Research Square

Preprints are preliminary reports that have not undergone peer review.
They should not be considered conclusive, used to inform clinical practice,
or referenced by the media as validated information.

Smartphone-Based Gender Identification from Palatal Rugae Images: A Comparative Transfer Learning Study of Pretrained CNNs

Dr. Deepa Hugar
Al Badar Dental College and Hospital
Dr. Rajmohan Pardeshi
Apex University
Dr. Rukhsar HUSSAIN
rukhsarhussain334@gmail.com
Pandit Deendayal Upadhyay Dental College and Hospital
Dr. Heena Zainab
Al Badar Dental College and Hospital
Dr. Ameena Sultana
Al Badar Dental College and Hospital
Dr. Khaja Moinuddin
Al Badar Dental College and Hospital

Research Article

Keywords: Convolutional Neural Networks (CNNs), Deep Learning, Forensic Odontology, Gender Identification, Palatal Rugae, Smartphone Imaging, Transfer Learning

Posted Date: May 13th, 2026

DOI: https://doi.org/10.21203/rs.3.rs-9230845/v1

License: This work is licensed under a Creative Commons Attribution 4.0 International License.
Read Full License

Additional Declarations: No competing interests reported.

Version of Record: A version of this preprint was published at Egyptian Journal of Forensic Sciences on October 16th, 2026. See the published version at https://doi.org/10.1186/s41935-026-00592-z.

Abstract

Background:

Palatal rugae are distinct anatomical ridges on the anterior part of the palate that exhibit individual-specific morphological patterns, making them valuable markers for personal identification and forensic analysis. With advancements in artificial intelligence, deep learning methods have emerged as effective tools for extracting discriminative features from medical and biometric images. This study investigates the potential of transfer learning-based convolutional neural networks (CNNs) for gender classification using palatal rugae images captured through a smartphone camera.

Results:

All pretrained models successfully learned discriminative gender-related features from palatal rugae images. Among them, Residual network 50 (ResNet50) and Visual Geometry Group 16 (VGG16) achieved the highest classification accuracy with optimal precision and recall, while EfficientNet-B0 and DenseNet121 demonstrated comparable but slightly lower performance. The Receiver Operating Curve (ROC curve) exhibited high Area under the Curve (AUC) values, confirming the strong separability between male and female classes.

Conclusion:

The findings confirm that smartphone-based imaging combined with transfer learning offers a promising, low-cost, and non-invasive approach for gender identification using palatal rugae patterns, as an adjunct tool for forensic odontology. Among the evaluated models, ResNet50 showed the most robust performance. Future work will focus on expanding the dataset and incorporating explainable Artificial Intelligence methods to support clinical and forensic applicability.

1. Introduction

The accurate identification of human remains is a primary concern in forensic science, particularly in mass-disaster, fire, or decomposition scenarios where standard approaches (fingerprints, dental records, DNA) may be unavailable or compromised (Sheoran et. al.2021). In such contexts, anatomical structures that are stable, unique to individuals, and resistant to post-mortem alteration become highly valuable. One such structure is the palatal rugae transverse ridges on the anterior portion of the hard palate which form early in utero and remain relatively unchanged throughout life (F.Pakshiret. al. 2019), (Caldas et. al. 2007). Because of their unique patterns, protected anatomical location, and resistance to trauma and decomposition, palatal rugae have been proposed as adjunctive identifiers in forensic odontology (Indira et. al. 2012).

Research has shown that the palatal rugae patterns may differ between sexes, and hence can serve as a tool for gender discrimination in forensics. For instance, studies in Indian (Gadicherlaet. al. 2017) and Iranian populations (M.Pakshiret. al. 2019) found statistically significant differences in certain rugae features between males and females. At the same time, the last decade has witnessed rapid progress in biometric identification and deep learning, especially using convolutional neural networks (CNNs) and transfer-learning approaches. These methods have been applied for gender classification from facial images, iris images and intra-oral photographs (Islam et. al. 2020), (Khalifa et. al. 2019), with pretrained architectures such as ResNet50, VGG16, EfficientNet-B0 and DenseNet121 being adapted to new tasks via fine-tuning (Smith et. al. 2018).

Despite these advances, the use of palatal rugae in automated gender classification remains under-explored. Traditional rugoscopy methods are manual, labour-intensive, and rely on cast models and human feature delineation (Caldas et al. 2007). Meanwhile, smartphone-based imaging and transfer learning open the possibility of portable, low-cost biometric workflows, which are highly desirable in field or resource-constrained forensic settings. The motivation for this work is thus two-fold: (i) to leverage modern deep-learning methods for a novel biometric modality (palatal rugae) previously analysed largely by manual or morphometric methods; and (ii) to demonstrate the viability of smartphone-acquired images (rather than specialised laboratory casts) for gender classification, thereby increasing accessibility and potential deployment in practical forensic or clinical workflows.

While multiple forensic odontology studies have reported sex-dimorphism in rugae (e.g., (Gadicherlaet. al. 2017), (M.Pakshiret. al. 2018), Malekzadeh etc al. 2018), there are limitations: many studies use small or homogeneous populations, manual rugae classification, or static cast models. Few studies have applied deep learning to rugae patterns; most biometric-gender classification work has focused on face, iris, fingerprints or periocular regions (see (Smith et. al. 2018)). To our knowledge, no study has yet combined smartphone-based rugae image acquisition with transfer-learning CNN architectures for gender classification. Additionally, comparative evaluations of multiple pretrained architectures on this modality are lacking, as are systematic reports of model performance using precision, recall, ROC and confusion matrices in the rugae context.

In this study, we propose a novel approach that bridges forensic odontology and artificial intelligence through the application of transfer learning to palatal rugae image analysis. First, we introduce a smartphone-based image acquisition protocol that enables portable and non-specialized capture of the palatal rugae region, thereby facilitating low-cost and accessible data collection for gender classification. Leveraging this dataset, we apply transfer-learning fine-tuning on four state-of-the-art pretrained convolutional neural network architectures. Furthermore, we perform a comprehensive comparative evaluation of these models using key performance indicators such as precision, recall, confusion matrix, and the area under the (ROC) curve, allowing identification of the most effective architecture for rugae-based gender classification. Finally, we discuss the forensic and clinical implications of our findings, emphasizing the potential of this AI-driven

framework to enable real-world, mobile, and explainable workflows for gender identification using palatal rugae imaging.A schematic overview of the proposed workflow is presented in Fig. 1, outlining the sequential stages of this study from data acquisition to model interpretation.

The rest of this paper is organised as follows. Section II describes the proposed methodology including image acquisition, preprocessing, data augmentation, model selection and training protocol. Section III presents the experimental results, including performance metrics for all models and comparative analysis. Section IV discusses the implications of the findings for forensic dentistry and biometric workflows, and outlines limitations and directions for future work. Finally, Section V concludes the study, summarising the contributions and potential practice impact.

2. Materials and Methods

2.1 Dataset Development: The dataset comprises 240 palatal rugae images collected at our College using a variety of commercially available smartphones with differing technical configurations (different manufacturers, sensor sizes and focal lengths) to reflect realistic field conditions. Participants were healthy volunteers aged 18–40 years, recruited from the outpatient department. The cohort consisted of 120 males and 120 females. Ethical approval for the study was obtained from the Institutional Ethics Committee which follows the standards of declaration of Helsinki, and written informed consent was obtained from all participants prior to image acquisition.

Images were captured by trained personnel using handheld smartphones under controlled indoor lighting to minimise shadows and glare. For each subject a single frontal intra-oral photograph of the anterior palate was taken following a standard protocol: participant seated upright, mouth opened to expose the hard palate, cheek retraction as needed, camera held approximately 15–25 cm from the oral cavity and aligned roughly perpendicular to the palatal plane. No specialized intra-oral cameras or laboratory casts were used; only standard smartphone cameras were used to ensure portability and real-world applicability. Each smartphone's make/model and nominal camera resolution were recorded in a metadata log to characterise device variability.

Inclusion criteria: age 18–40 years, presence of intact anterior palatal rugae, willingness to participate and provide consent. Exclusion criteria: recent palatal surgery, extensive palatal pathology, severe crowding or prosthetic appliances obscuring the rugae, and poor image quality despite re-capture attempts.

Original captures were saved in JPEG format with device-native resolution. All images were anonymized and assigned randomized IDs. Preprocessing included (i) visual quality check and dismissal of blurred images; (ii) manual cropping of the ROI to isolate the palatal rugae; (iii) resizing to a model-appropriate square resolution (224×224 pixels) to match the input requirements of the pretrained CNN backbones; and (iv) pixel-value scaling to the (0,1) range. No automated segmentation was used; ROI cropping was performed by a trained operator and verified by a senior clinician to ensure consistent framing across samples.

Each image was labelled with the subject's self-reported gender (male/female) recorded at recruitment. Labels and metadata (age group, device model, capture date) were stored in a secured spreadsheet. To ensure label accuracy and ROI quality, a second reviewer (oral pathology / forensic dentistry clinician) randomly inspected 20% of images; no systematic discrepancies were found.

2.2 Transfer Learning with Pre-trained CNN Architectures

CNNs are a class of artificial intelligence models inspired by how the human brain processes visual information. They are designed to automatically learn important features from images such as edges, shapes, textures, and patterns without the need for manual measurement or human-defined rules. In medical and dental imaging, CNNs have shown remarkable success in tasks like identifying lesions, detecting dental caries, classifying radiographs, and analysing microscopic structures (Litjenset. al. 2017), (Esteva et. al. 2017). By processing many examples, CNNs gradually learn to recognize the subtle visual cues that distinguish one class (e.g., male vs. female) from another.

Transfer learning is a technique that allows researchers to use knowledge already learned by a CNN from a very large dataset (such as ImageNet, which contains millions of natural images) and apply it to a new but related task, like analysing palatal rugae images. Instead of training a deep model from scratch, which would require thousands of medical images transfer learning fine-tunes an existing pre-trained model on a smaller, domain-specific dataset. This approach not only saves time and computing resources but also improves accuracy, especially when medical image data are limited. In essence, transfer learning helps the model "transfer" its general understanding of visual patterns (edges, textures, gradients) to specialized tasks such as forensic or clinical gender classification.

In our study, we leveraged four state-of-the-art CNN architectures pre-trained on the ImageNet dataset, and fine-tuned them for binary gender-classification from palatal rugae images. The chosen models were ResNet50, DenseNet121, EfficientNet-B0 and VGG16.

Residual Network (ResNet50) introduces skip connections to mitigate the vanishing gradient problem in deep architectures, and has become a widely adopted backbone in many image-classification tasks (Howard et. al. 2016). DenseNet121 uses dense connectivity between layers so that each layer receives feature-maps from all preceding layers; this architecture improves feature reuse and reduces parameter count (Huang et. al. 2017). EfficientNet-B0 applies compound model scaling (depth, width and input resolution) to balance model size and accuracy, thereby achieving efficient yet high-performing representations (M. Tan and Q. Le2019). VGG16, though older, remains a canonical benchmark featuring 16 convolutional and fully-connected layers and delivering strong baseline performance for transfer learning tasks (K. Simonyan and A. Zisserman 2014, Simon et al. 2016).

For each of these architectures we replaced the original classification head with a new fully connected layer (or layers) appropriate for binary classification (male vs. female). We froze the convolutional base for an initial warm-up phase and then unfroze select higher layers for fine-tuning. Input images were resized to 224 × 224 pixels to match the native input dimensions of the networks. All models used

weights pre-trained on ImageNet, and were further trained using our augmented palatal rugae dataset. This approach enabled effective feature extraction from complex anatomical patterns without manual feature-engineering, leveraging the representational power of deep CNNs in a domain new to biometric gender classification.

2.3 Evaluation Protocol

To assess the performance of the proposed deep learning models, several standard evaluation metrics were employed, including accuracy, precision, recall, and F1-score. Accuracy reflects the overall proportion of correctly classified samples, whereas precision and recall provide a more detailed understanding of model behavior in imbalanced clinical datasets—precision indicates how many predicted positive cases are truly positive, and recall measures how many actual positives are correctly identified by the model (D. M. W. Powers 2011). The F1-score, representing the harmonic mean of precision and recall, offers a balanced measure of performance particularly relevant in biomedical studies where false negatives and false positives have differing implications (T. Saito and M. Rehmsmeier 2015). To further analyze the discriminative capability of each model, ROC curves were plotted, and AUC was computed to quantify classification performance across varying thresholds (T. Fawcett 2005). Additionally, Gradient-weighted Class Activation Mapping (Grad-CAM) was used to generate visual explanations of the CNN predictions by highlighting the most informative regions in the palatal rugae images that contributed to gender classification (Selvaraju et. al. 2017). Such visual interpretability is critical in clinical AI applications, promoting transparency and enhancing trust among practitioners.

3. Experimental Results

3.1 Results

The performance of four pretrained CNN models—ResNet50, DenseNet121, EfficientNet-B0, and VGG16—was evaluated for gender classification based on palatal rugae images and exhaustive result are shown in Table 1. All implementations were carried out using PyTorch on a system configured with an Intel Core i7 processor, 16 GB RAM, and an NVIDIA GeForce RTX GPU (4 GB VRAM). The dataset contained 240 smartphone-acquired palatal rugae images (120 males and 120 females), divided into 80% for training and 20% for testing. Data augmentation (rotation, flipping, and contrast and brightness adjustments) was applied during training to improve generalisation and reduce overfitting.

Table 1
Comparative performance of transfer learning models for gender classification using palatal rugae images

Model	Gender	Precision	Recall	F1-Score	Overall Accuracy
ResNet50	Female	0.72	0.88	0.79	**0.77**
	Male	0.84	0.67	0.74	
DenseNet121	Female	0.59	0.79	0.68	**0.62**
	Male	0.69	0.46	0.55	
EfficientNet-B0	Female	0.65	0.83	0.73	**0.69**
	Male	0.76	0.54	0.63	
VGG16	Female	0.70	0.79	0.75	**0.73**
	Male	0.76	0.67	0.71	

Among the models, ResNet50 achieved the highest performance with an overall accuracy of 77%, followed by VGG16 (73%), EfficientNet-B0 (69%), and DenseNet121 (62%).

ResNet50 displayed superior sensitivity for female samples (recall = 0.88; F1-score = 0.79) and balanced male classification (recall = 0.67; F1-score = 0.74), yielding a per-class accuracy of 87.5% for females and 66.7% for males. VGG16 produced comparatively stable and balanced results (female = 0.75 F1; male = 0.71 F1), while EfficientNet-B0 performed better on female images (recall = 0.83) but struggled with males (recall = 0.54), possibly due to limited extraction of fine-scale rugae geometry. DenseNet121, though deeper and densely connected, underperformed (accuracy = 62%) and showed a marked reduction in male recall (0.46), likely caused by feature redundancy and overfitting on texture patterns in a small dataset. For deeper understanding we have given confusion matrices in Fig. 2.

These findings suggest that moderately deep residual architectures, such as ResNet50, offer the best balance between model depth, gradient stability, and generalization when analyzing subtle biological variations in limited datasets—a trend consistent with prior biomedical imaging research (Gadicherlaet. al. 2017).

The discriminative capacity of each model was assessed using ROC curves and AUC metrics as shown in Fig. 3. The ResNet50 model achieved the highest AUC, confirming its superior class separability between male and female samples. VGG16 and EfficientNet-B0 showed moderate but reliable AUC values, indicating effective yet less robust classification boundaries. DenseNet121 exhibited the lowest AUC, corresponding to its weaker performance metrics.

The ROC–AUC outcomes demonstrate that residual learning facilitates superior feature abstraction, particularly when class boundaries are subtle—as in palatal rugae dimorphism. In clinical AI studies,

higher AUC values imply a more reliable classifier across varying sensitivity-specificity trade-offs (A. Jain and R. Chowdhary 2014).

To provide interpretability and transparency, Grad-CAM (Selvaraju et. al. 2017) was used to visualize the discriminative regions that guided model decisions. For correctly classified cases, Grad-CAM heatmaps highlighted activations concentrated over the central and posterior rugae regions, which are anatomically recognized as exhibiting greater inter-individual variation and sexual dimorphism (F.Pakshiret. al. 2019), (Gadicherlaet. al. 2017). In Fig. 4. representative examples of palatal rugae images for male (top row) and female (bottom row) subjects are shown alongside their corresponding Grad-CAM heatmaps. The activation regions (highlighted in red/yellow) indicate the discriminative zones most influential in the model's decision-making process. In both cases, ResNet50 predominantly focused on the central and posterior rugae regions, which exhibit distinctive textural and curvature patterns relevant to sexual dimorphism. The Grad-CAM outputs confirm that the model's predictions were based on clinically meaningful anatomical areas, supporting interpretability and forensic reliability of the proposed AI-assisted approach.

These visual explanations confirm that the CNNs learned clinically relevant morphological cues rather than relying on incidental artifacts. The integration of Grad-CAM thus reinforces clinical confidence by enabling qualitative verification of model focus areas, an important step toward explainable and trustworthy AI applications in forensic odontology (Dwivedi et. al. 2016), (Gupta et. al. 2022).

From a forensic perspective, the study validates the potential of AI-assisted palatal rugae analysis for gender identification. The higher female classification accuracy observed may correspond to more consistent curvature and spacing of rugae in female palates, a trend previously documented in morphological studies (F.Pakshiret. al. 2019), (Gadicherlaet. al. 2017). From a computational viewpoint, ResNet50's residual connections enabled effective gradient propagation across layers, improving feature extraction despite dataset limitations. Although DenseNet121 was theoretically deeper, its dense feature reuse likely led to overfitting. EfficientNet-B0 and VGG16 provided a favourable trade-off between computational cost and diagnostic accuracy, suitable for deployment on resource-limited clinical hardware.

Overall, the results demonstrate that transfer learning combined with explainable AI visualization offers a robust and interpretable framework for gender identification from palatal rugae images captured via smartphones. This approach can extend to field-based or tele-forensic workflows where affordability, portability, and transparency are essential.

3.2 Discussion:

The results of this study demonstrate that transfer learning-based CNNs can effectively classify gender from palatal rugae images captured using standard smartphone cameras. This finding reinforces the long-established notion in forensic odontology that palatal rugae patterns exhibit individuality and sexual dimorphism, thereby serving as a potential tool for personal identification (Gadicherlaet. al.2017)

(Dwivedi et. al. 2016). While conventional rugae analysis typically relies on dental casts or intraoral scanners, our results suggest that digitally captured rugae images, when processed through pretrained CNNs, can yield comparable discriminative accuracy. This marks a step toward non-invasive, portable, and cost-effective forensic imaging using readily available smartphone technology.

In forensic contexts where fingerprints or DNA may be unavailablesuch as in burn victims, mass disasters, or decomposed bodies—the oral cavity remains well protected, often preserving the palatal rugae structure (A. Jain and R. Chowdhary 2014), (Gupta et. al.2022). These resilient mucosal folds resist postmortem changes, making them reliable for identification even under adverse conditions (Muthusubramanianet. al. 2015). The higher classification accuracy for female images observed across all CNN architectures in our study aligns with prior morphological findings that female rugae tend to exhibit more uniform and curved patterns, whereas male rugae often show greater irregularity and branching, increasing intra-class variability (Gadicherlaet. al. 2017), (Nayak et. al. 2011), (Trizzino et. al. 2023). Such inherent anatomical differences appear to facilitate CNN learning, as the model can detect recurrent curvatures and ridge patterns characteristic of female samples. The results thus reaffirm the potential of rugae-based features as auxiliary biometric identifiers in forensic gender estimation, complementing traditional parameters such as dental arch width or mandibular dimensions (Baban and Mohammad et. al. 2024).

From an artificial intelligence perspective, the superior performance of ResNet50 (accuracy = 77%) can be attributed to its residual learning architecture, which effectively mitigates vanishing gradient issues and enables deep feature extraction from subtle morphological cues. In contrast, DenseNet121 demonstrated reduced accuracy due to feature redundancy, a known issue when data size is limited—a challenge often encountered in medical and forensic imaging datasets (Litjens et al. 2017) The relatively strong performance of VGG16 and EfficientNet-B0 demonstrates that even lightweight models can generalize well in constrained environments, supporting their suitability for edge or mobile deployment in clinical and forensic settings (Rasheed S 2026).

To address the “black-box” limitation of deep models, Grad-CAM was employed for visual interpretability (Selvarajuet. al. 2017). The resulting heatmaps consistently showed activation focused on the central and posterior rugae zones, which correspond to anatomically relevant sites of sexual dimorphism (A. Jain and R. Chowdhary), (Nayak et. al. 2011). Misclassified cases, however, displayed dispersed attention toward non-rugae areas, indicating potential interference from lighting or mucosal reflection during smartphone imaging. Such findings confirm that the CNNs primarily learned biologically meaningful discriminative cues, enhancing both interpretive transparency and forensic reliability. This approach aligns with recent trends emphasizing explainable AI (XAI) in medical and forensic domains to increase user trust and traceability of automated decisions (Dwivedi et. al. 2016), (Gupta et. al. 2022).

Previous forensic studies have primarily utilized morphometric or visual pattern-based techniques for rugae analysis (Gadicherlaet. al. 2017)–(Muthusubramanianet. al. 2015). However, integrating transfer learning with smartphone-acquired images, as demonstrated here, expands applicability to field-based

identification scenarios. The performance metrics achieved are comparable to other emerging biometric modalities such as cheiloscopy (lip prints) and dental radiograph analysis, which have also employed CNN-based classification with accuracy in the 70–80% range (Nayak et. al. 2011), (Trizzino et. al. 2023). Recent systematic reviews affirm that palatal rugae remain one of the most stable intraoral identifiers and can serve as a reliable digital biometric marker in combination with AI (Gupta et. al. 2022), (Trizzino et. al. 2023). Our findings further support this, showing that portable, non-specialized imaging—combined with robust neural architectures—can yield scientifically valid and operationally feasible outcomes.

The results of this work have significant implications for forensic identification, gender estimation, and digital dental records. The methodology proposed could be integrated into mobile forensic kits or clinical software for rapid field-level screening, especially in low-resource or rural settings (Rasheed S 2026). The demonstrated interpretability through Grad-CAM provides an added layer of forensic admissibility, as investigators and odontologists can visually verify the AI's decision focus before reporting. Future research should aim to expand the dataset across broader demographic groups, incorporate multimodal dental data, and explore federated or edge-AI frameworks for privacy-preserving forensic analysis.

While the present study demonstrates the feasibility of using smartphone-acquired palatal rugae images for gender classification, certain limitations should be acknowledged. The dataset, although carefully curated and balanced, is moderate in size and sourced from a specific population, which may influence the broader generalizability of the findings. Image acquisition using different smartphone devices introduces natural variability in resolution and illumination; however, this also reflects realistic field conditions. The region of interest was delineated through manual cropping to ensure anatomical accuracy, though future work may benefit from automated standardization. The current framework focuses on binary gender classification and a limited set of pretrained architectures, providing a foundational comparison rather than an exhaustive exploration. Additionally, the observed performance levels indicate that the approach is best suited as an adjunct to existing forensic methods. Further validation on larger, multi-institutional datasets and diverse demographic groups would strengthen the robustness and applicability of the proposed methodology.

In summary, this study establishes that transfer learning combined with explainable AI visualization offers a possibly viable pathway for objective, reproducible, and field-deployable gender classification from palatal rugae images, bridging the gap between clinical forensics and computational intelligence.

4. Conclusion

The present study proposes a structured approach for gender classification using palatal rugae images through transfer learning and convolutional neural networks. By utilizing pretrained models on smartphone-acquired intraoral images, the findings indicate that such methods can capture discriminative patterns from subtle mucosal structures with moderate classification performance.

Among the evaluated architectures, ResNet50 demonstrated comparatively balanced results, suggesting its suitability for this type of image-based analysis.

The incorporation of Grad-CAM visualization provided useful interpretability by highlighting anatomically relevant regions that contributed to model predictions. Such visualization supports a better understanding of model behavior and may enhance transparency in analytical workflows.

From a forensic perspective, the study explores a non-invasive, low-cost, and portable approach that may complement conventional palatal rugae analysis methods, particularly in resource-constrained or preliminary screening scenarios. It also represents a step toward the broader exploration of explainable artificial intelligence techniques in dental biometrics, where reproducibility and interpretability are important considerations.

Future work should focus on validating the approach using larger and more diverse datasets, incorporating additional dental or biometric modalities, and evaluating performance under varied real-world conditions. Overall, this study provides a preliminary foundation for further investigation into the use of computational methods in forensic odontology.

Abbreviations

AI: Artificial Intelligence

Residual network 50- ResNet50

Visual Geometry Group 16-VGG16

Convolutional neural networks- CNNs

Region of interest- ROI

Receiver operating characteristic curve-ROC

Area under the curve-AUC

Gradient-weighted Class Activation Mapping- Grad-CAM

Declarations

- **Ethics Approval-** Ethical approval was taken by our college Ethical Board Committee- Institutional Ethics Committee Al Badar rural Dental College & Hospital with reference no- ARDCH/2023-2024/IEC/D-19.
- **Human ethics & Consent for participation-** Written informed consent was taken from all the participants

- **Consent for publication-** No one's data is taken for publication.
- **Funding-** Not applicable.

Author Contribution

1st & 2nd authors are equally contributed authors,3rd author edited manuscriptAll others reviewed manuscript

References

1. Sheoran, V., Joshi, S., & Bhayani, T. R. (2021). Age and Gender Prediction Using Deep CNNs and Transfer Learning. In *Communications in computer and information science* (pp. 293–304). https://doi.org/10.1007/978-981-16-1092-9_25
2. Pakshir, F. , Ajami, S. ,Pakshir, H. and Malekzadeh, A. (2019). Characteristics of Palatal Rugae Patterns as a Potential Tool for Sex Discrimination in a Sample of Iranian Children. *Journal of Dentistry*, *20*(1), 1-9. doi: 10.30476/dentjods.2019.44556
3. Caldas, I. M., Magalhães, T., & Afonso, A. (2007). Establishing identity using cheiloscopy and palatoscopy. *Forensic Science International, 165*(1), 1–9. https://doi.org/10.1016/j.forsciint.2006.04.010
4. Indira, A., Gupta, M., & David, M. P. (2012). Usefulness of palatal rugae patterns in establishing identity: Preliminary results from Bengaluru city, India. *Journal of Forensic Dental Sciences, 4*(1), 2–5. https://doi.org/10.4103/0975-1475.99149
5. Gadicherla, P., Saini, D., & Bhaskar, M. (2017). Palatal rugae pattern: An aid for sex identification. *Journal of Forensic Dental Sciences, 9*(1), 48. https://doi.org/10.4103/jfo.jfds_108_15
6. Malekzadeh, A. R., Pakshir, H. R., Ajami, S., &Pakshir, F. (2018). The application of palatal rugae for sex discrimination in forensic medicine in a selected Iranian population. *Iranian Journal of Medical Sciences, 43*(6), 612–622. https://doi.org/10.30476/ijms.2018.40585
7. Islam, M. M., Tasnim, N., & Baek, J.-H. (2020). Human Gender Classification Using Transfer Learning via Pareto Frontier CNN Networks. *Inventions*, *5*(2), 16. https://doi.org/10.3390/inventions5020016
8. Khalifa, N. E. M., Taha, M. H. N., Hassanien, A. E., & Selim, I. (2019). Deep learning for gender classification through iris images. *BMC Medical Imaging, 19*(1), Article 42. https://doi.org/10.1186/s12880-019-0331-x
9. Smith, P., & Chen, C. (2018). Transfer learning with deep CNNs for gender recognition and age estimation. In *Proceedings of the 2018 IEEE International Conference on Big Data (Big Data)* (pp. 2564–2571). https://doi.org/10.1109/BigData.2018.8621891
10. Litjens, G., Kooi, T., Ehteshami Bejnordi, B., Setio, A. A. A., Ciompi, F., Ghafoorian, M., van der Laak, J. A. W. M., van Ginneken, B., & Sánchez, C. I. (2017). A survey on deep learning in medical image analysis. *Medical Image Analysis, 42*, 60–88. https://doi.org/10.1016/j.media.2017.07.005

11. Esteva, A., Kuprel, B., Novoa, R. A., Ko, J., Swetter, S. M., Blau, H. M., & Thrun, S. (2017). Dermatologist-level classification of skin cancer with deep neural networks. *Nature, 542*(7639), 115–118. https://doi.org/10.1038/nature21056
12. Simon, M., Rodner, E., & Denzler, J. (2016). Imagenet pre-trained models with batch normalization. *arXiv preprint arXiv:1612.01452*.
13. Huang, G., Liu, Z., Van Der Maaten, L. and Weinberger, K.Q. (2017) Densely Connected Convolutional Networks. Proceedings of the IEEE Conference on Computer Vision and Pattern Recognition, Honolulu, 21-26 July 2017, 4700-4708. https://doi.org/10.1109/CVPR.2017.243
14. Tan, M. and Le, Q.V. (2019) EfficientNet: Rethinking Model Scaling for Convolutional Neural Networks. Proceedings of the 36th International Conference on Machine Learning, ICML 2019, Long Beach, 9-15 June 2019, 6105-6114. http://proceedings.mlr.press/v97/tan19a.html
15. Simonyan, K. and Zisserman, A. (2014) Very Deep Convolutional Networks for Large-scale Image Recognition. arXiv: 1409.1556.https://doi.org/10.48550/arXiv.1409.1556
16. Powers, D.M.W. (2011) Evaluation: From Precision, Recall and F-Measure to Roc, Informedness, Markedness & Correlation. Journal of Machine Learning Technologies, 2, 37-63.
17. Saito, T., &Rehmsmeier, M. (2015). The precision-recall plot is more informative than the ROC plot when evaluating binary classifiers on imbalanced datasets. *PLoS ONE, 10*(3), e0118432. https://doi.org/10.1371/journal.pone.0118432
18. Fawcett, T. (2006). An introduction to ROC analysis. *Pattern Recognition Letters, 27*(8), 861–874. https://doi.org/10.1016/j.patrec.2005.10.010
19. Selvaraju, R. R., Cogswell, M., Das, A., Vedantam, R., Parikh, D., & Batra, D. (2017). Grad-CAM: Visual explanations from deep networks via gradient-based localization. In *Proceedings of the IEEE International Conference on Computer Vision (ICCV)* (pp. 618–626). https://doi.org/10.1109/ICCV.2017.74
20. Jain, A., & Chowdhary, R. (2014). Palatal rugae and their role in forensic odontology. *Journal of Investigative and Clinical Dentistry, 5*(3), 171–178. https://doi.org/10.1111/j.2041-1626.2013.00150.x
21. Dwivedi, N., &Nagarajappa, A. K. (2016). Morphological analysis of palatal rugae pattern in central Indian population. *Journal of International Society of Preventive & Community Dentistry, 6*(5), 417–422. https://doi.org/10.4103/2231-0762.192947
22. Gupta, A. A., Kheur, S., Alshehri, A., Awadh, W., Ahmed, Z. H., Feroz, S. M. A., Khan, S. S., Mushtaq, S., Dewan, H., Khurshid, Z., Varadarajan, S., Sujatha, G., Veeraraghavan, V. P., & Patil, S. (2022). Is palatal rugae pattern a reliable tool for personal identification following orthodontic treatment? A systematic review and meta-analysis. *Diagnostics, 12*(2), 418. https://doi.org/10.3390/diagnostics12020418
23. Muthusubramanian, M., Limson, K. S., & Julian, R. (2005). Analysis of rugae in burn victims and cadavers to simulate rugae identification in cases of incineration and decomposition. *Journal of Forensic Odonto-Stomatology, 23*(1), 26–29.

24. Byatnal, A., Byatnal, A., Kiran, A. R., Samata, Y., Guruprasad, Y., &Telagi, N. (2014). Palatoscopy: An adjunct to forensic odontology: A comparative study among five different populations of India. *Journal of Natural Science, Biology and Medicine, 5*(1), 52–55. https://doi.org/10.4103/0976-9668.127287
25. Trizzino, A., Messina, P., Sciarra, F. M., Zerbo, S., Argo, A., & Scardina, G. A. (2023). Palatal rugae as a discriminating factor in determining sex: A new method applicable in forensic odontology? *Dentistry Journal, 11*(9), 204. https://doi.org/10.3390/dj11090204
26. Baban, M. T. A., & Mohammad, D. N. (2024). A new approach for sex prediction by evaluating mandibular arch and canine dimensions with machine-learning classifiers and intraoral scanners (a retrospective study). *Scientific Reports, 14*, Article 27974. https://doi.org/10.1038/s41598-024-79738-9
27. Rasheed, S. (2026). Lightweight Deep Learning Models for Face Mask Detection in Real-Time Edge Environments: A Review and Future Research Directions. *Machine Learning and Knowledge Extraction*, *8*(4), 102. https://doi.org/10.3390/make8040102

Figures

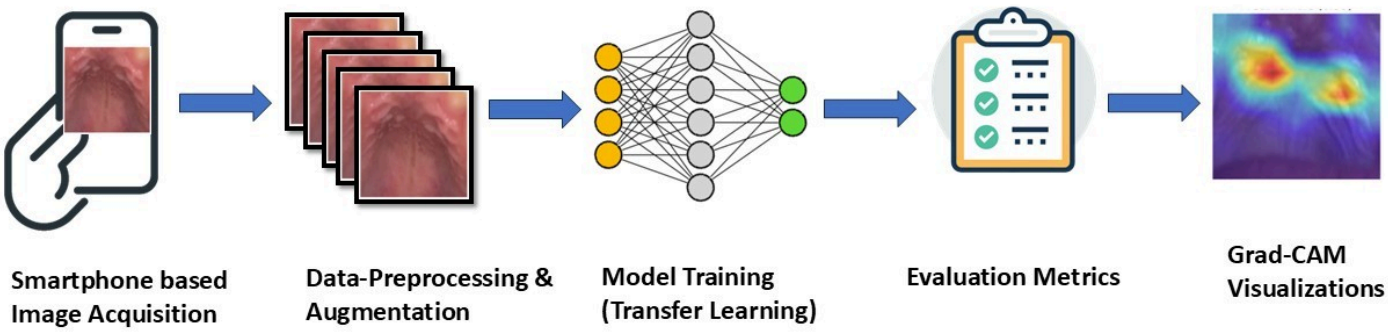

Figure 1

Schematic representation of the proposed workflow for gender classification using palatal rugae and transfer learning

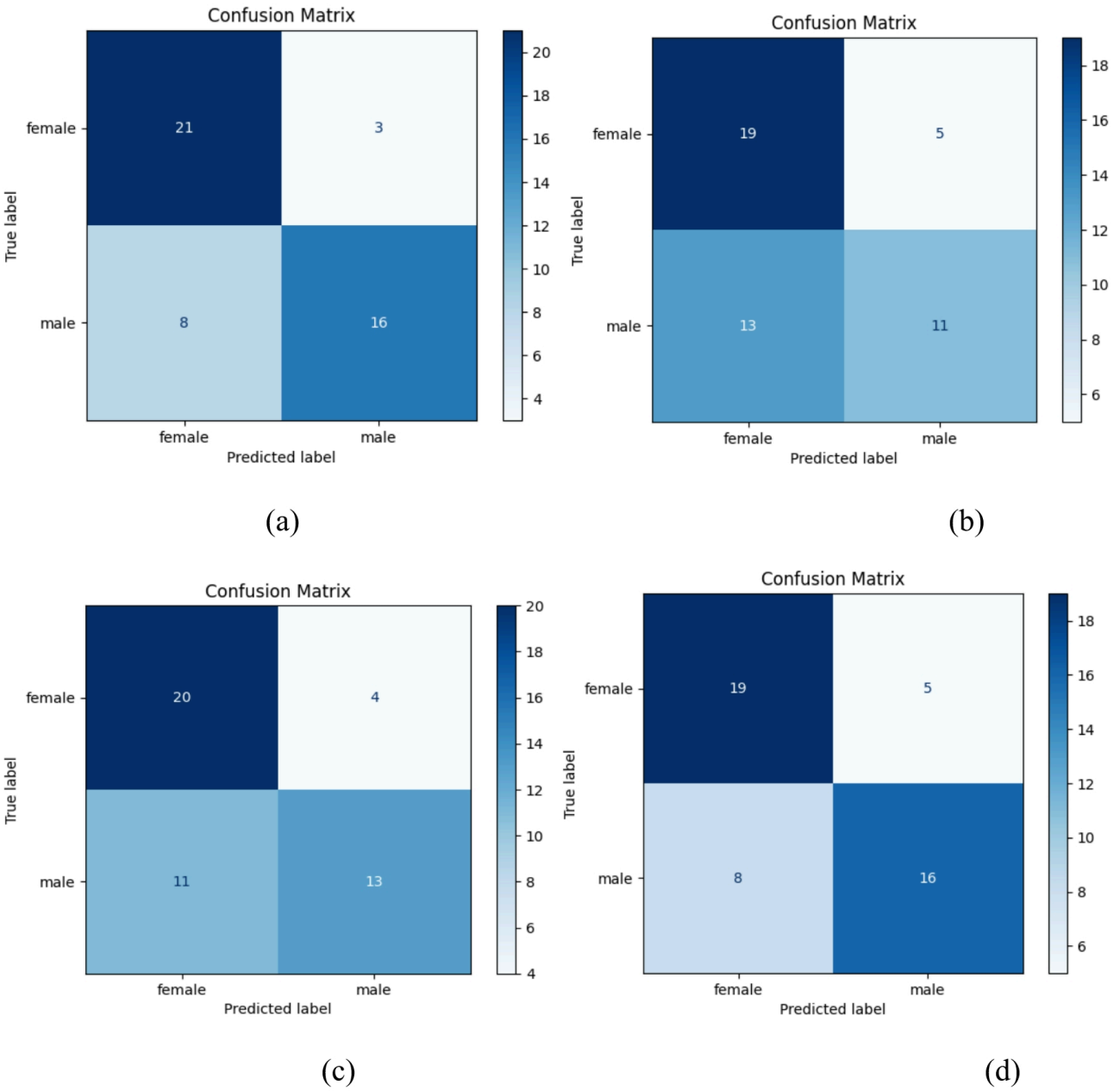

Figure 2

Confusion matrices for gender classification using palatal rugae images with four pretrained CNN models: (a) ResNet50, (b) DenseNet121, (c) EfficientNet-B0, and (d) VGG16. Diagonal values indicate correct predictions, with ResNet50 achieving the most balanced accuracy across both gender classes

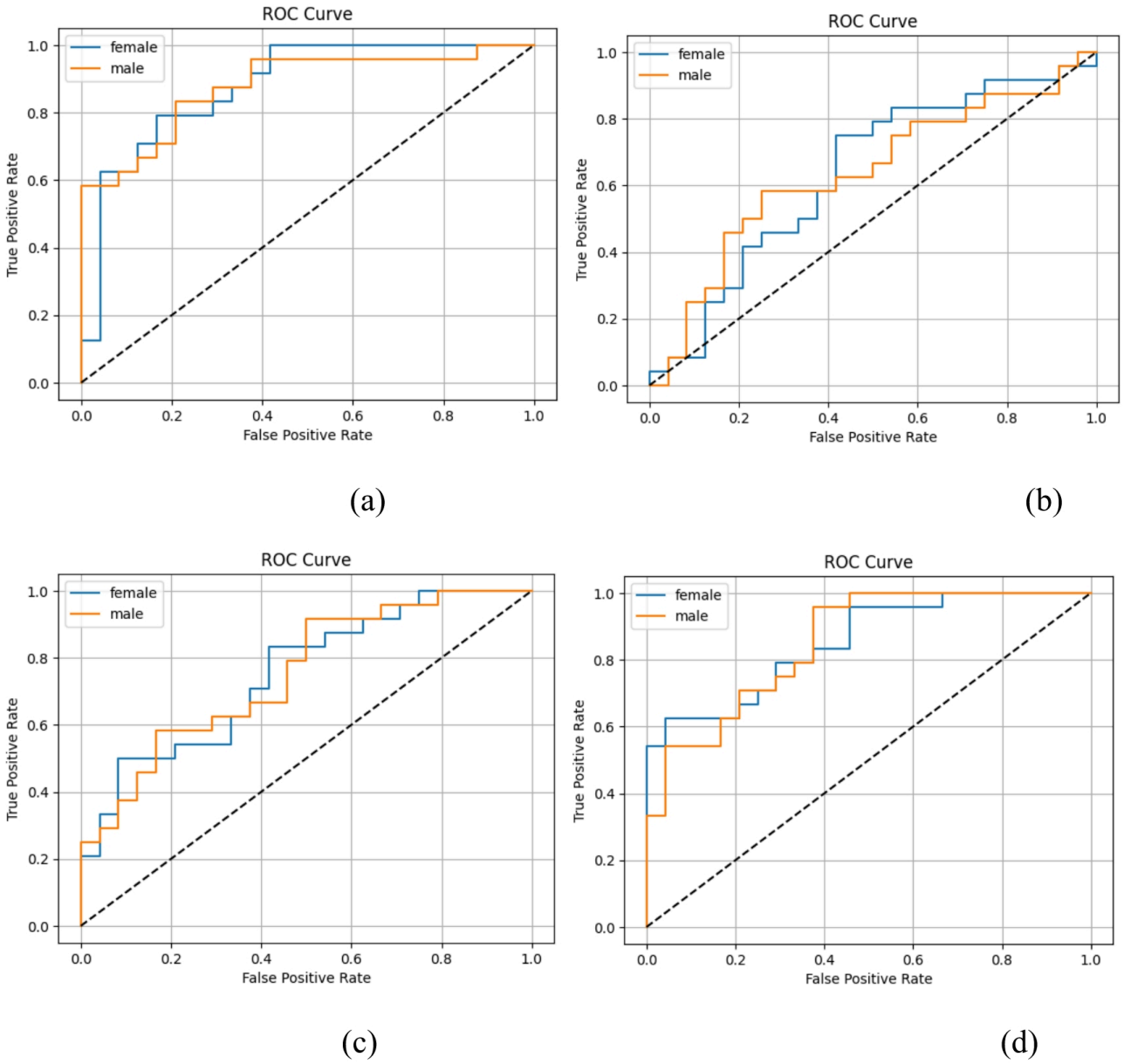

Figure 3

ROC curves for gender classification using palatal rugae images with four pretrained CNN models: (a) ResNet50, (b) DenseNet121, (c) EfficientNet-B0, and (d) VGG16. Each curve represents male and female class performance; higher AUC values indicate better discriminative ability, with ResNet50 showing the strongest separation between classes

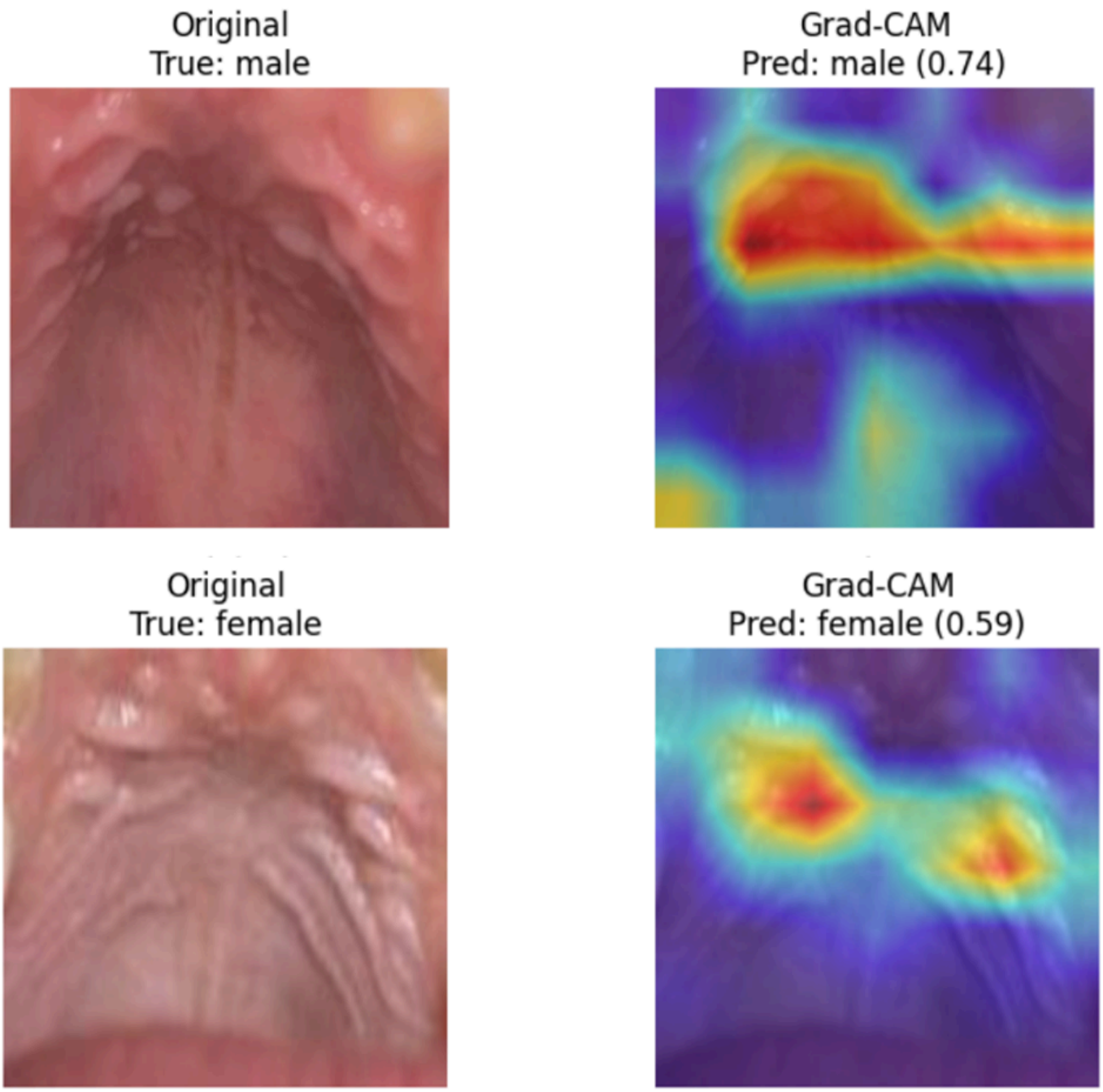

Figure 4

Grad-CAM heatmaps for the ResNet50 model showing discriminative attention over palatal rugae regions. Top: male image (true = male, predicted = male, confidence = 0.74). Bottom: female image (true = female, predicted = female, confidence = 0.59). Red and yellow areas highlight regions most influential in classification, corresponding primarily to central and posterior rugae zones