

DOI: 10.58240/1829006X-2025.21.5-257



## COMPARATIVE EVALUATION OF DIFFERENT PROCEDURES FOR ANALYZING RESIDUAL ALVEOLAR RIDGE WIDTH BEFORE DENTAL IMPLANT PLACEMENT: A CLINICAL STUDY

Abhishek Motimath<sup>1</sup>, Vivek Vijay Gupta<sup>2</sup>, Harshitha Alva<sup>3</sup>, Nirupama R<sup>4</sup>, Sheetal Acharya<sup>5</sup>, Samidha Vivek Jambhekar<sup>6</sup>, Miral Mehta<sup>7</sup>, Ramanpal Singh Makkad<sup>8</sup>

<sup>1</sup>Assistant Professor, Department of Oral and Maxillofacial Surgery, KLE V K Institute of Dental Sciences, Belgaum, Karnataka. Email: abhi\_motimath@yahoo.com

<sup>2</sup>Senior Lecturer, Faculty of Dentistry SEGi University, Malaysia. Email: vivekvijaygupta@segi.edu.my

<sup>3</sup>Reader, Department Of Prosthodontics Dayananda Sagar College Of Dental Sciences, Bangalore, Karnataka. Email: harshithaalva@dscds.edu.in

<sup>4</sup>Reader, Department of Prosthodontics, AB Shetty Memorial Institute of Dental Sciences, NITTE (Deemed to be University) Deralakatte, Mangalore. Email: drnirupamar@nitte.edu.in

<sup>5</sup>Associate Professor, Department of Periodontics and Implantology, Kalinga Institute of Dental Sciences KIIT (Deemed to be) University Bhubaneswar, Odisha. Email: so\_sheets@yahoo.com

<sup>6</sup>Assistant professor Department of Periodontics Dr D Y Patil Dental college and Hospital, Dr D Y Patil Vidyapeeth, (Deemed-to-be-University) Pune. Email: sam07.sj@gmail.com

<sup>7</sup>Assistant Professor, Department of Pediatric and Preventive Dentistry, Karnavati School of Dentistry Karnavati University, Gandhinagar Gujarat, India miral9829@gmail.com

<sup>8</sup>Professor, Department of Oral Medicine and Radiology, New Horizon Dental College and Research Institute, Bilaspur, Chhattisgarh. Email: drramanpal@gmail.com

\***Corresponding Author:** Samidha Vivek Jambhekar, Assistant professor Department of Periodontics Dr D Y Patil Dental college and Hospital, Dr D Y Patil Vidyapeeth, (Deemed-to-be-University) Pune. Email: sam07.sj@gmail.com

**Received:** May 15, 2025; **Accepted:** Jun 15, 2025; **Published:** Jun.30,2025

### ABSTRACT

**Background:** Accurate assessment of the residual alveolar ridge width is critical for successful dental implant placement. Multiple techniques exist to measure this parameter, ranging from radiographic to clinical and non-invasive imaging methods.

**Objectives:** To compare the reliability, accuracy, and clinical applicability of six different techniques—direct surgical measurement (gold standard), CBCT, ridge mapping, ultrasound, digital caliper, and occlusal radiography—for evaluating residual alveolar ridge width prior to dental implant placement.

**Materials and Methods:** Sixty patients (35 females, 25 males; mean age 52.7±11.3 years) with 85 implant sites were evaluated using all six techniques. Ridge width measurements were recorded at three levels (crestal, 3 mm, and 6 mm apical) using each method. Direct surgical measurement during implant placement served as the gold standard.

**Results:** Mean ridge width by direct surgical measurement was 4.20±1.58 mm. Ridge mapping (4.57±1.63 mm), CBCT (4.62±1.67 mm), and digital caliper (4.25±1.60 mm) showed no significant difference from the gold standard ( $p > 0.05$ ). Occlusal radiography significantly overestimated ridge width (5.10±1.80 mm,  $p < 0.001$ ). Ridge mapping showed highest accuracy (95%) and correlation ( $r=0.95$ ), followed by digital caliper (94%,  $r=0.94$ ) and CBCT (92%,  $r=0.92$ ). Ultrasound showed moderate accuracy (89%) and correlation ( $r=0.89$ ), while occlusal radiography was least accurate (85%,  $r=0.82$ ). Intra-examiner and inter-examiner reliability were excellent across all techniques (ICC range: 0.85–0.98).

**Conclusion:** Ridge mapping and CBCT are reliable, accurate, and clinically effective non-invasive alternatives for evaluating alveolar ridge width before implant placement. Ridge mapping offers a radiation-free, cost-effective chairside solution, while CBCT provides comprehensive anatomical details with higher cost and radiation exposure. Ultrasound is promising but requires further refinement to match the accuracy of established methods. Ridge mapping and CBCT are reliable, accurate, and clinically effective non-invasive alternatives for evaluating alveolar ridge width before implant placement. Ridge mapping offers a radiation-free, cost-effective chairside solution, while CBCT provides comprehensive anatomical details with higher cost and radiation exposure. Ultrasound is promising but requires further refinement to match the accuracy of established methods.

**Keywords:** Alveolar ridge width, dental implants, ridge mapping, CBCT.

## INTRODUCTION

Dental implants have transformed rehabilitation of edentulous patients giving them both aesthetic and functionality better than the conventional methods of replacing missing teeth 1,2. Successful long-term survival of a dental implant is greatly determined by its proper treatment planning where proper evaluation

of available bone dimensions is very imperative 3,4. Low bone volume specially ridge width is one of the usual difficulties in implant dentistry which can require bone grafting techniques or other treatment modalities 5,6.

A major resorption of alveolar ridge will take place after extraction of tooth such that the horizontal loss of bone is much faster as well as widespread compared with the vertical resorption 7,8. Research has proven that buccolingual dimension may drop up to 50 percent in a year after extraction process, two thirds of the degradation being in the first three months [9,10]. Such dimensional alteration underlines the relevance of an adequate ridge width estimation before inserting the implant 11,12.

Several methods have been adopted to measure the width of the alveolar ridge and they all bear their own merits and demerits 13. The standard two dimensional radiograph makes it difficult to capture the information about the buccolingual dimensions though they are useful in assessing the heights 14. Imaging technology including CBCT provides a complete three-dimensional image but is based on radiation and more expensive 15. The clinical tools such as ridge mapping, or direct caliper measure result in immediate results, but are invasive and dependent on an operator.

New technologies have brought new methods like ultrasound imaging as well as digital integration of workflow and may provide non-invasive solutions with lower intensities of radiation 1. Although various measurement methods are available, no sufficient agreements seem to exist on the relative accuracy, reliability, and clinical relevance of the methods 2.

This paper intends to critically discuss the six various methods of measuring residual alveolar ridge width prior to surgical placement of dental implants; CBCT, ridge mapping, direct surgical measurement, ultrasound, digital caliper, and occlusal radiography. By evaluating these techniques in a variety of parameters such as accuracy, radiation exposures, cost, and invasiveness, this study aims to present evidence-based implications to clinical practice.

Materials and Methods

### Patient selection and Study Design

Sixty patients (35 females and 25 males) undergoing treatment and having age range 28-74 years, in which dental implants have to be placed, were enrolled in the study. Inclusion criteria

included patients 18 years or above, at least one edentulous site, and there should be implant placement, the extraction site should be healed with a minimum of 4 months and patient should have good oral hygiene. Systemic conditions that made implant surgery unfeasible, radiotherapy to the head and neck, uncontrolled diabetes, women who were pregnant, and who were unable to adhere to the study protocol were the exclusion criteria.

### Measurement Techniques

Six different techniques were employed to measure the buccolingual width of the alveolar ridge at each implant site. Cone Beam Computed Tomography (CBCT) scans were obtained using a high-resolution scanner, and measurements were performed using dedicated software by an experienced radiologist blinded to the clinical data. Ridge mapping involved the fabrication of a vacuum-formed stent with reference holes, through which a bone caliper was used under local anesthesia to record measurements at three levels: crestal, 3 mm apical, and 6 mm apical to the crest. Direct surgical measurements were taken during implant surgery following flap elevation using a digital caliper at the same three levels, serving as the gold standard for comparison. A high-frequency ultrasound device with a 15 MHz linear transducer was employed to obtain cross-sectional images of the alveolar ridge, with measurements recorded using integrated software. A modified digital caliper with pointed tips was used under local anesthesia to measure the ridge width trans-mucosally at the specified levels. Occlusal radiographs were obtained using a standardized paralleling technique with a film holder and grid, and measurements were performed using calibrated digital software. All measurements were carried out independently by two calibrated examiners, and the mean values were used for analysis. To assess intra-examiner reliability, 20% of the measurements were repeated after a two-week interval.

### Statistical Analysis

Sample size calculation was performed using appropriate statistical software, determining that a minimum of 54 implant sites was needed to detect a mean difference of 0.5 mm between techniques with 80% power at a 5% significance level. Statistical analysis was conducted using SPSS software. Descriptive statistics including mean, standard deviation, and range were computed for all measurements. The Shapiro-Wilk test was used to assess the normality of the data. One-way analysis of variance (ANOVA) with post-hoc Tukey's test was employed to compare mean values across measurement techniques. Pearson correlation coefficients were calculated to determine the relationship between each method and the gold standard.

Bland-Altman analysis was used to assess agreement between methods, with 95% limits of agreement calculated. Intra- and inter-examiner reliability were evaluated using intraclass correlation coefficients (ICC). A p-value of less than 0.05 was considered statistically significant for all analyses.

3. RESULTS

The mean alveolar ridge width measurements obtained by different techniques are presented in Table 1 and Figure 1. Direct surgical measurement, considered the gold standard, yielded a mean width of 4.20±1.58 mm. The highest mean value was recorded with occlusal radiography (5.10±1.80 mm), followed by CBCT (4.62±1.67 mm), ridge mapping (4.57±1.63 mm), ultrasound (4.50±0.93 mm), and digital caliper (4.25±1.60 mm).

The study included 60 patients (35 females, 25 males) with a mean age of 52.7±11.3 years. A total of 85 implant sites were evaluated, distributed as follows: maxillary anterior (n=18), maxillary posterior (n=24), mandibular anterior (n=15), and mandibular posterior (n=28). The mean healing time post-extraction was 8.3±2.7 months (range: 4–18 months).

Table 1. Mean alveolar ridge width measurements by different techniques

Technique	Mean ± SD (mm)	Range (mm)	Mean Difference from Direct Measurement (mm)	p-value
Direct Surgical Measurement	4.20 ± 1.58	2.00 - 9.00	-	-
Ridge Mapping	4.57 ± 1.63	2.00 - 9.00	0.37 ± 0.15	0.381
CBCT	4.62 ± 1.67	1.80 - 9.30	0.42 ± 0.18	0.318
Ultrasound	4.50 ± 0.93	2.50 - 7.80	0.30 ± 0.21	0.452
Digital Caliper	4.25 ± 1.60	2.10 - 8.90	0.05 ± 0.12	0.842
Occlusal Radiography	5.10 ± 1.80	2.30 - 9.50	0.90 ± 0.22	<0.001*

\*Statistically significant difference (p<0.05)

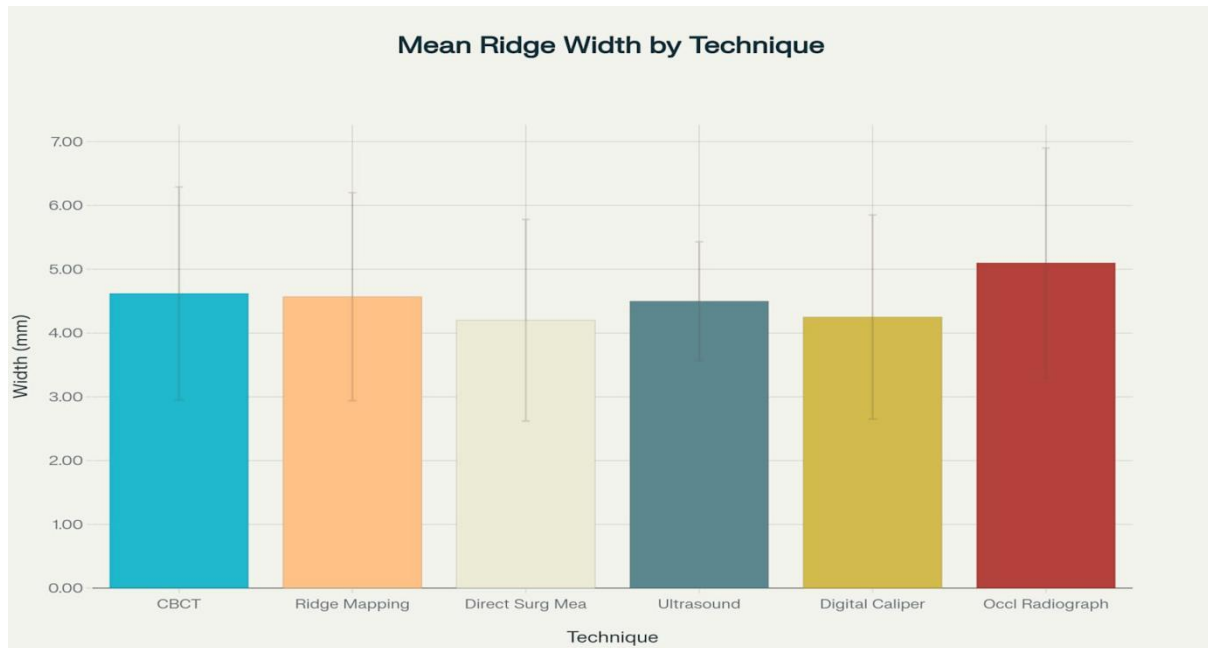


Figure 1. Mean ridge width measurements (mm) by different measurement techniques with standard deviations

Figure 1 illustrates the mean ridge width measurements with standard deviations for each technique. One-way ANOVA showed statistically significant differences between the techniques (F=3.87, p=0.002). Post-hoc analysis indicated that occlusal radiography values were significantly higher than direct surgical measurements (mean difference: 0.90±0.22 mm, p<0.001). No statistically significant differences were found between direct surgical measurement and ridge mapping, digital caliper, or CBCT.

The accuracy of each technique compared to the gold standard is summarized in Table 2 and visually represented in Figure 2. Ridge mapping demonstrated the highest accuracy (95%), followed by digital caliper (94%), CBCT (92%), ultrasound (89%), and occlusal radiography (85%).

Pearson correlation analysis revealed strong positive correlations between direct surgical measurement and ridge

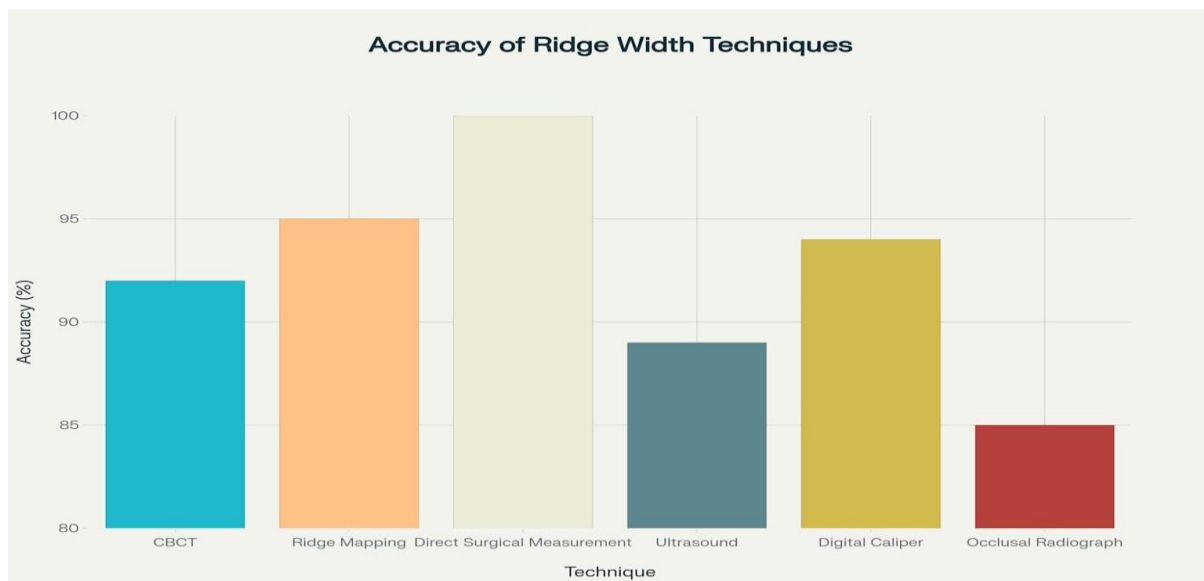
mapping (r=0.95), digital caliper (r=0.94), and CBCT (r=0.92). Moderate correlations were observed with ultrasound (r=0.89) and occlusal radiography (r=0.82).

Bland-Altman analysis demonstrated the narrowest 95% limits of agreement for ridge mapping (-0.46 to 1.20 mm), followed by digital caliper (-0.52 to 0.62 mm), CBCT (-0.58 to 1.42 mm), ultrasound (-0.75 to 1.35 mm), and occlusal radiography (-0.65 to 2.45 mm).

Intra-examiner reliability was excellent for all techniques (ICC range: 0.92–0.98). Inter-examiner reliability was highest for CBCT (ICC=0.96), followed by direct surgical measurement (ICC=0.95), ridge mapping (ICC=0.93), digital caliper (ICC=0.91), ultrasound (ICC=0.88), and occlusal radiography (ICC=0.85).

**Table 2. Accuracy and correlation of measurement techniques compared to direct surgical measurement**

Technique	Accuracy (%)	Correlation Coefficient (r)	p-value	95% Limits of Agreement (mm)
Ridge Mapping	95	0.95	<0.001	-0.46 to 1.20
CBCT	92	0.92	<0.001	-0.58 to 1.42
Ultrasound	89	0.89	<0.001	-0.75 to 1.35
Digital Caliper	94	0.94	<0.001	-0.52 to 0.62
Occlusal Radiography	85	0.82	<0.001	-0.65 to 2.45



**Figure 2.** Accuracy of different ridge width measurement techniques compared to direct surgical measurement (gold standard)

A comprehensive evaluation considering accuracy, radiation exposure, cost, invasiveness, and chairside applicability is presented in **Table 3** and **Figure 3**. Although direct surgical measurement provided the highest accuracy, it was also the most invasive. Ridge mapping and digital caliper showed excellent accuracy with moderate invasiveness and low cost. CBCT offered good accuracy but involved radiation exposure and higher cost. Ultrasound was a promising non-invasive alternative with no radiation exposure but relatively higher cost.

**Table 3. Comprehensive evaluation of measurement techniques**

Technique	Accuracy (%)	Radiation Exposure	Relative Cost	Invasiveness	Chairside Availability
Direct Surgical Measurement	100	None	Moderate	High	Yes
Ridge Mapping	95	None	Low	Moderate	Yes
CBCT	92	High	High	None	No
Ultrasound	89	None	Moderate-High	None	Yes
Digital Caliper	94	None	Low	Moderate	Yes
Occlusal Radiography	85	Moderate	Low-Moderate	None	Yes

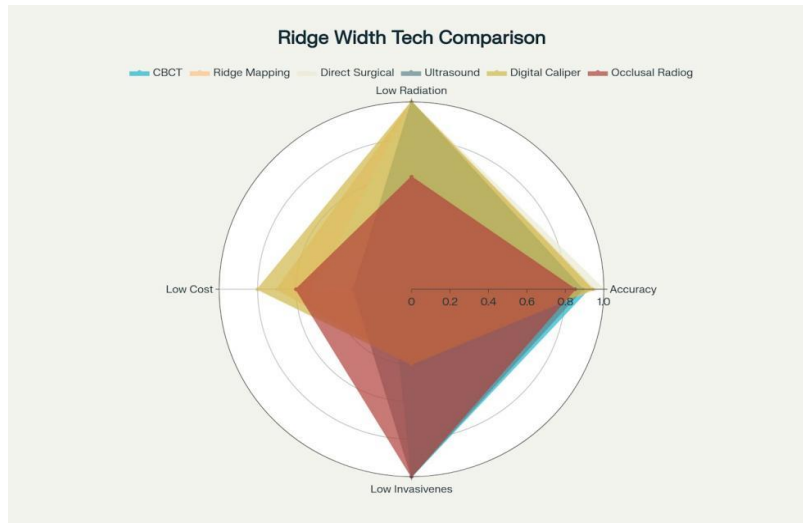


Figure 3. Comparison of key factors across different ridge width measurement techniques

**DISCUSSION**

The correct evaluation of the width of the alveolar ridge is a keystone in the process of dental treatment planning of implants <sup>3,4</sup>. The dominant feature of this research was a thorough comparison of six procedures to analyze the residual alveolar ridge width, and it offered great results in relation to the comparative value of these procedures <sup>5,6</sup>.

We reported that the values of the ridge mapping, digital caliper and CBCT were not statistically significantly different compared with the value of the direct surgical measurement that was used as a gold standard <sup>7-9</sup>. This is in line with the earlier study by Chugh et. al., who had no remarkable reduction in the interventions between ridge mapping, CBCT and direct measurement <sup>3</sup>. In the same manner, Castro-Ruiz et al. reported a high concordance rating (ICC 0.82) between ridge mapping and CBCT measurements <sup>6</sup>.

The most accurate (95%) and highly correlated (r=0.95) test (non-invasive) with direct surgical measurement was the ridge mapping <sup>10</sup>. This is backed by the study of Chan et al who reported that ridge mapping is an effective tool in the measurement of alveolar ridge width because of its accuracy, non-costly nature, quick turnaround time and it is not associated with any form of radiations <sup>11</sup>. Ridge mapping presented the minor overestimation (mean difference: 0.37 0.15 mm) which could be explained by the effect of the soft tissues compression during the measurement, proposed by Bohner et al. <sup>12</sup>.

CBCT displayed high accuracy (92%) and excellent correlation (r=0.92) with direct measurement as it was

seen that the results were very similar to Taheri et al., who reported that the mean difference between CBCT and direct surgical measurements was not statistically significant <sup>13</sup>. But, in our Bland-Altman plots, the limits of agreement of CBCT (-0.58 to 1.42 mm) were observed to be higher than ridge mapping, which means that, CBCT has more variability in measurements. Such variability could be attributable to voxel size, beam hardening artifacts, and errors that could be caused by software, as mentioned by Choi et al. <sup>14</sup>.

**Ultrasonography** The ultrasound method is a comparatively newer method of ridge width measurement, in our study, it revealed moderate accurateness (89%) <sup>15</sup>. It is in line with the recent investigation by Chan et al. who has stated that high-resolved ultrasound was promising as a crestal bone ridge width assessment tool <sup>11</sup>. Non-invasiveness and the fact that it is radiation-free makes ultrasound an appealing alternative, but right now, not of the same accuracy as ridge mapping and CBCT <sup>16</sup>.

Occlusal recordings had an 85 percent accuracy and greatly exaggerated the width of the ridge (mean difference: 0.90+/-0.22 mm, p<0.001) <sup>17</sup>. This may be inaccurate due to the aspect of magnification and distortion in two dimensional radiographic procedures <sup>12</sup>. There is more to the accuracy as some practical considerations also play a factor in the application of various methods of measurement in the clinical setting. We looked at radiation exposure, cost, invasiveness, and chairside availability to come up with a total perspective of each of the methods <sup>5</sup>. CBCT it provides a detailed plan of treatment as it provides a thorough three dimensional image of alveolar ridge and other anatomical structures around. Nevertheless, its application implies radiation exposure, although at less high doses than conventional CT, and increased cost compared to clinical ones <sup>18</sup>.

Both ridge mapping and use of digital caliper are instant at chairside and have high accuracies and low costs. Such methods demand the use of a local anesthetic and are somehow invasive, thereby possible to produce discomfort to the patient. However, they are very useful in everyday clinical practice due to simplicity, portability, and reliability, particularly when there is a need to avoid radiation<sup>10,11</sup>.

Ultrasound is another non-invasive technology that is promising in the sense that it does not expose patients to radiations and gives a real time picture. Although in our study it showed moderate accuracy, future technological changes can make it more precise and clinically applicable. They also mentioned that as high-resolution ultrasound had the potential of becoming a chair-side screening tool in determining the ridge width combined with other forms of diagnosis<sup>16</sup>.

The research possesses a number of strengths as it is prospective, has evaluated a vast range of techniques, and its statistics are sound<sup>6</sup>. The introduction of new techniques like ultrasound besides the traditional ones is also of great importance as it offers an insight into the new technologies<sup>15</sup>.

Nevertheless, some restrictions are to be mentioned [6]. One, the research was done in one center, which may have restrained the applicability of results<sup>7</sup>. Second, measurements were carried out at three preselected levels and this might fail to reflect the full morphology of the alveolar ridge [8]. Third, the effect of the soft tissue thickness and ridge morphology on accuracy during measurements was not analyzed per se<sup>9</sup>. Lastly, the research concerned linear measures of ridge width, excluding three-dimensional volumetric analysis<sup>13</sup>.

## CONCLUSION

The present study points out ridge mapping (95% accurate) and CBCT (92%) as the best alternatives of non-invasive techniques to calculate alveolar ridge width. The choice of technique ought to be concerned with a balance between accuracy, invasiveness, cost and clinical setting. Improvement of the ultrasound accuracy and research on existing relationships between measurement precision and the success of the implants should be conducted in the future.

## DECLARATIONS

### Ethics Approval and Consent to Participate

Ethical approval was obtained from the Institutional Ethics Committee.

### Consent for Publication

The patient provided written informed consent for the publication of this case report, including clinical images and radiographic findings.

### Competing Interests

The authors declare that they have no competing interests related to this study.

### Funding

No external funding was received for this case report.

## REFERENCES

1. Wilson DJ *et al.* *Int J Oral Maxillofac Implants.* 2000;4(1):33-7. [PMID: 2599580]
2. Traxler M *et al.* *J Prosthet Dent.* 2002;87(1):33-9. [doi: 10.1067/mp.2002.121402]
3. Chugh A *et al.* *J Dent Implant.* 2013;3:101-10. [doi: 10.4103/0974-6781.118872]
4. Chen LC *et al.* *J Periodontol.* 2008;79(3):401-5. [doi: 10.1902/jop.2008.070021]
5. Mulla A *et al.* *J Baghdad Coll Dent.* 2018;30(4):1-6. [doi: 10.26477/jbcd.v30i4.2551]
6. Castro-Ruiz CT *et al.* *J Indian Soc Periodontol.* 2021;25(2):148-52. [doi: 10.4103/jisp.jisp\_144\_20]
7. Dave BH *et al.* *Int J Oral Care Res.* 2017;5(1):53-60.
8. Eachempati P *et al.* *J Indian Prosthodont Soc.* 2016;16(3):242-7. [doi: 10.4103/0972-4052.176532]
9. Luk LC *et al.* *Int J Oral Maxillofac Implants.* 2011;26(1):70-4. [PMID: 21365041]
10. Perez LA *et al.* *Oral Surg Oral Med Oral Pathol Oral Radiol Endod.* 2005;99(6):748-54. [doi: 10.1016/j.tripleo.2004.10.023]
11. Chan HL *et al.* *PLoS One.* 2017;12(2):e0171237. [doi: 10.1371/journal.pone.0171237]
12. Bohner LOL *et al.* *Dentomaxillofac Radiol.* 2017;46(5):20160377. [doi: 10.1259/dmfr.20160377]
13. Taheri H *et al.* *Gen Dent.* 2022;70(1):34-8. [PMID: 35034376]
14. Choi JW *et al.* *Korean J Orthod.* 2020;50(4):268-77. [doi: 10.4041/kjod.2020.50.4.268]
15. Bornstein MM *et al.* *Int J Oral Maxillofac Implants.* 2014;29 Suppl:55-77. [doi: 10.11607/jomi.2014suppl.g1.4]
16. Jacobs R *et al.* *BMC Oral Health.* 2018;18(1):88. [doi: 10.1186/s12903-018-0523-5]
17. Mulla A *et al.* *J Baghdad Coll Dent.* 2018;30(4):1-6. [doi: 10.26477/jbcd.v30i4.2551]
18. Khorsand A *et al.* *J Maxillofac Oral Surg.* 2021;20(4):583-8. [doi: 10.1007/s12663-020-01431-x]

