



CLINICAL ARTICLE

THE USE OF A MODIFIED DEEPIHELIALISED FREE GINGIVAL GRAFT IN THE TREATMENT OF GINGIVAL RECESSIONS ASSOCIATED WITH INTERPROXIMAL BONE LOSS. CASE REPORT

Vardan Bakalyan PhD^{1*}

¹ Ass. Prof, Lecturer of the National Institute of Health, Yerevan, Armenia

* Corresponding author: Vardan L. Bakalyan PhD, Ass.Prof., National Institute of Health, Yerevan, Armenia

e-mail: vbakalyan@yahoo.com

Received: Jan 7, 2024; **Accepted:** Mar 11, 2024; **Published:** Mar 25, 2024

Abstract

The prevalence of gingival recessions is very high, and it increases with age. The gingival recessions occur frequently in populations both with high and low standards of dental care. Gingival recessions are surgically treated to improve aesthetics, reduce root hypersensitivity. Recently, the coronally advanced flap is more frequently used, displacing the free gingival graft and the laterally positioned flap. Connective tissue graft or a deepithelialised free gingival graft is often used in combination with coronally advanced flap. It has been stated, that periodontal plastic procedures may predictably determine complete root coverage in multiple Miller class I and II recessions.

According to the treatment of multiple Miller class III recessions, there is a lack of evidence by clinical trials in the literature. It should be considered, that dealing with multiple recessions can be associated with different limitations in the same surgical area, such as interproximal bone loss, larger avascular surface, position of the teeth, high muscle and frenulum attachments, etc. There is a quite big difference in the literature according to the data of complete root coverage percentage.

Another problem is dealing with black triangles because of interproximal bone loss. Of course, patients expect not only recession closure, but also papillary reconstruction. But it is very hard to predict a complete root coverage at Miller class III recession and papillary reconstruction at the same time.

The purpose of this clinical report is to evaluate the effectiveness of the coronally advanced flap in combination with modified deepithelialised free gingival graft (MDFGG). The scalloped form of the deepithelialised free gingival graft in combination with the coronally advanced flap helped to solve two problems simultaneously: recession closure and papillary reconstruction.

The results lead to further researches for the treatment of Miller class III and IV recessions, and also papillary reconstruction techniques.

Keywords: gingival recession; interproximal bone loss; deepithelialised free gingival graft; modification; papillary reconstruction.

Introduction

The gingival recession is defined as marginal tissue displacement apical to the cemento-enamel junction. The prevalence of gingival recessions (GR)

increases with age. It was shown that almost all persons above 50 years of age have at least one recession site.¹

Gingival recessions occur frequently both in populations with high standards of oral hygiene² and

in populations deprived of dental care.³ The high prevalence of GRs in populations with high standards of individual hygiene shows that mechanical factors play role in recession formation and progression.⁴ All the way, the biological mechanism of the development of GRs is not fully understood. However, the recession formation follows the pre-existing alveolar bone dehiscence.⁵ Orthodontic therapy can play a significant role in the development of GRs.⁶ It has been revealed that young adults (18-22 years old), orthodontically treated some years ago, showed twice higher risk of developing GRs than the ones, who didn't pass orthodontic treatment.⁷

GRs are surgically treated to improve aesthetics, reduce root hypersensitivity. Several techniques have been suggested to treat single recessions.⁸ These are the free gingival graft (FGG), coronally advanced flap (CAF), laterally positioned flap (LPF), modified coronally advanced flap (MCAF), coronally advanced tunnel (CAT), laterally advanced tunnel (LAT) techniques. Various degree of complete root coverage (CRC) has been achieved.⁸ Different anatomical factors can influence on the result, i.e. prominent roots, tooth rotation, high frenulum and muscle attachments, shallow vestibule, etc.⁹

Treating multiple adjacent recessions is usually more difficult because it demands more operator's manual, patient cooperation, there is more probability to have local factors interfering to achieve CRC, may be more donor tissue will be needed, which is difficult to obtain in patients especially with thin gingival phenotype, etc. Different techniques have been suggested for the treatment of multiple adjacent recessions in the last decades.¹⁰⁻¹⁴

While free gingival grafts (FGG) and laterally positioned flaps (LPF) were often used in 1970s and 1980s, the coronally advanced flap (CAF) began to displace them in clinical practice from late 1980s and is now extensively used¹⁵ due to its predictability to obtain soft tissue reconstruction and pleasant aesthetics.¹⁶ Several combinations by adding grafts, barriers or biomaterials over the root were suggested.¹⁷

It has been stated, that periodontal plastic procedures (PPP) may predictably determine CRC in multiple Miller class I and II recessions.¹⁸ There are some contradictory datas according to the use of acellular dermal matrix (ADM).^{19,20} Enamel protein derivatives (EMD),²¹ diode laser in combination with

CAF, MCAF, MCAT techniques.²⁰ The estimated differences mostly did not result to be either statistically or clinically significant and should be carefully considered.

According to the treatment of multiple Miller class III recessions, there is a lack of evidence by clinical trials in the literature.^{13,18} All the way, it should be considered, that dealing with multiple recessions can be associated with different limitations in the same surgical area, such as interproximal bone loss, larger avascular surface, position of the teeth, high muscle and frenulum attachments, etc.

There is a quite big difference in the literature according to the data of CRC percentage.¹⁸ Thombre et al., 2013, show improvement of CRC from 24 to 64% while adding ADM to CAF for the treatment of multiple Miller class I and II recession defects. This combination was only minimally inferior to the one using CTG.¹⁶ The maximal preserving of flap vascularisation by tunnelling modified CAF has also shown its efficacy.^{20,22} Aroca et al. 2009, 2010, revealed that addition of PRF or EMD did not improve the results.^{20,22}

It has to be stated, that studies with conflict of interest showed better results, as CRC, than those without conflict of interest.¹⁸

According to the lack of assurance that a Miller class III recession will be fully covered, and keeping in mind possible legal interrelations between the patient and the personnel in the case of <<insufficient>> treatment, a question can be raised: do we have to try to treat a Miller class III recession? The answer to the above-mentioned question can be the data of the following article,²¹ which state that 78,1 % of 1.647 GR defects with baseline and follow-up information show recession depth increase. The authors came to conclusion that the untreated recessions have tendency for progression during long-term follow-up.

Another problem is the presence of black triangles because of interproximal bone loss. Of course, patients' expectation is not only recession coverage, but also papillary reconstruction. It is well known, that the few techniques for papilla reconstruction are somewhat difficult to perform by young specialists and very technique sensitive.

An efficient Miller class III recession coverage technique could be created in the future with

predictable papillary reconstruction outcome.

A surgical technique is described below on a case report using a special design connective tissue graft and a coronally advanced flap.

Case Report

Patient SY, 50 years old, female, admitted with complaints of esthetics, especially in the maxillary front teeth and right premolars, also pus coming from pockets at the same sites (Figure 1a).

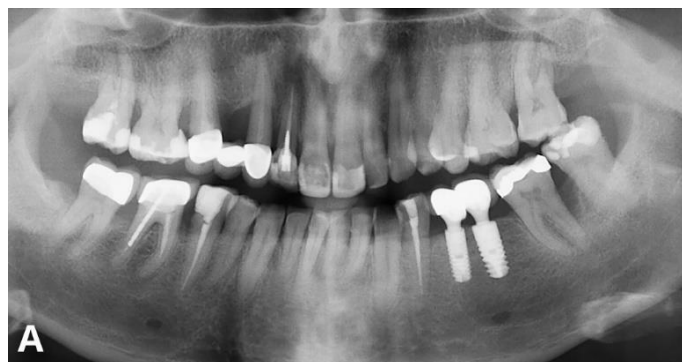


Figure 1. Panoramic x-rays. A – after initial periodontal therapy

The patient did not have medical problems, was smoking up to 10 cigarettes per day. The patient was informed about possible general and oral health problems because of smoking. Treatment plan was discussed and confirmed.

Standard initial periodontal therapy was done. Oral hygiene instructions, local antiseptics as 0,12% chlorhexidine oral rinses, full mouth scaling and root planing was done.

After 2 months pocket measurement revealed deep pockets at teeth NN 12, 13, 6-7 mms in depth, at 11-23 mean depth was 4-4.5 mms (Figure. 2a). Reconstructive surgical procedure using xenograft, without membrane, was done for the teeth NN 13-23. At the same time bone augmentation was performed at the site of tooth N14. The patient quit smoking for a few months, a week before surgery.

After 2 months pocket measurement revealed, that the pockets over teeth NN 13-23 were not more than 3mms, except dl and db of tooth N13 – 4 mms. An

implant was placed at the site of tooth N14 (Figure 1b).

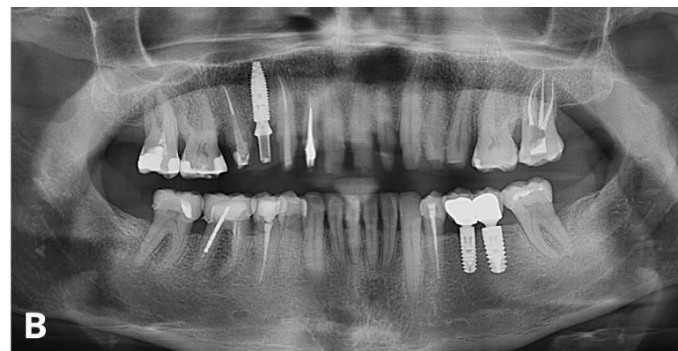

Figure 1. B – after surgical periodontal therapy and implant placement at the site of tooth N 14

The patient still was not satisfied with the esthetic outcome due to recessions on teeth NN 13,12 and black interproximal triangles between teeth NN 13, 12 and 11 (Figure 2b). Surgery was planned for recession closure over teeth NN 13,12, also papilla augmentation between teeth NN 13, 12 and 12, 11. There was also visualization of pigmented roots of teeth NN 13 and 12, so soft tissue augmentation intended to thicken the gingiva in order to mask the visualization of pigmented roots.

The surgery was performed under block anesthesia. A split thickness envelope flap was elevated from vestibular side of teeth NN 13-21 with distal oblique releasing incision at the site of tooth N 14 (Figure 2c).

The incision began in the center of the interdental papilla. It was done with the help of interdental blade, then a split thickness flap was released 2-3mms apically from the mucogingival line. Care was taken to verify the mobility of the flap in coronal direction.

A modified, scalloped full thickness free gingival graft (MFGG) was taken palatally from the teeth NN 23-25, 2.5-3 mms far from the gingival margin. The coronal contour of the graft was following the gingival margin of the neighboring teeth. The flap was 1,5-2 mms in thickness, and 5-8 mms in width (Figure 2d). The difference in width was due to scalloped contour. Attempt was made not to overthin the peaks of the graft both in thickness and width.

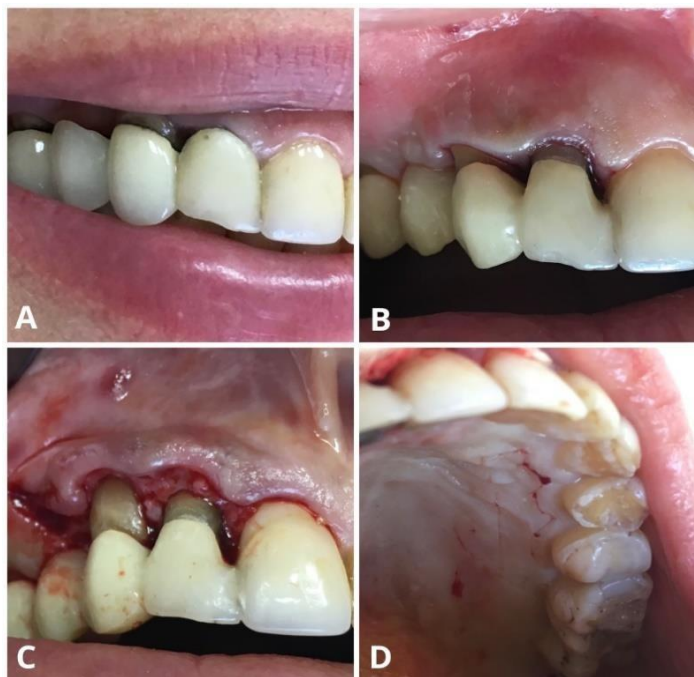

Figure 2. *A - Black triangles are seen after initial periodontal therapy; B – black triangles are seen after surgical periodontal therapy; C – a split thickness flap with distal oblique incision is released; D – the modified, scalloped form of the free gingival graft (MFGG).*

The free gingival graft (Figure 3a) was deepithelialised trying again not to overthin the peaks. The deepithelialised modified free gingival graft (DMFGG) was sutured so, that the edges of the flap (the peaks) were sutured with the palatal halves of the interdental papillae with polyglactin 6-0 (fig.3b).

The apical edge of the graft was fixed with a few simple sutures, again polyglactin 6-0 (pict. 3c). The overlying flap was sutured first distally, where the releasing incision was, and then interproximally with the help of sling sutures, taking also the underlying DFGG with polypropylene 6,0 (Figure 3d).

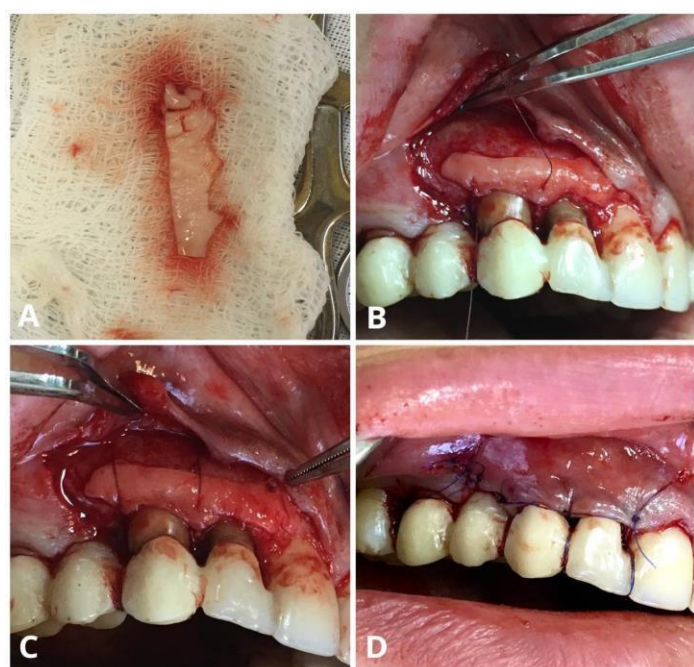


Figure 3. *A – The modified, scalloped free gingival graft (MFGG), prior to deepithelialisation; B – suturing in coronal direction; C – immobilization of the DMFGG in apical direction; D – suturing of the overlying flap*

The level of the flap edge at the time of suturing was 2,5-3 mms coronal from its preoperative level.

Postoperative medications were prescribed as follows: Amoxicillin, 500 mgs, twice a day, for 6 days, Clavulanic acid, 125mgs, twice a day, for 6

days, NSAID, first days – 2-3 times in a day, after in the case of pain. Chlorhexidine 0.12% mouth rinses were prescribed for 4 weeks. The postoperative period was without complications. The sutures were removed on the 10th - 13th day.

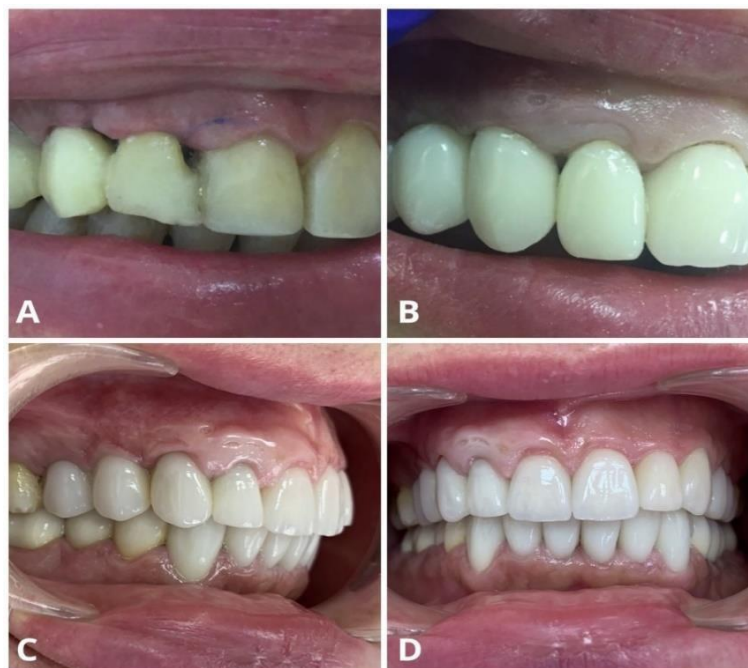

Figure 4. *A – The situation two weeks after plastic surgery; B – the gingival recontouring with temporary crowns and bridges; C, D – the final crowns and bridges. Note the papillary volume between teeth NN 14-11*

Results

One month postoperatively there was a pronounced coronal shift in the level and thickening of the soft tissues. The interdental embrasures were partially closed, the volume of the papillas significantly increased (Figure 4a). A temporary bridge was then created for final gingival contouring, 2 months after surgery. After 6 more weeks, the esthetic result was satisfactory both for us and for the patient (Figure 4b). The pocket depths were no more than 3 mms. The gingiva was enough thick and the pigmented roots were not visible through it. The final crowns and bridges were then created by the prosthodontist (Figure 4 c, d).

Discussion

This clinical case helps to reevaluate the opportunities of the periodontal plastic surgery, especially in the cases, where significant horizontal

bone loss is present. The most significant goal is the augmentation of the papillary volume and the closure of recessions class III by Millers classification.

One of the advantages of the above-described surgical technique is the less chance for necrosis of especially the interdental part of the graft, because it can be vascularized both by the periosteum and superficially from the overlying flap.

Of course, there is a need of enough interdental space to have enough wide underlying vascularizing bed, also the tissues have to be enough thick to split them without overthinning the overlying flap.

The next advantage is that beside the mandibular teeth and upper central incisors, it is enough easy to measure and take the flap from the palatal aspect of the same teeth, because it is enough to make a scalloped incision, 3 mms far from the gingival margin, trying not to overthin the peaks of the graft.

The third advantage is that because of the scalloped type of the free gingival graft the donor site is not too wide and heals rapidly.

The disadvantages are, that this type of surgery

can be mostly done for the upper jaw, where a split thickness flap, thus better vascularization is possible. Then, the width of the interdental spaces, thus, again, better vascularization is more on the upper jaw. Another disadvantage is the probability of necrosis mostly of the edges of the overlying flap, especially if they are overthinned or compressed with sutures. If such necrosis happens, the volume of the papilla will not grow enough, so the surgery can result just in thickening of the vestibular gingiva and recession closure, which is also a good result.

Other complications can be the same as for periodontal flap surgeries, split thickness flaps, free gingival grafts, deepithelialised free gingival grafts, palatal donor sites, etc.

Conclusion

A coronally positioned flap with the help of a modified, scalloped deepithelialised free gingival graft (MDFGG) can be used for recession closure and papillary reconstruction in the case of main horizontal bone loss. This can be performed for Miller's class III recession closure or class IV partial closure, and thickening of vestibular tissues to mask the transparency of the pigmented roots in the case of thin gingival biotype. But patient and segment selection

have to be done carefully due to vascularisation problems, which could arise in patients with narrow interdental spaces, thin biotype, and also smokers.

If the biotype is thin, a full thickness flap can be raised, but there is a lack of evidence, that this type of surgery will have enough positive result especially at the lower anterior segment.

Declarations

Conflicts of interest and financial disclosures

The author declares that he has no conflict percent and there was no external source of funding for the research in question.

Ethical approval

The study was approved by the University ethics committee and was conducted in accordance with the Declaration of the World Medical Association.

Source of funding

This research received no external funding.

Data Availability Statement

Not applicable.

REFERENCES

1. Loe H, Anerud A, Boysen H. The natural history of periodontal disease in man: prevalence, severity, and extent of gingival recession. *J Periodontol.* 1992;63(6):489-95. doi:10.1902/jop.1992.63.6.489
2. Sarfati A, Bourgeois D, Katsahian S, Mora F, Bouchard P. Risk assessment for buccal gingival recession defects in an adult population. *J Periodontol.* 2010;81(10):1419-25. doi:10.1902/jop.2010.100102
3. Kapferer I, Benesch T, Gregoric N, Ulm C, Hienz SA. Lip piercing: prevalence of associated gingival recession and contributing factors. A cross-sectional study. *J Periodontol Res.* 2007;42(2):177-83. doi:10.1111/j.1600-0765.2006.00931.x
4. Renkema AM, Navratilova Z, Mazurova K, Katsaros C, Fudalej PS. Gingival labial recessions and the post-treatment proclination of mandibular incisors. *Eur J Orthod.* 2015;37(5):508-13. doi:10.1093/ejo/cju073
5. Renkema AM, Fudalej PS, Renkema AA, Abbas F, Bronkhorst E, Katsaros C. Gingival labial recessions in orthodontically treated and untreated individuals: a case - control study. *J Clin Periodontol.* 2013;40(6):631-7. doi:10.1111/jcpe.12105
6. Slutzkey S, Levin L. Gingival recession in young adults: occurrence, severity, and relationship to past orthodontic treatment and oral piercing. *Am J Orthod Dentofacial Orthop.* 2008;134(5):652-6. doi:10.1016/j.ajodo.2007.02.054
7. Graziani F, Gennai S, Roldán S, Discepoli N, Buti J, Madianos P, Herrera D. Efficacy of periodontal plastic procedures in the treatment of multiple gingival recessions. *J Clin Periodontol.* 2014;41(15):S63-76. doi:10.1111/jcpe.12172

8. Cairo F, Pagliaro U, Nieri M. Treatment of gingival recession with coronally advanced flap procedures: a systematic review. *J Clin Periodontol.* 2008;35(8):136-62. doi:10.1111/j.1600-051X.2008.01267.x
9. Langer B, Calagna L. The subepithelial connective tissue graft. *J Prosthet Dent.* 1980;44(4):363-7. doi:10.1016/0022-3913(80)90090-6
10. Allen AL. Use of the supraperiosteal envelope in soft tissue grafting for root coverage. I. Rationale and technique. *Int J Periodontics Restorative Dent.* 1994;14(3):216-27
11. Zabalegui I, Sicilia A, Cambra J, Gil J, Sanz M. Treatment of multiple adjacent gingival recessions with the tunnel subepithelial connective tissue graft: a clinical report. *Int J Periodontics Restorative Dent.* 1999;19(2):199-206
12. Zucchelli G, De Sanctis M. Treatment of multiple recession-type defects in patients with esthetic demands. *J Periodontol.* 2000;71(9):1506-14. doi:10.1902/jop.2000.71.9.1506
13. Aroca S, Molnár B, Windisch P, Gera I, Salvi GE, Nikolidakis D, Sculean A. Treatment of multiple adjacent Miller class I and II gingival recessions with a Modified Coronally Advanced Tunnel (MCAT) technique and a collagen matrix or palatal connective tissue graft: a randomized, controlled clinical trial. *J Clin Periodontol.* 2013;40(7):713-20. doi:10.1111/jcpe.12112
14. Cairo F, Nieri M, Pagliaro U. Efficacy of periodontal plastic surgery procedures in the treatment of localized facial gingival recessions. A systematic review. *J Clin Periodontol.* 2014;41(15):S44-62. doi:10.1111/jcpe.12182
15. Kerner S, Katsahian S, Sarfati A, et al. A comparison of methods of aesthetic assessment in root coverage procedures. *J Clin Periodontol.* 2009;36(1):80-7. doi:10.1111/j.1600-051X.2008.01348.x
16. Thombre V, Koudale SB, Bhongade ML. Comparative evaluation of the effectiveness of coronally positioned flap with or without acellular dermal matrix allograft in the treatment of multiple marginal gingival recession defects. *Int J Periodontics Restorative Dent.* 2013;33(3):e88-94. doi:10.11607/prd.1371
17. Hirsch A, Goldstein M, Goultschin J, Boyan BD, Schwartz Z. A 2-year follow-up of root coverage using sub-pedicle acellular dermal matrix allografts and subepithelial connective tissue autografts. *J Periodontol.* 2005;76(8):1323-8. doi:10.1902/jop.2005.76.8.1323
18. Chambrone L, Faggion CM Jr, Pannuti CM, Chambrone LA. Evidence-based periodontal plastic surgery: an assessment of quality of systematic reviews in the treatment of recession-type defects. *J Clin Periodontol.* 2010;37(12):1110-8. doi:10.1111/j.1600-051X.2010.01634.x
19. Cordaro L, di Torresanto VM, Torsello F. Split-mouth comparison of a coronally advanced flap with or without enamel matrix derivative for coverage of multiple gingival recession defects: 6- and 24-month follow-up. *Int J Periodontics Restorative Dent.* 2012;32(1):e10-20
20. Aroca S, Keglevich T, Barbieri B, Gera I, Etienne D. Clinical evaluation of a modified coronally advanced flap alone or in combination with a platelet-rich fibrin membrane for the treatment of adjacent multiple gingival recessions: a 6-month study. *J Periodontol.* 2009;80(2):244-52. doi:10.1902/jop.2009.080253
21. Chambrone L, Tatakis DN. Long-Term Outcomes of Untreated Buccal Gingival Recessions: A Systematic Review and Meta-Analysis. *J Periodontol.* 2016;87(7):796-808. doi:10.1902/jop.2016.150625
22. Aroca, S., Keglevich, T., Nikolidakis D, Gera I, Nagy K, Azzi R, Etienne D. (2010). Treatment of class III multiple gingival recessions: a randomized-clinical trial. *Journal of Periodontology* 37, 88-97.

ՄՈՂԻՖԻԿԱՑՎԱԾ ԴԵՆՊԻԹԵԼԻԶԱՑՎԱԾ ԱԶԱՏ ԼՆԴԱՅԻՆ ՊԱՏՎԱՍՏՈՒԿԻ ԿԻՐԱՌՈՒՄԸ ՄԻԶԱՏԱՄՆԱՅԻՆ ՈՍԿՐԻ ԿՈՐՄՏՈՎ ՈՒՂԵԿՑՎՈՂ ԼՆԴԱՅԻՆ ՌԵՑԵՍԻՎԱՆԵՐԻ ԲՈՒԺՄԱՆ ԺԱՄԱՆԱԿ: (ԿԼԻՆԻԿԱԿԱՆ ԴԵՊԹ ԵՎԱՐԱԳՐՈՒԹՅՈՒՆ)

Վարդան Բակալյան, բ.գ.թ.¹

¹ Դասախոս, Առողջապահության ազգային ինստիտուտ, Երևան, Հայաստան

Ամփոփում

Լնդային ռեցեսիայի առաջացման հաճախականությունը բավականին բարձր է, ընդ որում այն մեծանում է տարիքի հետ: Լնդային ռեցեսիան հաճախակի հանդիպում է ինչպես բարձր, այնպես էլ ցածր մակարդակի անձնական հիգիենա ունեցող պոպուլյացիաներում:

Լնդի ռեցեսիայի բուժումը վիրահատական է: Արդյունքը ինչպես էպիտիկայի բարելավումն է, այնպես էլ գերզգայնության իջեցումը: Վերջերս, որպես վիրաբուժական տեխնիկա, լայն կիրառություն է ստացել պսակայնորեն տեղաշարժված լաթը, հետզհետե դուրս մղելով ազատ լնդային պատվաստուկի և կողմնայնորեն տեղաշարժված լաթի կիրառումը: Պսակայնորեն տեղաշարժված լաթը հաճախ օգտագործվում է շարակցահյուսվածքային տրանսպլանտատի կամ դեկայիթելիզացված ազատ լնդային տրանսպլանտատի հետ համակցված: Ապացուցված է, որ պլաստիկ պերիօդոնտալ վիրահատությունները կարող են կանխատեսելիորեն հանգեցնել ըստ Միլլերի I և II դասերի՝ բազմակի ռեցեսիաների լիարժեք փակման: Սակայն գրականության մեջ չկան բուժման հատկապես ըստ Միլլերի III դասի բազմակի ռեցեսիաների փակման վերաբերյալ բավարար քանակությամբ կլինիկական հետազոտություններ: Բազմակի ռեցեսիաների բուժման բարդությունը կայանում է նաև նրանում, որ առավել լայն սեզմենտում կարող են լինել այնպիսի սահմանափակումներ, ինչպիսիք են ինտերպրոքսիմալ ոսկրի կորուստը, ավելի լայն ավասկուլյար գոտի, ատամների ոչ ճշգրիտ դիրքը, մկանների և սանձիկների բարձր կպումները և այլն: Գրականության մեջ առկա է տվյալների և արդյունքների բավականին մեծ տարբերություն արմատի ամբողջական փակման տվյալների մասով: Մեկ այլ խնդիր է համարվում միջատամնային սև եռանկյունիների առաջացումը՝ ինտերպրոքսիմալ ոսկրի կորուստի հետևանքով: Իհարկե, ստոմատոլոգիական պացիենտները ցանկանում են ոչ միայն փակել արմատի ռեցեսիան, այլև վերականգնել ատամնապտկիկի բարձրությունը: Սակայն, ըստ առկա տվյալների՝ բավականին դժվար է կանխատեսել նմանատիպ վիրահատության արդյունքը:

Այս կլինիկական հետազոտության նպատակն է՝ պսակայնորեն տեղաշարժված լաթի հետ համակցված, դրասանգաձև, դեկայիթելիզացված ազատ լնդային տրանսպլանտատի կիրառման էֆեկտիվության գնահատումը: Պսակայնորեն տեղաշարժված լաթի հետ համակցված հատուկ ձևի դեկայիթելիզացված ազատ լնդային տրանսպլանտատի կիրառումը օգնեց միաժամանակ լուծելու երկու խնդիր՝ ըստ Միլլերի III դասի ռեցեսիայի փակումը և լնդային պտկիկի ռեկոնստրուկցիան: Նպատակահարմար է հետագա հետազոտությունների անցկացումը՝ ըստ Միլլերի III և IV դասերի ռեցեսիաների փակման և լնդային պտկիկի ռեկոնստրուկցիայի մշակման համար:

ПРИМЕНЕНИЕ МОДИФИЦИРОВАННОГО ДЕЭПИТЕЛИЗИРОВАННОГО СВОБОДНОГО ДЕСНЕВОГО ТРАНСПЛАНТАТА В ЛЕЧЕНИИ РЕЦЕССИЙ ДЕСНЫ, СОПРОВОЖДАЮЩИХСЯ ПОТЕРЕЙ МЕЖЗУБНОЙ КОСТНОЙ. (ОПИСАНИЕ КЛИНИЧЕСКОГО СЛУЧАЯ)

Вардан Бакарян, к.м.н.¹

¹ Лектор, Национального института здравоохранения, Ереван, Армения

Абстракт

Частота рецессий десны достаточно высокая, увеличиваясь с возрастом. Рецессии десны часто встречаются в популяциях как с высоким, так и недостаточным уровнем индивидуальной гигиены.

Рецессии десны лечатся хирургически. Результатом является как улучшение эстетики, так и снижение гиперчувствительности. В последнее время в качестве хирургической техники все чаще применяется коронально перемещенный лоскут, смещая свободный десневой трансплантат и латерально перемещенный лоскут. Коронально перемещенный лоскут часто используется в сочетании с соединительнотканым трансплантатом или деэпителизированным свободным десневым трансплантатом. Доказано, что пластические периодонтальные операции могут предсказуемо привести к полному закрытию множественных рецессий I и II классов по Миллеру. Однако в литературе нет достаточного количества клинических исследований относительно лечения особенно множественных рецессий III класса по Миллеру. Сложность лечения множественных рецессий состоит в том, что в более широком сегменте могут быть такие ограничения, как потеря интерпроксимальной кости, более широкая аваскулярная зона, смещенная позиция зубов, высокое прикрепление уздечек и мышц и т.д. В литературе имеется достаточно большая разница данных в результатах по полному закрытию корня.

Другой проблемой является наличие черных межзубных треугольников при потере интерпроксимальной кости. Конечно, стоматологические пациенты желают не только закрыть рецессию корня, но и восстановить высоту сосочка. Однако, по имеющимся данным, достаточно сложно прогнозировать результат операции.

Целью данной клинической презентации является оценка эффективности коронально перемещенного лоскута в сочетании с деэпителизированным свободным десневым трансплантатом особой формы.

Применение коронально перемещенного лоскута в сочетании с гирляндобразным деэпителизированным свободным десневым трансплантатом помогло одновременно решить две проблемы: закрытие рецессий III класса по Миллеру и реконструкцию сосочка.

Целесообразно проведение дальнейших исследований для разработки эффективных методов лечения рецессий III и IV классов по Миллеру, а также реконструкции сосочков.