

DOI: 10.58240/1829006X-2023.19.2-27



CLINICAL ARTICLE

**EVALUATION OF THE EFFECTIVENESS OF DIFFERENT METHODS SINUS FLOOR
ELEVATION THE LATERAL APPROACH**

Asdghig Boyadjian,^{1*} Mgrditch Boyadjian,² Artur Gevorgyan,³ Vardan Gevorgyan⁴

- ¹ Assistant professor of Department of Oral and Maxillofacial Surgery, Yerevan State Medical University, Armenia
² Boyadjian Dental Clinic, Yerevan, Armenia
³ Lectuar, Department of Oral and Maxillofacial Surgery, Yerevan State Medical University, Armeni
⁴ Lectuar, Department of Pediatric Stomatology and Orthodontics, Yerevan State Medical University, Armenia

**Corresponding author: dr. Asdghig Boyadjian; Boyadjian Dental Clinic;
e-mail: asdghigbo@gmail.com*

Received: Feb. 25, 2023; **Accepted:** Mar. 28, 2023; **Published:** Apr. 15, 2023

Abstract

Background: The posterior maxillary area sometimes has insufficient bone mass for dental implants. The augmentation of the sinus floor allows the implant to be placed in the posterior of the upper jaw.

Purpose: The aim of this study was to compare the effectiveness antral balloon- assisted maxillary sinus elevation and traditional sinus floor elevation followed by bone graft and delayed implant placement the posterior maxillary area.

Material and methods: A total of 68 patients, (aged 27 to 56 years, 32 women and 36 men), without any systemic diseases with unilateral/bilateral missing teeth and atrophy of the posterior maxillary area, who required an enlargement of the sinus prior to implant placement, whom the location of the sinus floor from the crest was 3-5mm, width ≥ 5 mm were included in the study between 2018 and 2021. Patients underwent a thorough clinical examination according to the generally accepted scheme. All patients were selected after meticulous evaluation of their medical histories and dental examinations, including OPG and dental Computed Tomography (CT) scans.

Results: The sinus lift using balloon technique was performed successfully in patients 1 group, with no complications. In 9 patients 2 group, perforation of the sinus membrane occurred during the operation, sinusitis in 4 patients, graft failure in 3 patients. Regardless of the approach used, both approaches showed significant increases in bone mass gain. Though not statistically significant difference, balloon-assisted procedure showed more mean bone gain (8.4 mm) compared to osteotome -assisted procedure (8.1 mm). The mean amount of Marginal Bone Loss (MBL) in patients 1 group 3 years follow-up was 0.86 mm in patients 2 group showed significantly less marginal bone loss 1,16mm. The implant survival rate 3 years follow-up was in patients 1 group was 97.62%, in patients 2 groups was 95.2%.

Conclusions: Research has shown that the balloon sinus lifting offers predictable, safe and effective results, and eliminates the complications associated with traditional side window techniques. However, further controlled clinical trials are needed to evaluate the efficacy and safety of these technique for their appropriate implementation in the field of oral implanotology.

Keywords: Sinus Floor Elevation, osteotome -assisted procedure, balloon- assisted maxillary sinus elevation

Introduction

Dental implants will resolve the problems associated with conventional dentures. Sufficient alveolar bone to for placement 10 mm long and a diameter of 3.5-4 mm implants has traditionally been considered the minimum requirement to allow bone placement of the implant. Due to the extraction of teeth into the segment molar and pneumatization of the maxillary sinus, the vertical height of the bone in the posterior edentulous upper jaw decreases thus limiting the installation of dental implants.¹ Bone density greatly affects primary implant stability and success, since implants in areas of lower bone quality are associated with a high failure rate.² It is important to place implants in locations with good primary stability, which cannot be acquired in regions with low bone density. Posterior maxilla often presents type III or type IV bone quality according to Lekholm and Zarb's classification.³ Increased pneumatization of the maxillary sinus and the quality of the III or IV types of bone in the posterior part of the upper jaw-all this emphasizes the need for additional procedures that increase the quality and quantity of bone.^{4,5} One solution in these clinical cases is to use shorter implants, which sometimes leads to an unfavorable crown-to-root ratio. Maxillary sinus augmentation has become the most common surgical procedure that involves detaching the Schneider membrane from the floor of the maxillary sinus, creating a space filled with a bone graft to facilitate vertical bone augmentation in the maxillary sinus cavity, allowing future dental implants to be restored.⁶ Boyne and James in 1980 proposed a conventional sinus augmentation procedure that involves direct visualization and manipulation of the Schneider membrane through a lateral window osteotomy (modified Caldwell-Luc approach).⁷ Although these procedures often ensured high implant survival and stability of bone tissue levels over time.⁸ However they were not always well accepted by patients due to their high cost, increased postoperative morbidity, high risk of infection (fistula with pus or abscess, often caused by infection of the graft material) and a long healing time. In addition to being an invasive surgical procedure, it also presents with post-operative conditions such as bleeding, edema, and membrane perforation.⁹⁻¹¹ H. Tatum in 1986 Transcrestal Sinus Floor Elevation (TSFE) was performed by lifting the sinus floor via sequential crestal bone preparations.¹²

Later, in 1994, summers introduced the osteotomy sinus floor elevation, which is a minimally invasive technique to localize the elevation of the maxillary sinus through the alveolar ridge.¹³ This approach is supposed to offer more patient comfort, more primary stability, and less morbidity. However, this method has been shown to be effective only when the crest height exceeds 6 mm. Perforation of the sinus membrane will result in deposition or interruption of the sinus lift procedure. Various modifications have been proposed to prevent complications associated with the summer's sinus floor elevation method.¹⁴ Over the past decade, many authors have developed minimally invasive sinus lift techniques to overcome the postoperative complications associated with traditional sinus lift procedures. Muronoi et al. for the first time it was proposed to enlarge the maxillary sinus floor using a balloon.¹⁵ The technique of balloon lift of the antral membrane was introduced through the lateral approach.¹⁶ Thereafter, a technique was described for minimally invasive balloon elevation of the antral membrane using a transcrestal approach, which included the use of a balloon device through a 3 mm osteotomy.¹⁷⁻¹⁹ Approach to the antrum through the lateral window and elevation of the Shneider membrane with an antral balloon is the method that has shown the lowest of membrane perforation. It elevates the membrane easily and makes the antral floor accessible for augmentation with grafting materials. The development of minimally invasive sinus lift surgery includes progress in endoscopy, development of intraoperative navigation for maxillofacial surgery. Decision making includes diagnostic and therapeutic indications, patient preferences and values, and cost considerations. After the sinus membrane lifting a variety of bone grafting materials can be used.²⁰⁻²² Since different techniques sinus lifting were evaluated in different trials, for implant failures and complications. Based on relevance question in focus in this study is the antral membrane balloon elevation technique effective in the terms of sinus augmentation success rate, survival rate of dental implants, bone gain, and complication rate compared with the traditional sinus floor elevation technique. The aim of this study was to compare the effectiveness antral balloon-assisted maxillary sinus elevation and traditional sinus floor elevation followed by bone graft and delayed implant placement the posterior maxillary area.

Material and methods

A total of 68 patients, (aged 27 to 56 years, 32 women and 36 men), without any systemic diseases, with unilateral/bilateral missing teeth and atrophy of the posterior maxillary area, who required an enlargement of the sinus prior to implant placement, were included in the study between 2018 and 2021. All patients presented functional and esthetic complaints. Written informed consent was obtained from all patients explaining the possible side effects of the procedure.

Indications of the technique in the study

The study included patients in whom the location of the sinus floor from the crest was 3–5 mm, width ≥ 5 mm (from the floor of the sinus to the crest of the bone, as determined radio graphically), a minimum follow-up period of 1-year loading.

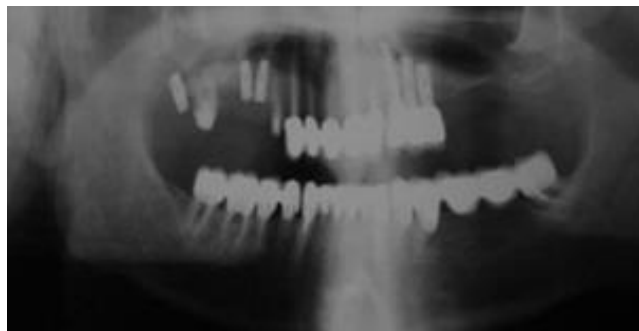

Figure 1. Preoperative radiograph

Initial height of the bone from the alveolar ridge to the sinus floor, the width of the ridge and the mesiodistal diameter of the edentulous area were measured using CT. To assess the volume of new bone and to monitor maxillary sinus re-pneumatization, CT scans were taken. These tests were conducted after the functional loading of implants and repeated after 1, 2, 3 years. Patients were divided into 2 groups; group distribution was performed randomly. In 36 patients of 1 group, implantation was performed after lateral approach antral balloon technique for sinus elevation followed by bone graft and delayed implant placement the posterior

maxillary area. In 32 patients of 2 group, implantation was performed after traditional sinus augmentation procedure (Boyne and James method) a that involves direct visualization and manipulation of the Schneider membrane through a lateral window osteotomy followed by bone graft and delayed implant placement

Contraindications of the technique in the study

Contraindications included any systemic condition that could interfere with physiological wound healing, orofacial cancer, radiation / chemotherapy to the head and neck area, Advanced medical conditions, patients who consumed oral bisphosphonates for more than three years, excessive smoking, alcohol or substance consumption, psychological problems. Local contraindications of sinus lift surgery included untreated active periodontal disease, maxillary sinus infections and pathological lesions, chronic sinusitis, alveolar scar possibility, odontogenic infections, allergic rhinitis. Patients underwent a thorough clinical examination according to the generally accepted scheme. All patients were selected after meticulous evaluation of their medical histories and dental examinations, including OPG and dental Computed Tomography (CT) scans (Figure 1).

the posterior maxillary segment. Patients were started on prophylactic antibiotic treatment 24 hours before surgery.

In patients 1 group after local anesthesia was injected into the edentulous ridge, after reflecting a mucoperiosteal flap bone scraper is used to collect autogenous bone from site of the operation (Figure 2). Opening a window on lateral wall of the maxillary sinus by round diamond bur and separating the Schneider membrane from the bony walls of maxillary sinus (Figure 3). Balloon-assisted maxillary sinus floor elevation was carried out using a Zimmer balloon (Zimmer, USA) (Figure 4).

Insertion of Zimmer balloon (Zimmer, USA) in between the sinus membrane and the bony walls to detach the remaining part of the sinus membrane from its bony walls (Figure 5). The balloon was then slowly inflated with saline (1 cm³ of saline corresponds to 6 mm membrane elevation) until the desired elevation

(usually ≥ 11 mm) was achieved. The balloon was then slowly deflated and removed.

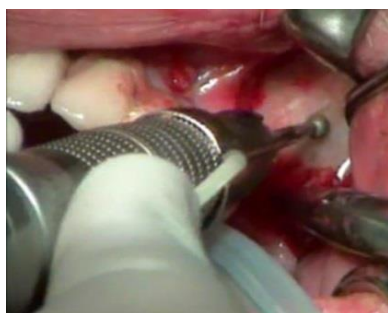

Figure 2. Bone scraper is used to collect autogenous bone from site of the operation

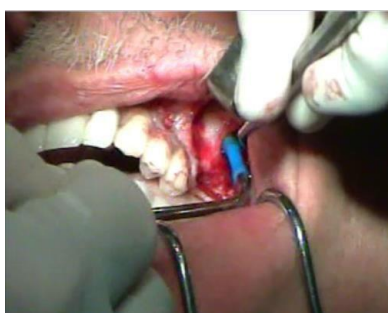

Figure 3. Opening a window on lateral wall of the maxillary sinus by round diamond bur

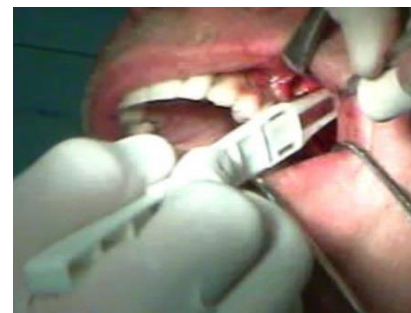

Figure 4. Insertion of Zimmer balloon in between the sinus membrane and the bony walls and inflating it with saline solution to detach the membrane from its bony walls

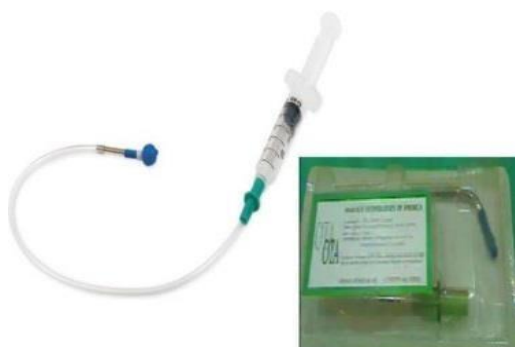

Figure 5: Zimmer balloon

Mixing the autogeneous bone which is collected from the site of the operation by a scraper with Cerasorb® (Curasan, German) crystals along with the patient's blood Platelet-Rich fibrin (Figure 6).




Figure 6. Autogeneous with Cerasorb® (Curasan, German) crystals along with the patient's blood Platelet- Rich fibrin

Bone graft material and Platelet-Rich fibrin were inserted into the sinus under the antral membrane, placement of Resodont® (Resorba Wundversorgung GmbH & Co. KG, Germany), resorbable membrane to cover the lateral wall of the sinus and separate it from the mucoperiosteal flap after which the flap was repositioned and sutured using 3-0 silk sutures (Figure 7,8,9). Radiographs were taken to assess the degree of sinus floor elevation in the surgical site after the procedure (Figure 10). The augmentation evaluated by CT scans. Patients were advised to strictly follow the postoperative instructions. Post-operative patient reactions including swelling, discoloration, discomfort, hematomas.

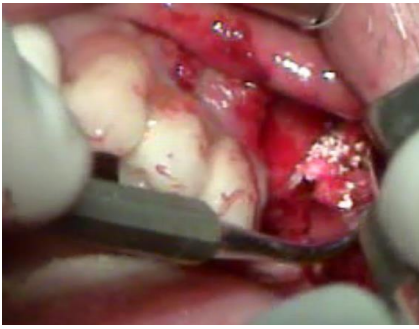

Figure 7. Augmentation of the sinus with bone graft and Platelet- Rich fibrin

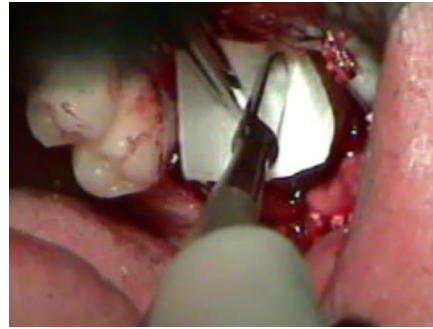


Figure 8. Resorbable Resodont® membrane to cover the lateral wall of the sinus and separate it from the mucoperiosteal flap

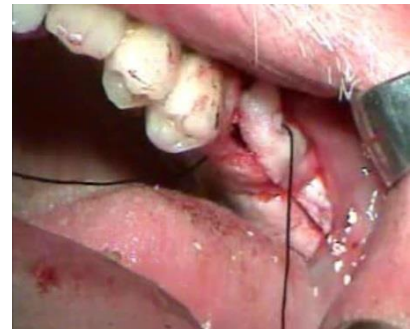

Figure 9. Suturing of the flap

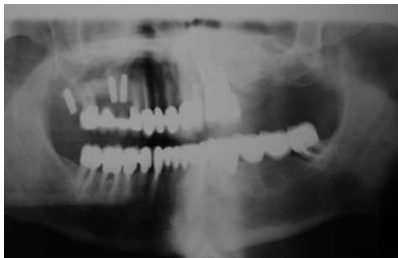

Figure 10. Postoperative radiograph after sinus lift

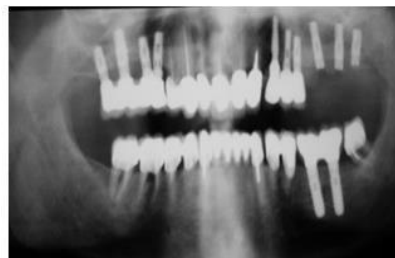

Figure 11. Radiograph after implant placement

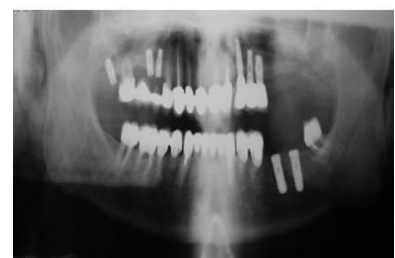

Figure 12. Final postoperative radiograph with restorations

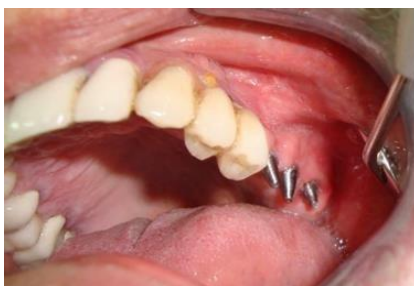

Figure 13. Intraoral view with abutments before fixation of the prosthetic construction

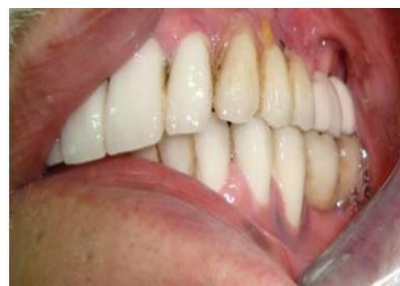

Figure 14. Final restoration with metal ceramic bridge

Implant placement was initiated 6 months post-operatively and reviewed at frequent intervals. Loading of the implants was carried out after 6 months. After removing the cover screw, healing plugs were installed and after 10 days the prosthetic stage of treatment was started (Figure 13, 14). All patients were evaluated radio- graphically after prosthetics (Figure 12) and 6th month, 1, 2, 3 years after prosthetics. The crestal bone height was maintained and verified by subsequent radiographs. In

32 patients of group 2 sinus lift procedure was performed using the traditional lateral approach method using bone graft material Resodont® and Platelet-Rich fibrin.

Midcrestal incision is made in the mesiodistal direction along the length of the alveolar crest and anterior- and posterior-releasing incisions are made. A full-thickness mucoperiosteal flap with a trapezoid base is elevated while maintaining periosteal integrity. The superior inferior and anteroposterior

borders of the lateral window are determined by the sinus volume, which is preoperatively examined by CT. The shape of the osteotomy window rectangular or oval and outlined with a size of 10×20 mm. The size of the window can increase or decrease, according to the size of the planned augmentation for implant placement. The inferior border of the bony window should be 2-5 mm superior to the sinus floor.

The elevation sinus membrane performed using broad-based freers or curettes. The prepared graft material Resodont® and Platelet-Rich fibrin is placed by pieces into the drilled hole, followed by a 6-month wait. After the bone is placed in the sinus, Resorbable Resodont® membrane to cover the lateral wall of the sinus and the mucoperiosteal flap is positioned and primary closure is achieved. Patients instructed about sinus precautions, which are avoiding anything that can cause sudden pressure changes in the sinus, such as nose blowing with nostrils pinched closed and sneezing with a closed mouth. A total of 118 implants were installed in patients 1 group and 96 implants were installed in patients 2 group. An implant was considered to have failed (clinical or absolute failure) if it had any of the following conditions: pain on function, mobility, radiographic bone loss > 1/2 the length of the implant, uncontrolled exudate, or was no longer in the mouth. Postsurgical change in Marginal Bone Loss (MBL) was assessed by digital x-ray were taken immediately (base line for comparison), 1, 2, 3 years after prosthesis loading. Statistics were used to calculate and analyze the mean marginal bone loss of implants

Statistical analyses

Statistical analyses were performed using SPSS software ver. 22.0 (IBM, Armonk, NY, USA), and MedCalc program for Windows. To test the significance of variations in the BOP, PPD, MBL, the t-test was used. The minimum level of statistical significance was set at a value of less than 0.05.

Results

The sinus lift using balloon technique was performed successfully in patients 1 group, with no complications. In 9 patients 2 group, perforation of the sinus membrane occurred during the operation, sinusitis in 4 patients, graft failure in 3 patients.

Table 1: The sinus lift complications in 1 and 2 groups

Complications	1 group	2 group
perforation of the sinus membrane	0	9
sinusitis	0	4
graft failure	0	3

Regardless of the approach used, both approaches showed significant increases in bone mass gain. Though not statistically significant difference, balloon-assisted procedure showed more mean bone gain (8.4 mm) compared to osteotome-assisted procedure (8.1 mm) table 2.

Table 2: Bone mass gain after sinus lift procedures in 1 and 2 groups

Bone mass gain	mm
1 group	8,4 mm
2 group	8,1 mm

The mean amount of Marginal Bone Loss (MBL) in patients 1 group 3 years follow-up was 0.86 mm in patients 2 group showed significantly less marginal bone loss 1,16mm table 3.

Table 3: Mean of marginal bone loss (MBL) in patients 1 and 2 groups 3 years follow-up

Mean marginal bone loss (MBL)	mm
1 group	0,86 mm
2 group	1,16 mm

In our study, delayed implant placement was performed due to insufficient initial bone height, as well as to ensure sufficient graft maturation. The implant survival rate 3 years follow-up was in patients 1 group was 97.62%, in patients 2 groups was 95.2%.

Discussions

Alveolar bone quantity and quality are the most important parameters primarily affecting the success of implant treatment. The choice of the method of rehabilitation with an implant for upper jaw atrophy is of decisive importance. Sinus lift procedures increase bone volume by augmenting the sinus cavity with autogenous bone and/or biomaterials.^{13,23,24} However, sinus floor elevation surgery is generally associated with higher costs, more complex surgical procedures,

and a high prevalence of complications such as infection, sinus membrane perforation and graft failure.^{25,26} Various techniques have been proposed to overcome this complication. Outcomes of this procedure may be affected by simultaneous versus delayed implant placement, selection of graft material, and the surface characteristics of the implants. Numerous articles have been published in this field regarding different grafting materials and modification to the classic technique. Minimally invasive balloon antral membrane lift is a surgical technique developed as a less invasive alternative to a lateral window approach that includes sinus lift using the sinus balloon followed by standard implant placement.^{27,28.}

To further simplify sinus lifting procedures and enhance their predictability and success, additional modifications technique, have been introduced during the past 10 years.²⁹ Numerous articles have been published in this field regarding different modification to the classic technique as transcresal approach, lateral window approach, piezosurgery, hydrodynamic ultrasonic approach, balloon elevation technique, osteotomy technique and nasal suction technique with their success rate. Which method to give preference when choosing the method of sinus lifting is important for the prevention of complications of surgery and is actual topic for research in the field of oral implantology.^{13,30-33} The present study was undertaken to comparison the safety and efficacy of a balloon sinus lift technique and traditional sinus lift. To compare the efficacy of balloon sinus, lift and traditional sinus lift technique, two groups of patients were formed. In patients of 1 group, lateral approach antral balloon technique for sinus elevation followed, in of 2 group traditional sinus lift procedure followed. The study used anorganic mineral and autogenous bone for the bone augmentation technique, a collagen membrane to protect the sinus window, and a staged approach for implant placement. Bone scraper was used to collect autogenous bone from the side of the operation before opening of the window and mixed with bone graft material Resodont® with along with patient's blood Platelet-Rich fibrin and covered by

resorbable membrane Resodont®. In our study, delayed implant placement was performed due to insufficient initial bone height and to ensure sufficient graft maturation. Compared to traditional sinus lift and balloon antral sinus lift have the advantage of being a high survival solution, they are less expensive, require less surgical time compared to traditional sinus lift surgery, and thus increase patient satisfaction. By incorporating efficient and efficacious materials such as anorganic bone grafting material and PRP, the balloon sinus lift technique offers an effective approach for minimally invasive sinus lifts, preventing sinus membrane perforation, reducing patient trauma, and improving implant osseointegration into grafted alveolar bone. Balloon antral sinus lift present an alternative traditional sinus lift with high survival rate and fewer complications and improving implant osseointegration into grafted alveolar bone. The process should be refined in order to reduce the percentage of mucosa perforation.

Conclusion

Research has shown that the balloon sinus lifting offers predictable, safe and effective results, and eliminates the complications associated with traditional side window techniques. Further controlled clinical trials are needed to evaluate the efficacy and safety of these techniques for their appropriate implementation in the field of oral implantology.

Conflict of interest and financial disclosure

The author declares that he has no conflict of interest and there was no external source of funding for the present study. None of the authors have any relevant financial relationship(s) with a commercial interest.

Funding

The work was not funded.

Consent statement

Written informed consent was obtained from the patient for publication of this case report and accompanying images.

REFERENCES

1. Hansson S, Halldin A. Alveolar ridge resorption after tooth extraction: A consequence of a fundamental principle of bone physiology. *J Dent Biomech.* 2012;3(0):1-8. <https://doi.org/10.1177/1758736012456543>
2. Adell R, Eriksson B, Lekholm U, Branemark PI, Jemt T. Long-term follow-up study of osseointegrated implants in the treatment of totally edentulous jaws. *Int J Oral Maxillofac Implants.* 1990;5:347-359
3. Lekholm U, Van Steenberghe D, Hermann I. Osseointegrated implants in the treatment of partially edentulous jaws: A prospective 5-year multicenter study. *Int J Oral Maxillofac Implants.* 1990;5:627-635
4. Sharan A, Madjar D. Maxillary sinus pneumatization following extractions: A radiographic study. *Int J Oral Maxillofac Implants.* 2008;23:48-56
5. Ribeiro-Rotta RF, de Oliveira RCG, Dias DR, Lindh C, Leles CR. Bone tissue microarchitectural characteristics at dental implant sites part 2: Correlation with bone classification and primary stability. *Clin Oral Implants Res.* 2014;25:47-53. <https://doi.org/10.1111/clr.12046>
6. Misch CE. Maxillary sinus augmentation for endosteal implants: Organized alternative treatment plans. *Int J Oral Implantol.* 1987;4:49-58
7. Boyne PJ, James RA. Grafting of the maxillary sinus floor with autogenous marrow and bone. *J Oral Surg.* 1980;38:613-616
8. Corbella S, Taschieri S, Fabbro DM. Long-term outcomes for the treatment of atrophic posterior maxilla: A systematic review of literature. *Clin Implant Dent Relat Res.* 2015;17:120-132. <https://doi.org/10.1155/2015/802310>
9. Farina R, Franceschetti G, Travaglini D, Consolo U, Minenna L, et al. (2018). Morbidity following transcrestal and lateral sinus floor elevation: A randomized trial. *J Clin Periodontol.* 2018;45:1128-1139. <https://doi.org/10.1111/jcpe.12985>
10. Regev E, Smith RA, Perrot DH, Pogrel MA. Maxillary sinus complications related to endosseous implants. *Int. J. Oral Maxillofac. Implant.* 1995;10:451-461
11. Schwarz L, Schiebel V, Hof M, Ulm C, Watzek G, et al. Risk factors of membrane perforation and postoperative complications in sinus floor elevation surgery: Review of 407 augmentation procedures. *J Oral Maxillofac Surg.* 2015;73:1275-1282. <https://doi.org/10.1016/j.joms.2015.01.039>
12. Summers RB. The osteotome technique: Part 3- less invasive methods of elevating the sinus floor. *Compendium.* 1994;15:698-700
13. Starch-Jensen T, Jensen JD. Maxillary sinus floor augmentation: A review of selected treatment modalities. *J Oral Maxillofac Res.* 2017;8:(3). <https://doi.org/10.5037/jomr.2017.8303>
14. Muroi M, Xu H, Shimizu Y, Ooya K. Simplified procedure for augmentation of the sinus floor using a haemostatic nasal balloon. *Br J Oral Maxillofac Surg.* 2003;41:120-121. [https://doi.org/10.1016/S0266-4356\(03\)00040-8](https://doi.org/10.1016/S0266-4356(03)00040-8)
15. Gonzalez AG, Fernández IC, Frechoso SC, Frechoso C, Felechosa AS. Minimally invasive sinus lift elevation with a silicone balloon and simultaneous implant placement. An independent 1-year follow-up clinical study. *Clin Oral Implants Res.* 2014;25:503
16. Asmael HM, Lateef TA. An assessment of the efficacy of sinus balloon technique on transcrestal maxillary sinus floor elevation surgery. *J Baghdad Coll Dent.* 2016;28:109-113. <https://doi.org/10.12816/0024718>
17. Apparaju V, Vaddamanu SK, Vyas R, Vishwanath S, Gurumurthy V, et al. Is balloon-assisted maxillary sinus floor augmentation before dental implant safe and promising? A systematic

- review and meta-analysis. *Nigerian J. Clinical Practice*. 2020;23:275-283.
18. Rao GS, Reddy SK. Antral balloon sinus elevation and grafting prior to dental implant placement: Review of 34 cases. *Int J Oral Maxillofac Implants*. 2014;29:414-418. <https://doi.org/10.11607/jomi.3075>
19. Gandhi Y. Sinus grafts: Science and techniques-then and now. *J Maxillofac Oral Surg*. 2017;16:135-144. <https://doi.org/10.1007/s12663-017-1007-x>
20. Silva LD, Lima VND, Faverani LP, Okamoto R, Pellizzer EP, et al. Maxillary sinus lift surgery-with or without graft material? A systematic review. *Int J Oral Maxillofac Surg*. 2016;45:1570-1576. <https://doi.org/10.1016/j.ijom.2016.09.023>
21. Ali S, Bakry SA, Abd-Elhakam H. Platelet-Rich fibrin in maxillary sinus augmentation: A systematic review. *J Oral Implantol*. 2015;41:746-753. <https://doi.org/10.1563/AAID-JOI-D-14-00167>
22. Kempraj J, Sundaram SS, Doss GPT, Nakeeran KP, Raja VBKK. Maxillary Sinus Augmentation Using Xenograft and Choukroun's Platelet-Rich Fibrin as Grafting Material: A Radiological Study. *Journal of Maxillofacial and Oral Surgery*. 2020;19:263-268. <https://doi.org/10.1007/s12663-019-01197-x>
23. Chen MH, Shi JY. Clinical and radiological outcomes of implants in osteotome sinus floor elevation with and without grafting: a systematic review and a meta-analysis. *J Prosthodont*. 2018;27:394-401. <https://doi.org/10.1111/jopr.12576>
24. Esposito M, Grusovin MG, Rees J, Karasoulos D, Felice P, et al. Effectiveness of sinus lift procedures for dental implant rehabilitation: a Cochrane systematic review. *Eur J Oral Implantol*. 2010;3:7-26
25. Kanayama T, Horii K, Senga Y, Shibuya Y. Crestal approach to sinus floor elevation for atrophic maxilla using platelet-rich fibrin as the only grafting material: A 1-year prospective study. *Implant Dent*. 2016;25:32-38
26. Petruzzi M, Ceccarelli R, Testori T, Grassi FR. Sinus floor augmentation with a hydropneumatic technique: A retrospective study in 40 patients. *Int J Periodontics Restorative Dent*. 2012;32:205-210
27. Kotsakis GA, Mazor Z. A simplified approach to the minimally invasive antral membrane elevation technique utilizing a viscoelastic medium for hydraulic sinus floor elevation. *Oral Maxillofac Surg*. 2015;19:97-101. <https://doi.org/10.1007/s10006-014-0473-2>
28. Leon Chen, Jennifer Cha. Achieving Predictable Hydraulic Sinus Condensing Using an Innovative Functional Sinus Implant: A Case Report. *Compendium*. 2020;41:278-283
29. Alsabbagh AY, Alsabbagh MM, Nahas BD, Rajih S. Comparison of three different methods of internal sinus lifting for elevation heights of 7 mm: An ex vivo study. *Int J Implant Dent*. 2017;3:40. <https://doi.org/10.1186/s40729-017-0103-5>
30. Ardekian L, Levit L, Michael L. Acute Sinusitis and Implant Failure Following Novel Minimally Invasive Hydraulic Sinus Lift: A Case Report. *Clin Surg*. 2018;3:1882
31. Sakkas A, Konstantinidis I, Winter K, Schramm A, Wilde F. Effect of Schneiderian membrane perforation on sinus lift graft outcome using two different donor sites: a retrospective study of 105 maxillary sinus elevation procedures. *GMS Interdiscip Plast Reconstr Surg DGPW*. 2016;5:11
32. Tallarico M, Meloni SM, Khanari E. Minimally Invasive Sinus Augmentation Procedure Using a Dedicated Hydraulic Sinus Lift Implant Device: A Prospective Case Series Study on Clinical, Radiologic, and Patient-Centered Outcomes. *Int J Periodontics Restorative Dent*. 2017;37:125-135. <https://doi.org/10.11607/prd.2914>
33. Farina R, Franceschetti G, Travaglini D, Consolo U, Minenna L, et al. Morbidity following transcrestal and lateral sinus floor elevation: a

randomized trial. *J Clin Periodontol.*
2018;45:1128-1139.
<https://doi.org/10.1111/jcpe.12985>

ԿՈՂՄՆԱՅԻՆ ՍՈՒՏՔՈՎ ՎԵՐՇՆՈՏԱՅԻՆ ԾՈՑԻ ՀԱՏԱԿԻ ԲԱՐՁՐԱՑՄԱՆ ՏԱՐԲԵՐ ՄԵԹՈԴՆԵՐԻ ԱՐԴՅՈՒՆԱՎԵՏՈՒԹՅԱՆ ԳՆԱՀԱՏՈՒՄ

Աստղիկ Բոյաջյան,¹ Մկրտիչ Բոյաջյան,² Արթուր Գևորգյան,³ Վարդան Գևորգյան⁴

- ¹ Երևանի պետական բժշկական համալսարանի վիրաբուժական ստոմատոլոգիայի և դիմաձևտային վիրաբուժության ամբիոնի ասիստենտ
- ² Բոյաջյան ստոմատոլոգիական կլինիկա, Երևան, Հայաստան
- ³ Երևանի պետական բժշկական համալսարանի վիրաբուժական ստոմատոլոգիայի և դիմաձևտային վիրաբուժության ամբիոնի դասախոս
- ⁴ Դասախոս, Երևանի պետական բժշկական համալսարանի մանկական ստոմատոլոգիայի և օրթոդոնտիայի ամբիոն

Ամփոփում

Նախապատմություն. Հետին վերձնտային հատվածը երբեմն անբավարար ոսկրային զանգված ունի իմպլանտների տեղադրման համար: Վերձնտային ծոցի հատակի բարձրացում թույլ է տալիս իմպլանտը տեղադրել վերին ձնոտի հետին մասում:

Նպատակ. Այս հետազոտության նպատակն էր համեմատել անտրալ փուչիկի օգնությամբ վերձնտային ծոցի հատակի բարձրացումը և վերձնտային ծոցի հատակի բարձրացման ավանդական մեթոդները, որին հաջորդում է ոսկրային փոխպատվաստումը և իմպլանտների հետաձգված տեղադրումը:

Նյութ և մեթոդներ. 2018-ից 2022թ. հետազոտության մեջ ներառվել են ընդհանուր 68 հիվանդ (27-ից 56 տարեկան, 32 կին և 36 տղամարդ), առանց որևէ համակարգային հիվանդությունների, միակողմանի/երկկողմանի բացակայող ատամներով և հետին վերձնտային հատվածի ատրոֆիայով, որոնց ծոցի հատակի տակ բարձրությունը 3-5 մմ էր, լայնությունը ≥ 5 մմ և նախքան իմպլանտների տեղադրումը պահանջվում էր վերձնտային ծոցի հատակի բարձրացում: Հիվանդները ենթարկվել են մանրակրկիտ կլինիկական հետազոտության՝ ընդհանուր ընդունված սխեմայի համաձայն: Բոլոր հիվանդներն ընտրվել են իրենց բժշկական պատմության մանրակրկիտ գնահատումից և ատամնաբուժական զննումներից հետո, ներառյալ OPG և ատամնաբուժական համակարգչային տոմոգրաֆիա (CT) սկանավորումները:

Արդյունքներ. Վերձնտային ծոցի հատակի բարձրացումը անտրալ փուչիկի տեխնիկայի միջոցով հաջողությամբ իրականացվել է 1-ին խմբի հիվանդների մոտ՝ առանց բարդությունների: 9 հիվանդի 2 խմբի մոտ վիրահատության ժամանակ առաջացել է ծոցի թաղանթի պերֆորացիա, 4 հիվանդի մոտ՝ սինուսիտ, 3 հիվանդի մոտ պատվաստման ձախողում: Անկախ օգտագործված մոտեցումից, երկու մոտեցումներն էլ ցույց տվեցին ոսկրային զանգվածի ավելացման զգալի աճ: Թեև վիճակագրորեն նշանակալի տարբերություն չկա, անտրալ փուչիկի օգնությամբ պրոցեդուրան ցույց է տվել ավելի միջին ոսկրային բարձրացում (8,4 մմ)՝ համեմատած օստեոտոմի օգնությամբ (8,1 մմ): 3-ամյա հսկողության ընթացքում սահմանային ոսկրային կորստի (MBL) միջին չափը հիվանդների 1-ին խմբի եղել է 0,86 մմ, հիվանդների 2-րդ խումբը ցույց է տվել զգալիորեն ավելի քիչ սահմանային ոսկրային կորուստ՝ 1,16 մմ: Իմպլանտների գոյատևման մակարդակը 3 տարի շարունակ եղել է հիվանդների 1-ին խմբի մոտ 97,62%, հիվանդների 2 խմբի մոտ՝ 95,2%:

Եզրակացություն. Հետազոտությունը ցույց է տվել, որ անտրալ փուչիկով ծոցի հատակի բարձրացումը առաջարկում է կանխատեսելի, անվտանգ և արդյունավետ արդյունքներ և վերացնում է ավանդական կողային պատուհանների տեխնիկայի հետ կապված բարդությունները: Այնուամենայնիվ, անհրաժեշտ են հետագա վերահսկվող կլինիկական փորձարկումներ՝ գնահատելու այս տեխնիկայի արդյունավետությունն ու անվտանգությունը՝ բերանի խոռոչի իմպլանտոլոգիայի ոլորտում դրանց համապատասխան իրականացման համար:

**ОЦЕНКА ЭФФЕКТИВНОСТИ РАЗЛИЧНЫХ МЕТОДОВ СИНУС-ЛИФТИНГА
БОКОВЫМ ДОСТУПОМ**

Асджиг Бояджян,¹ Мгрдитч Бояджян,² Артур Геворгян,³ Вардан Геворгян⁴

- ¹ Преподаватель кафедры челюстно-лицевой хирургии, Ереванский государственный медицинский университет, Армения
- ² Стоматологическая клиника Бояджян, Ереван, Армения
- ³ Преподаватель кафедры челюстно-лицевой хирургии Ереванского государственного медицинского университета, Армения
- ⁴ Преподаватель кафедры детской стоматологии и ортодонтии Ереванского государственного медицинского университета, Армения

Абстракт

Актуальность: В задней части верхней челюсти иногда недостаточно костной массы для установки зубных имплантатов. Увеличение дна пазухи позволяет разместить имплантат в задней части верхней челюсти.

Цель: целью данного исследования было сравнить эффективность поднятия верхнечелюстной пазухи с помощью антрального баллона и традиционного поднятия дна верхнечелюстной пазухи с последующей костной трансплантацией и отсроченной установкой имплантата в задней области верхней челюсти.

Материал и методы: Обследовано 68 пациентов (в возрасте от 27 до 56 лет, 32 женщины и 36 мужчин), без каких-либо системных заболеваний, с одно-/двусторонним отсутствием зубов и атрофией задней верхнечелюстной области, которым потребовалось расширение пазухи. до установки имплантата, у которых расстояние дна пазухи от гребня составляло 3-5 мм, ширина ≥ 5 мм, были включены в исследование в период с 2018 по 2021 год. Пациенты прошли тщательное клиническое обследование по общепринятой схеме. Все пациенты были отобраны после тщательной оценки их истории болезни и стоматологических обследований, включая ОПГ и стоматологическую компьютерную томографию (КТ).

Результаты: Синус-лифтинг баллонной техникой успешно выполнен пациентам 1 группы, без осложнений. У 9 больных 2 группы во время операции возникла перфорация оболочки пазухи, синусит у 4 больных, несостоятельность трансплантата у 3 больных. Независимо от используемого подхода, оба подхода показали значительное увеличение прироста костной массы. Хотя статистически значимой разницы нет, процедура с использованием баллона показала больший средний прирост кости (8,4 мм) по сравнению с процедурой с помощью остеотома (8,1 мм). Средняя величина потери маргинальной кости (MBL) у пациентов 1 группы через 3 года наблюдения составила 0,86 мм, у пациентов 2 группы потеря маргинальной кости была достоверно меньше 1,16 мм. Приживаемость имплантатов через 3 года наблюдения составила у пациентов 1 группы 97,62%, у пациентов 2 группы 95,2%.

Выводы: исследования показали, что баллонный синус-лифтинг дает предсказуемые, безопасные и эффективные результаты и устраняет осложнения, связанные с традиционными методами бокового окна. Однако необходимы дальнейшие контролируемые клинические испытания для оценки эффективности и безопасности этих методов для их надлежащего применения в области оральной имплантологии.