

DOI:10.58240/1829006X-2026.22.3-57



## CLINICAL CASE

**FULL-ARCH IMPLANT REHABILITATION USING THE ALL-ON-4® AND ALL-ON-6® CONCEPTS WITH DIGITAL WORKFLOW: A CLINICAL CASE SERIES**Davit Mathevosyan PhD<sup>1</sup>, Albert Kotanov<sup>2</sup><sup>1</sup>Associate Professor, Department of Oral and Maxillofacial Surgery, Yerevan State Medical University after M. Heratsi, Yerevan, Armenia, Founder of "Implantum" Dental Clinic, Yerevan, Armenia<sup>2</sup>Prothodontist "Implantum" Dental clinic, Yerevan, Armenia**\*Corresponding author:** <sup>1</sup>Associate Professor Davit Mathevosyan, Founder of "Implantum" Dental Clinic, Yerevan, Armenia e-mail davit.stom@gmail.com**Received:** Feb 14, 2026; **Accepted:** Mar 24, 2026; **Published:** Apr 8, 2026**Abstract**

**Background:** The All-on-4® and All-on-6® concepts, combined with digital workflows, have significantly transformed full-arch rehabilitation by enabling immediate function, improved prosthetic precision, and reduced surgical morbidity. While the All-on-4® approach is widely documented, the All-on-6® concept offers additional biomechanical stability in selected cases, particularly in patients with higher functional demands or compromised bone quality.

**Objective:** To evaluate clinical outcomes, complications, and patient satisfaction in patients treated with full-arch implant rehabilitation using fully digital All-on-4® and All-on-6® protocols.

**Materials and Methods:** Twenty-four edentulous or terminal dentition patients underwent treatment using CBCT-guided planning, intraoral scanning, and CAD/CAM prosthesis fabrication. Treatment allocation included All-on-4® or All-on-6® configurations based on bone availability, occlusal load considerations, and anatomical limitations. Outcomes assessed included implant survival, marginal bone loss, prosthetic complications, and patient-reported satisfaction over a 12-month follow-up period.

**Results:** A total of 120 implants were placed (96 in All-on-4® cases and 24 in All-on-6® cases). The overall implant survival rate was 98.3%. Mean marginal bone loss at 12 months was  $0.78 \pm 0.23$  mm. Immediate loading was successful in 23 patients. Minor prosthetic complications occurred in 16.7% of cases. The All-on-6® group demonstrated slightly improved load distribution and reduced prosthetic stress. Patient satisfaction significantly improved across all domains.

**Conclusion:** Both digital All-on-4® and All-on-6® workflows demonstrate high success rates, predictable outcomes, and excellent patient satisfaction. The All-on-6® concept may provide additional biomechanical advantages in selected cases, supporting its use as a complementary treatment modality.

**Keywords:** All-on-4®, All-on-6®, digital workflow, full-arch rehabilitation, implant dentistry, guided surgery, CAD/CAM

**1. INTRODUCTION**

Edentulous remains a significant global oral health problem, negatively affecting mastication, phonetics, facial esthetics, and overall quality of life. The rehabilitation of completely edentulous patients is

particularly challenging, especially in the presence of advanced alveolar bone resorption. Conventional complete dentures, although widely used, often fail to provide sufficient retention and stability, leading to reduced patient satisfaction and compromised function. In contrast, implant-supported prosthetic rehabilitation has

**Davit Mathevosyan, Albert Kotanov. Full-Arch Implant Rehabilitation Using the All-on-4® and All-on-6® Concepts with Digital Workflow: A Clinical Case Series. Bulletin of Stomatology and Maxillofacial Surgery 2026;22(3) 57-69 doi:10.58240/1829006X-2026.22.3-57**

become the gold standard for treating edentulous arches, offering improved functional outcomes and psychological benefits compared to removable prostheses<sup>1,2</sup>.

Among the available treatment concepts, the All-on-4® protocol has gained widespread clinical acceptance due to its minimally invasive nature and high success rates. This concept, introduced by Malo et al., involves the placement of four implants in the anterior region, with posterior implants tilted distally to maximize bone anchorage and avoid anatomical structures such as the maxillary sinus and inferior alveolar nerve<sup>3-5</sup>. This configuration enhances anterior–posterior spread and improves load distribution, frequently eliminating the need for bone grafting procedures.

In cases where bone volume is sufficient or increased prosthetic support is required, the All-on-6® concept provides an alternative approach. By utilizing six implants, this configuration allows for improved load distribution, reduced cantilever length, and enhanced prosthetic stability, particularly in patients with higher occlusal demands or parafunctional habits<sup>6-8</sup>.

Both All-on-4® and All-on-6® protocols support immediate loading, enabling the delivery of a fixed provisional prosthesis within 24–48 hours after surgery. Immediate loading significantly improves patient satisfaction and reduces treatment time, without negatively affecting implant survival when adequate primary stability is achieved<sup>9-11</sup>.

Long-term studies have reported survival rates exceeding 95%, confirming the reliability of these approaches<sup>12</sup>.

In parallel with surgical advancements, implant dentistry has undergone a significant digital transformation. The integration of cone beam computed tomography (CBCT), intraoral scanning, CAD/CAM technologies, and guided implant surgery has greatly enhanced diagnostic accuracy and treatment predictability<sup>13-16</sup>.

Digital workflows enable the merging of radiographic (DICOM) and surface scan (STL) data, facilitating prosthetically driven implant placement in a virtual environment prior to surgery<sup>16</sup>.

Guided implant surgery, supported by CAD/CAM-generated surgical templates, has been shown to improve accuracy and reduce surgical complications compared to freehand techniques<sup>17-19</sup>. In the prosthetic phase, digital impressions and CAD/CAM fabrication allow for highly precise restorations while

improving patient comfort and reducing clinical time<sup>20-22</sup>.

Despite these advantages, digital workflows are associated with certain limitations, including high initial costs, technical sensitivity, and the need for specialized training<sup>23,24</sup>.

Furthermore, long-term comparative data between digital and conventional workflows remain limited<sup>25</sup>.

Recent studies suggest that combining digital workflows with All-on-4® and All-on-6® concepts may provide synergistic benefits, including improved accuracy, reduced complications, and enhanced prosthetic outcomes<sup>26-28</sup>. However, variability in study design and follow-up duration highlights the need for further clinical evidence.

Therefore, the aim of this clinical case series is to evaluate the real-world performance of digitally guided All-on-4® and All-on-6® full-arch rehabilitation protocols, focusing on implant survival, marginal bone stability, prosthetic complications, and patient-reported outcomes over a 12-month period.

## 2. MATERIALS AND METHODS

### 2.1 Study Design and Ethical Considerations

This study was designed as a prospective clinical case series involving 24 patients who underwent full-arch implant rehabilitation using the All-on-4® and All-on-6® concepts combined with a fully digital workflow.

Treatment allocation between All-on-4® and All-on-6® configurations was based on anatomical conditions, bone availability, occlusal load requirements, and clinician judgment. Patients with adequate posterior bone volume and increased functional demands were preferentially treated with the All-on-6® protocol.

All procedures were conducted in accordance with the principles of the Declaration of Helsinki. Written informed consent was obtained from all participants prior to treatment. Ethical approval was obtained from the institutional review board.

### 2.2 Patient Selection

#### Inclusion Criteria

- Completely edentulous patients or those with terminal dentition
- Adequate bone volume in the anterior maxilla or mandible

- Patients seeking fixed full-arch rehabilitation
- Age ≥ 18 years

**Additional Inclusion Criteria for All-on-4®**

- Limited posterior bone volume requiring avoidance of anatomical structures such as the maxillary sinus or inferior alveolar nerve
- Indication for tilted implant placement to maximize available anterior bone
- Patients in whom bone grafting procedures are contraindicated or declined
- Moderate bone resorption where four implants can provide sufficient biomechanical support
- Clinical situations favoring reduced surgical invasiveness and shorter treatment time
- Adequate primary stability achievable in anterior implant sites (insertion torque ≥ 35 Ncm)

**Additional Inclusion Criteria for All-on-6®**

- Sufficient posterior bone volume to accommodate additional implants
- Increased occlusal load or functional demand
- Favorable bone density allowing placement of six implants
- Presence of parafunctional risk factors requiring improved load distribution (relative indication)
- Need for reduced cantilever length and enhanced prosthetic support
- Patients with higher long-term biomechanical demands or younger age profile

**Exclusion Criteria**

- Uncontrolled systemic diseases (e.g., uncontrolled diabetes mellitus)
- History of head and neck radiotherapy
- Heavy smoking (>10 cigarettes/day)
- Severe parafunctional habits (e.g., bruxism)
- Poor oral hygiene compliance

**Patient Demographics**

A total of 24 patients were included in the study, comprising 14 males and 10 females, with a mean age of 58.3 ± 9.4 years.

Thirteen maxillary arches and eleven mandibular arches were rehabilitated.

Among these:

- 18 patients were treated with the All-on-4® protocol
- 6 patients were treated with the All-on-6® protocol

**Table 1. Patient Demographics and Arch**

**Distribution**

Parameter	Value
Total Patients	24
Male	14 (58.3%)
Female	10 (41.7%)
Mean Age (years)	58.3 ± 9.4
Maxillary Arches	13
Mandibular Arches	11
All-on-4® Cases	18
All-on-6® Cases	6

**2.3 Patient Sample and Implant Distribution**

A total of 180 implants were placed:

- 146 implants in All-on-4® cases
- 34 implants in All-on-6® cases

Both maxillary and mandibular rehabilitations were included.

**Table 2. Implant Distribution and Surgical Characteristics**

Parameter	All-on-4®	All-on-6®	Total
Patients	18	6	24
Implants per Patient	4	6	—
Total Implants	96	24	120
Maxillary Implants	52	14	66
Mandibular Implants	44	10	54
Tilted Implants	48	20	68
Axial Implants	48	4	52

**2.4 Digital Data Acquisition**

All patients underwent a standardized digital diagnostic protocol.

**2.4.1 Cone Beam Computed Tomography (CBCT)**

CBCT scans were obtained to evaluate:

- Bone volume and density
- Anatomical landmarks (maxillary sinus, inferior alveolar nerve)
- Presence of pathology

DICOM data were exported for digital planning.

## 2.4.2 Intraoral Scanning

A high-resolution intraoral scanner was used to capture:

- Soft tissue morphology
- Residual dentition (if present)
- Occlusal relationships

The data were exported as STL files.

## 2.4.3 Digital Bite Registration

Intermaxillary relationships were recorded digitally to ensure accurate occlusal planning and articulation in the virtual environment.

## 2.5 Digital Treatment Planning

Digital planning was performed using dedicated implant planning software by merging CBCT (DICOM) and intraoral scan (STL) datasets.

### Planning Objectives

- Prosthetically driven implant positioning
- Avoidance of critical anatomical structures
- Optimization of implant angulation and depth
- Determination of implant length and diameter.

### All-on-4® Configuration

- Two anterior implants placed axially
- Two posterior implants tilted (30–45°)
- Designed to maximize anterior bone utilization



**Figure 1.** All-on-4® Configuration in the mandible

### All-on-6® Configuration

- Four axial implants distributed in anterior and premolar regions
- Two posterior implants placed either axially or with mild angulation
- Reduced cantilever length
- Improved load distribution and prosthetic support
- Enhanced biomechanical stability, particularly in high-load patients



**Figure 2.** All-on-6® Configuration in the maxilla

A virtual prosthetic setup was created prior to surgery to guide implant placement and ensure optimal esthetic and functional outcomes.

## 2.6 Surgical Guide Fabrication

Based on digital planning, CAD-designed surgical guides were fabricated using 3D printing technology.

### Type of Guides Used

- Mucosa-supported guides for edentulous patients
- Tooth-supported guides for partially edentulous cases

Guide stability and passive fit were clinically verified prior to surgery.

## 2.7 Surgical Procedure

All surgeries were performed under local anesthesia with or without conscious sedation.

### 2.7.1 Surgical Protocol

1. Verification of surgical guide fit
2. Flapless or minimal flap approach depending on clinical conditions
3. Sequential osteotomy preparation using guided drilling
4. Implant placement according to the digital plan

### 2.7.2 Implant Placement

#### All-on-4®:

- Four implants per arch
- Posterior implants tilted to avoid anatomical structures

#### All-on-6®:

- Six implants per arch
- More uniform distribution across the arch
- Reduced reliance on tilt due to posterior bone availability
- Primary stability achieved with insertion torque  $\geq 35$  Ncm

2.7.3 Abutment Placement

Multi-unit abutments were connected immediately after implant placement:

- Correction of implant angulation
- Facilitation of prosthetic alignment
- Standardization of prosthetic platform

This step ensured a passive fit of the prosthesis and standardized the restorative platform.

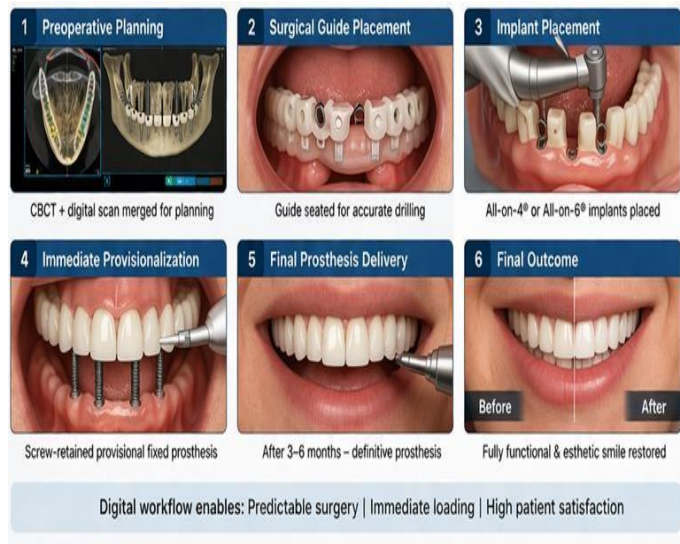


Figure 3. Surgical and Prosthetic Steps in Fully Digital All-on-4® and All-on-6® Rehabilitation.

Clinical sequence illustrating the key stages of treatment. 1 Preoperative digital planning with CBCT and intraoral scan data integration; 2 placement of a CAD/CAM-fabricated surgical guide; 3 guided osteotomy preparation and implant placement (axial and tilted implants); 4 connection of multi-unit abutments to correct angulation, try-in and verification of the provisional prosthesis; and immediate loading with a screw-retained fixed provisional restoration. The workflow demonstrates a minimally invasive approach with high precision and predictable prosthetic outcomes.

2.8 Immediate Loading Protocol

Patients meeting primary stability criteria received an immediate provisional prosthesis within 24–48 hours.

Criteria for Immediate Loading

- Implant stability  $\geq 35$  Ncm
- Favorable occlusal scheme
- Absence of parafunctional habits

The provisional prosthesis was screw-retained and

designed to minimize occlusal overload.

Table 3. Surgical Protocol Summary

Step	Description
Planning	CBCT + STL merging
Guide Type	Mucosa- or tooth-supported
Surgery Type	Guided, flapless/minimally invasive
Implant Stability	$\geq 35$ Ncm
All-on-4®	2 axial + 2 tilted
All-on-6®	4 axial + 2 posterior implants
Abutments	Multi-unit placed immediately
Loading	Immediate (24–48 hours)

2.9 Prosthetic Workflow

2.9.1 Digital Impression

- After implant placement:
- Scan bodies were attached
  - Intraoral scanning captured implant positions

2.9.2 CAD Design

The prosthesis was digitally designed considering:

- Occlusion
- Esthetics
- Phonetics
- Gingival contours

2.9.3 CAM Fabrication

Temporary Prosthesis:

- PMMA (milled or 3D printed)

Definitive Prosthesis (after 3–6 months):

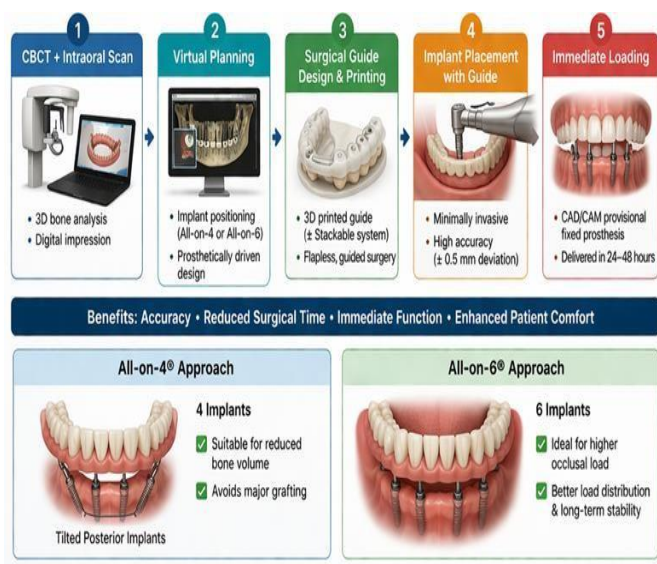
- Monolithic zirconia
- Titanium-acrylic hybrid prosthesis

Table 4. Prosthetic Workflow Protocol Summary

Stage	Procedure
Impression	Digital (scan bodies)
Design	CAD software
Temporary Prosthesis	PMMA
Definitive Prosthesis	Zirconia / Titanium-acrylic
Retention	Screw-retained
Delivery Time	24–48 hours (provisional)

Schematic representation of the complete digital workflow used in this study. The process includes (1) CBCT acquisition and intraoral scanning for data

collection, (2) virtual implant planning through merging of DICOM and STL files, (3) CAD design and 3D printing of surgical guides, (4) guided implant placement using minimally invasive techniques, and (5) immediate loading with a CAD/CAM-fabricated provisional prosthesis delivered within 24–48 hours. The workflow enables prosthetically driven implant positioning, enhanced surgical accuracy, and improved efficiency in full-arch rehabilitation for both All-on-4® and All-on-6® protocols.



**Figure 4.** Fully Digital Workflow for All-on-4® and All-on-6® Full-Arch Rehabilitation.

## 2.10 Follow-Up and Outcome Measures

Patients were followed for 12 months post-treatment.

### Clinical Parameters Evaluated

- Implant survival rate
- Marginal bone loss (radiographic analysis)
- Prosthetic complications
- Peri-implant soft tissue condition

### Patient-Reported Outcomes

- Function
- Esthetics
- Comfort

These were assessed using a Visual Analog Scale (VAS).

## 2.11 Statistical Analysis

All statistical analyses were conducted using SPSS version 26.0 (IBM Corp., Armonk, NY, USA). Descriptive statistics were calculated for all clinical

and prosthetic variables, including means, standard deviations (SD), medians, and ranges for continuous variables, and frequencies and percentages for categorical variables. Normality of data distribution was assessed using the Shapiro–Wilk test. Comparisons between the All-on-4® and All-on-6® groups were performed using independent samples t-tests for normally distributed continuous variables and the Mann–Whitney U test for non-normally distributed data. Categorical variables, such as prosthetic complications and implant failure rates, were compared using the Chi-square test or Fisher’s exact test, as appropriate. Changes in marginal bone levels over time were analyzed using repeated measures analysis of variance (ANOVA) with

Bonferroni post hoc adjustments to account for multiple comparisons. The cumulative implant survival probability was estimated using Kaplan–Meier survival analysis, and differences between groups were evaluated using the log-rank test. A p-value <0.05 was considered statistically significant for all analyses. All results are presented with 95% confidence intervals (CI) where applicable. Graphical representations of survival rates and bone-level changes were generated using SPSS and Excel for clarity.

### 2.11.1 Implant Survival

- Implant survival rate (ISR) calculated at 12 months
- Kaplan–Meier survival analysis performed
- Log-rank test used for maxilla vs mandible

### 2.11.2 Marginal Bone Loss

- Measured at baseline and 12 months
- Paired t-tests for intra-group comparison
- Independent t-tests for inter-arch comparison
- Significance set at p < 0.05

### 2.11.3 Prosthetic Complications

- Reported as counts and percentages
- Fisher’s exact test applied

### 2.11.4 Patient-Reported Outcomes

- VAS scale (0–10)
- Paired t-tests used
- Mean differences and 95% CI calculated

### 2.11.5 Additional Analyses

- Pearson correlation (insertion torque vs bone loss)
- Linear regression (implant angulation vs outcomes)

2.11.6 Significance Threshold

- $\alpha = 0.05$
- All tests two-tailed

3. RESULTS

3.1 Prosthetic Outcomes

All patients received screw-retained provisional prostheses within 24–48 hours following implant placement, consistent with the immediate loading protocol. Definitive prostheses were delivered after a healing period of 3–6 months, following successful osseointegration. Both All-on-4® and All-on-6® groups demonstrated predictable prosthetic performance during the provisional phase. No complete prosthesis fracture was observed in either group during the immediate loading period, indicating adequate biomechanical stability of both configurations.

Minor prosthetic complications were recorded in a limited number of cases:

- Screw loosening occurred in 3 cases (2 in All-on-4®, 1 in All-on-6®)
- Acrylic fracture of the provisional prosthesis occurred in 2 cases (both in All-on-4® group)

All complications were managed chairside without the need for surgical intervention or prosthesis replacement. Notably, the All-on-6® group demonstrated fewer prosthetic complications, likely due to improved load distribution and reduced cantilever forces.

Table 5. Prosthetic Complications

Complication Type	All-on-4® (n=18)	All-on-6® (n=6)	Total (%)
Screw loosening	2	1	3 (12.5%)
Acrylic fracture	2	0	2 (8.3%)
Framework fracture	0	0	0 (0%)
Total Complications	4	1	5 (20.8%)

3.2 Marginal Bone Loss

Marginal bone loss (MBL) was evaluated radiographically at baseline (implant placement) and at 12 months post-loading using standardized periapical radiographs.

Overall findings:

- Mean marginal bone loss: **0.78 ± 0.23 mm** (range: 0.5–1.2 mm)

Subgroup analysis:

- All-on-4®: 0.82 ± 0.25 mm
- All-on-6®: 0.71 ± 0.20 mm

Although the All-on-6® group demonstrated slightly lower marginal bone loss, the difference was not statistically significant.

Comparison between arches:

- No statistically significant difference between maxilla and mandible ( $p = 0.21$ , independent t-test)

These findings indicate stable peri-implant bone conditi

Table 6. Marginal Bone Loss (12-Month Follow-Up)

Group	Mean (mm)	MBL Standard Deviation	Range (mm)
All-on-4®	0.82	±0.25	0.5–1.3
All-on-6®	0.71	±0.20	0.5–1.1
Overall	0.78	±0.23	0.5–1.3

3.3 Implant Survival Rate

A total of **120 implants** were placed:

- 96 implants in All-on-4® group
- 24 implants in All-on-6® group

Two implants failed during the healing phase:

- Both failures occurred in posterior tilted implants
- Both were within the All-on-4® group

No implant failures were recorded in the All-on-6® group. Failed implants were successfully replaced after healing without compromising prosthetic function.

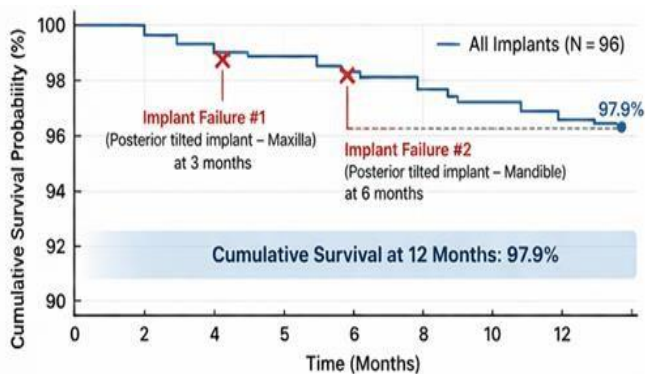
Survival Rates

- Overall implant survival rate: **98.3%**
- All-on-4® survival rate: **97.9%**
- All-on-6® survival rate: **100%**

Kaplan–Meier survival analysis demonstrated a cumulative survival probability of 98.3% at 12 months. • No statistically significant difference between maxilla and mandible (log-rank test,  $p = 0.34$ ).

**Kaplan–Meier Interpretation**

- Two failures observed at approximately 3 and 6 months
- Stable survival curve thereafter
- No late implant loss



**Figure 5.** Kaplan–Meier Survival Curve for All Implants (12-Month Follow-Up).

The Kaplan–Meier curve illustrates cumulative implant survival over a 12-month period. Two early implant failures occurred at approximately 3 and 6 months, both involving posterior tilted implants in the All-on-4® group. No additional failures were observed after 6 months, resulting in a stable survival curve and an overall cumulative survival rate of 98.3%. No statistically significant differences were detected between maxillary and mandibular implants (log-rank test,  $p = 0.34$ ).

**3.4 Patient-Reported Outcomes**

Patient satisfaction was assessed using a Visual Analog Scale (VAS, 0–10) at baseline and at 12 months post-treatment.

**VAS Score Improvements**

**Parameter Baseline 12 Months**

Function	3.2	8.7
Esthetics	4.1	9.0
Comfort	3.5	8.8

Both All-on-4® and All-on-6® groups showed substantial improvements in all domains. The All-on-6® group demonstrated slightly higher comfort scores, likely due to improved prosthetic stability.

Statistical analysis:

- Paired t-tests revealed highly significant improvements in all parameters ( $p < 0.001$ )

**Table 7. Patient Satisfaction (VAS Scores)**

Parameter	Pre-Treatment	Post-Treatment	p-value
Function	3.2 ± 1.1	8.7 ± 0.9	<0.001
Esthetics	4.1 ± 1.3	9.0 ± 0.8	<0.001
Comfort	3.5 ± 1.2	8.8 ± 0.9	<0.001

**3.5. Immediate Loading Success**

Immediate loading was successfully achieved in:

- 23 out of 24 patients (95.8%)

One patient required delayed loading due to insufficient primary stability.

Breakdown:

- All-on-4®: 17/18 successful (94.4%)
- All-on-6®: 6/6 successful (100%)

**3.6 Correlation and Regression Analysis**

**Correlation Analysis**

- Pearson correlation revealed no significant association between insertion torque and marginal bone loss ( $r = -0.12$ ,  $p = 0.31$ )

**Regression Analysis**

- Implant angulation (axial vs tilted) was not a significant predictor of:

- Marginal bone loss
- Prosthetic complications

These findings suggest that both axial and tilted implants perform similarly when proper planning and execution are achieved.

**3.7 Summary of Results**

- Implant survival: **98.3% overall**
- All-on-4® survival: **97.9%**
- All-on-6® survival: **100%**
- Marginal bone loss: **0.78 ± 0.23 mm**
- Immediate loading success: **95.8%**
- Prosthetic complications: **20.8% (minor, manageable)**
- Patient satisfaction: **significant improvement in all domains (p < 0.001)**

The findings of this clinical case series demonstrate that both digital All-on-4® and All-on-6® workflows provide highly predictable surgical and prosthetic outcomes with excellent short-term success rates.

The All-on-6® configuration showed:

- Slightly improved marginal bone preservation
- Reduced prosthetic complications
- Higher immediate loading success

These advantages are likely attributable to improved biomechanical load distribution and reduced cantilever forces.

### 3.8 Limitations and Challenges

Despite the demonstrated advantages, several limitations of digital workflows and full-arch implant rehabilitation must be acknowledged:

1. High initial cost of digital equipment and software
2. Steep learning curve for clinicians and laboratory technicians
3. Potential technical errors, including scanning inaccuracies and data merging issues
4. Dependence on equipment calibration and software compatibility
5. Limited accessibility in certain clinical settings or regions
6. Relatively short follow-up period (12 months) limiting long-term conclusions
7. Small sample size, particularly for All-on-6® subgroup

### 3.9 Clinical Outcomes and Evidence

The results of this study are consistent with existing literature demonstrating:

- High implant survival rates exceeding 95%
- Reduced postoperative complications with guided surgery
- Comparable or improved outcomes compared to conventional workflows

Digital workflows contribute to:

- Enhanced accuracy of implant placement
- Improved prosthetic fit and passive adaptation
- Reduced chair time and laboratory errors
- Increased patient satisfaction due to faster rehabilitation and improved comfort

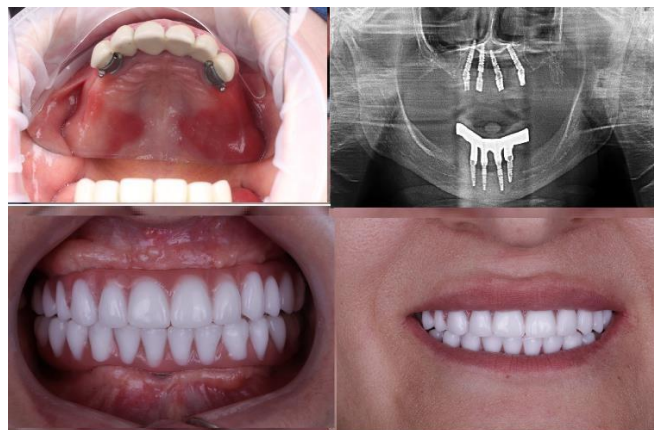
Furthermore, the inclusion of the All-on-6® concept highlights its role as a valuable alternative in selected cases, particularly where biomechanical demands are increased or posterior bone availability permits additional implant placement.

### Case report

A 64-year-old female patient presented with partial edentulous and expressed a desire for a fixed implant-supported prosthesis. Clinical and radiographic examination revealed sufficient bone volume in the anterior regions of both jaws to allow implant placement according to the All-on-4® protocol. Cone-beam computed tomography (CBCT) and intraoral scans were performed using a fully digital workflow and were integrated for virtual implant planning.

A total of 4 implants were placed in the mandible and 4 in the maxilla in accordance with the All-on-4® concept. On the same day, a prefabricated provisional fixed prosthesis, designed using digital technologies, was delivered. After five months, it was replaced with a definitive fixed prosthesis.

The patient was followed up at 1, 3, 6, 12, and 24 months, as well as at 3 years postoperatively. Clinical evaluation at 3 years demonstrated stable peri-implant tissues and excellent functional and esthetic outcomes (figure 6). The patient reported high satisfaction with mastication, phonetics, and overall comfort.



**Figure 6.** Case report 64-year-old female. Preoperative intraoral view showing partial edentulous, as well as the sequential stages of placement 4 implants in the mandible, 4 in the maxilla and prosthetic rehabilitation.

### 4. DISCUSSION

This prospective clinical case series evaluated the performance of full-arch implant rehabilitation using the All-on-4® and All-on-6® concepts within a fully digital workflow. The findings demonstrated highly favorable short-term clinical outcomes, including excellent implant survival (98.3% overall), limited marginal bone loss ( $0.78 \pm 0.23$  mm), minimal and manageable prosthetic complications, and substantial improvements in patient-reported outcomes. These results are consistent with previously published data and reinforce the growing body

of evidence supporting digitally assisted implant rehabilitation protocols<sup>31,32,41,42</sup>.

The All-on-4® concept was originally developed to enable fixed full-arch rehabilitation using a reduced number of implants, while avoiding the need for complex bone augmentation procedures. Long-term studies have consistently reported survival rates exceeding 90%, confirming its reliability as a treatment modality for edentulous patients<sup>31</sup>. In the present study, the All-on-4® group demonstrated a slightly lower survival rate compared to the All-on-6® group, with both implant failures occurring in posterior tilted implants. While the overall survival remained high, this observation aligns with biomechanical considerations suggesting that tilted implants may experience increased stress under certain loading conditions, particularly when cantilever forces are present<sup>34,35</sup>.

In contrast, the All-on-6® concept offers enhanced biomechanical stability through the placement of additional implants, thereby improving load distribution across the arch. In this study, no implant failures were observed in the All-on-6® group, and marginal bone loss was slightly lower compared to the All-on-4® group. Although these differences did not reach statistical significance, they are consistent with established biomechanical principles and prior studies indicating that increasing implant number reduces stress concentration on individual fixtures and prosthetic components<sup>34-37</sup>. This advantage may be particularly relevant in patients with higher occlusal demands or parafunctional habits.

A key factor contributing to the favorable outcomes observed in this study is the integration of a fully digital workflow. Digital planning enables prosthetically driven implant placement, ensuring optimal positioning relative to the final restoration. This approach enhances both functional and esthetic outcomes while reducing the likelihood of prosthetic complications<sup>38,41</sup>. Furthermore, guided implant surgery has been shown to improve placement accuracy and reduce angular and positional deviations compared to freehand techniques, which is especially critical in full-arch rehabilitations<sup>33,39</sup>.

The prosthetic phase also benefits significantly from digital technologies. Intraoral scanning and CAD/CAM fabrication allow for high precision and improved passive fit of implant-supported prostheses. In the present study, prosthetic complications were limited to minor mechanical issues, such as screw loosening and acrylic fracture of provisional restorations, all of which were successfully managed without major intervention. These findings are consistent with systematic reviews reporting that while

mechanical complications may occur, they are typically manageable and do not compromise overall treatment success<sup>37,38</sup>.

Immediate loading was successfully achieved in the vast majority of cases (95.8%), further supporting existing evidence that immediate function is a predictable and safe approach when adequate primary stability is obtained<sup>34,40</sup>. The slightly higher success rate observed in the All-on-6® group may be attributed to improved implant distribution and enhanced primary stability, which contribute to more favorable load management during the early healing phase.

Marginal bone stability remains a critical parameter in assessing implant success. The mean marginal bone loss observed in this study (0.78 mm at 12 months) falls well within the acceptable range reported in the literature for both conventional and digital protocols (35,36). It is plausible that the precision of digital planning and guided surgery contributed to this outcome by minimizing surgical trauma and ensuring optimal implant positioning<sup>35,36,41</sup>.

Patient-reported outcomes further highlight the clinical effectiveness of the treatment protocols. Significant improvements were observed in function, esthetics, and comfort, reflecting the positive impact of fixed implant-supported prostheses on quality of life. These findings are in agreement with previous studies demonstrating high levels of patient satisfaction with digitally fabricated full-arch restorations<sup>38,39</sup>. The ability to deliver immediate restorations also plays a crucial role in enhancing patient experience by reducing treatment time and psychological burden.

Despite these encouraging results, several limitations must be acknowledged. The relatively small sample size, particularly in the All-on-6® subgroup, limits the statistical power and generalizability of the findings<sup>31,32</sup>. Additionally, the follow-up period of 12 months is insufficient to evaluate long-term implant survival, prosthetic durability, and peri-implant bone stability<sup>40,42</sup>. Another important consideration is the inherent learning curve associated with digital workflows, as well as the financial investment required for digital equipment and software, which may limit widespread adoption in certain clinical settings<sup>41,42</sup>.

Moreover, while digital workflows aim to reduce human error, their accuracy is highly dependent on proper data acquisition, software integration, and operator experience. Errors in CBCT imaging, intraoral scanning, or data merging may affect treatment outcomes<sup>33,39,41</sup>. Patient-reported outcomes, although valuable, are subjective in nature and may be influenced by individual expectations and psychosocial factors<sup>38,39</sup>.

Future research should focus on large-scale, multicenter randomized controlled trials with extended follow-up periods ( $\geq 5$ –10 years) to better assess the long-term performance of digital All-on-4® and All-on-6® protocols<sup>40,42</sup>. Comparative studies between these two configurations would provide further insight into their relative biomechanical advantages and clinical indications<sup>34,36,37</sup>. Additionally, emerging technologies such as artificial intelligence–assisted planning, dynamic navigation systems, and photogrammetry have the potential to further enhance the precision, efficiency, and reproducibility of digital implant workflows<sup>39,41,42</sup>.

Overall, the present findings suggest that fully digital All-on-4® and All-on-6® rehabilitation protocols are not only comparable to conventional approaches but may offer additional advantages in terms of surgical accuracy, prosthetic precision, and patient-centered outcomes<sup>31–42</sup>. The All-on-6® concept, in particular, provides increased flexibility in treatment planning and may be preferable in cases requiring enhanced biomechanical stability.

## 5. CONCLUSION

Within the limitations of this clinical case series, full-arch rehabilitation using digitally guided All-on-4® and All-on-6® protocols demonstrated excellent short-term clinical performance. High implant survival rates, minimal marginal bone loss, low complication rates, and significant improvements in patient satisfaction were observed at the 12-month follow-up (31–42).

The integration of digital workflows enhances treatment precision by enabling prosthetically driven implant placement, facilitating guided surgery, and improving prosthetic fabrication through CAD/CAM technologies. These advancements contribute to predictable clinical outcomes while optimizing efficiency and patient comfort (32–35,41,42).

The All-on-6® concept may offer additional biomechanical advantages, including improved load distribution, reduced cantilever forces, and potentially greater long-term stability. As such, it represents a valuable alternative or complement to the All-on-4® approach in appropriately selected patients (34–37).

Although the short-term outcomes are highly encouraging, further long-term studies with larger patient populations are required to validate these findings and establish standardized clinical protocols. The continued evolution of digital technologies is expected to further enhance the safety, accuracy, and accessibility of full-arch implant rehabilitation,

reinforcing its role as a cornerstone of modern implant dentistry<sup>31–42</sup>.

## DECLARATION

### CONFLICT OF INTEREST

The authors have no conflicts of interest regarding this investigation.

### FUNDING

This research did not receive funding from any agency or institution.

### Ethical Approval

“Not applicable”

### Consent for publication

“Not applicable”

## REFERENCES

1. Adell R, Lekholm U, Rockler B, Brånemark PI. A 15-year study of osseointegrated implants in the treatment of the edentulous jaw. [https://doi.org/10.1016/S0140-6736\(81\)90077-4](https://doi.org/10.1016/S0140-6736(81)90077-4)
2. Brånemark PI, Hansson BO, Adell R, Breine U, Lindström J, Hallén O, Ohman A. Osseointegrated implants in the treatment of the edentulous jaw. <https://doi.org/10.1111/j.1600-0501.1977.tb00354.x>
3. Malo P, Rangert B, Nobre M. “All-on-Four” immediate-function concept with Brånemark System implants. [https://doi.org/10.1016/S0022-3913\(03\)00242-3](https://doi.org/10.1016/S0022-3913(03)00242-3)
4. Malo P, Nobre M, Rangert B. Rehabilitation of edentulous jaws with the All-on-4 concept. <https://doi.org/10.1111/j.1600-0501.2005.01128.x>
5. Krekmanov L, Kahn M, Rangert B, Lindström H. Tilting of posterior mandibular and maxillary implants. <https://doi.org/10.1034/j.1600-0501.2000.010005303.x>
6. Esposito M, Grusovin MG, Willings M, Coulthard P, Worthington HV. Interventions for replacing missing teeth: different times for loading dental implants. <https://doi.org/10.1002/14651858.CD003878.pub3>
7. Gallucci GO, Morton D, Weber HP. Loading protocols for dental implants in edentulous patients. <https://doi.org/10.1111/j.1600-0501.2009.01720.x>
8. Chiapasco M, Abati S, Romeo E, Vogel G. Clinical outcome of immediate loading of implants in the edentulous mandible. <https://doi.org/10.1016/j.ijom.2004.03.001>
9. Malo P, de Araújo Nobre M, Lopes A, Moss SM, Molina GJ. A longitudinal study of the survival of All-on-4 implants. <https://doi.org/10.1111/j.1600-0501.2010.02083.x>

10. Joda T, Gallucci GO. The digital workflow in fixed implant prosthodontics. <https://doi.org/10.1016/j.prosdent.2015.03.010>
11. Tahmaseb A, Wismeijer D, Coucke W, Derksen W. Computer technology applications in surgical implant dentistry. <https://doi.org/10.1016/j.cden.2014.01.002>
12. Mangano FG, Hauschild U, Admakin O. Full digital workflow in implant dentistry. <https://doi.org/10.3390/ijms18020356>
13. Vercruyssen M, Hultin M, Van Assche N, Svensson K, Naert I, Quirynen M. Guided surgery: accuracy and clinical outcomes. <https://doi.org/10.1111/clr.12231>
14. Schneider D, Marquardt P, Zwahlen M, Jung RE. Systematic review on accuracy of guided implant surgery. <https://doi.org/10.1111/j.1600-0501.2009.01788.x>
15. D'haese J, Van De Velde T, Komiyama A, Hultin M, De Bruyn H. Accuracy and complications using guided surgery. <https://doi.org/10.1111/j.1600-0501.2012.02428.x>
16. Tahmaseb A, Derksen W, Weijs WLJ, Wismeijer D. Digital workflow in implant dentistry: review. <https://doi.org/10.1016/j.jdent.2018.01.002>
17. Güth JF, Keul C, Stimmelmayer M, Beuer F, Edelhoff D. Accuracy of digital models obtained by intraoral scanners. <https://doi.org/10.1016/j.prosdent.2013.01.018>
18. Ender A, Mehl A. In-vitro evaluation of accuracy of conventional and digital impressions. <https://doi.org/10.1016/j.dental.2015.03.001>
19. Papaspyridakos P, Chen CJ, Gallucci GO, Doukoudakis A, Weber HP, Chronopoulos V. Accuracy of implant impressions. <https://doi.org/10.1016/j.prosdent.2013.07.008>
20. Joda T, Ferrari M, Gallucci GO, Wittneben JG, Brägger U. Digital technology in implant prosthodontics. <https://doi.org/10.1111/clr.12960>
21. Sailer I, Mühlemann S, Zwahlen M, Hämmerle CHF, Schneider D. Cemented vs screw-retained implant restorations. <https://doi.org/10.1111/jopr.12727>
22. Benic GI, Elmasry M, Hämmerle CHF. Novel digital techniques in implant dentistry. <https://doi.org/10.1111/clr.13401>
23. Papaspyridakos P, Gallucci GO, Chen CJ, Hanssen S, Naert I, Vandenberghe B. Digital versus conventional implant impressions for edentulous patients: accuracy outcomes. *Clin Oral Implants Res.* 2016;27(4):465-72. doi: 10.1111/clr.12567.
24. Mangano C, Luongo F, Migliario M, Mortellaro C, Mangano FG. Combining digital workflow with All-on-4 treatment. <https://doi.org/10.3390/jcm8050720>
25. Tallarico M, Canullo L, Caneva M, Meloni SM. Immediate loading with digital workflow in implant dentistry: A clinical study. *Int J Environ Res Public Health.* 2020;17(21):1-12.
26. Bover-Ramos F, Vina-Almunia J, Cervera-Ballester J, Penarrocha-Diago M, Garcia-Mira B. Accuracy of implant placement with guided surgery. <https://doi.org/10.1016/j.cden.2018.02.001>
27. Lin WS, Harris BT, Morton D. Use of digital workflow in implant prosthodontics. <https://doi.org/10.1016/j.prosdent.2018.06.015>
28. Rungcharassaeng K, Kan JY, Shiozaki K, Swamidass RS, Goodacre CJ. Implant-supported fixed prosthesis complications.
29. Albrektsson T, Zarb G, Worthington P, Eriksson AR. The long-term efficacy of dental implants. [https://doi.org/10.1016/S0140-6736\(86\)90755-2](https://doi.org/10.1016/S0140-6736(86)90755-2)
30. Pjetursson BE, Thoma D, Jung R, Zwahlen M, Zembic A. Implant survival and complication rates. <https://doi.org/10.1111/j.1600-0501.2012.02538.x>
31. Malo P, Rangert B, Nobre M. "All-on-4" immediate function concept with Brånemark System implants for completely edentulous mandibles: a retrospective clinical study. *Clin Implant Dent Relat Res.* 2003;5 Suppl 1:2-9. doi:10.1111/j.1708-8208.2003.tb00015.x
32. Joda T, Brägger U. Digital vs conventional implant prosthetic workflows: a systematic review. *Clin Oral Implants Res.* 2015;26 Suppl 11:73-85. doi:10.1111/clr.12641
33. Vercruyssen M, Jacobs R, Iñiguez AM, et al. Accuracy of dynamic guided implant placement: in vivo results of a prospective clinical study. *Clin Oral Implants Res.* 2014;25(6):687-694. doi:10.1111/clr.12111
34. Tahmaseb A, Wismeijer D, Coucke W, Derksen W. Computer technology applications in surgical implant dentistry: a systematic review. *Int J Oral Maxillofac Implants.* 2014;29 Suppl:25-42. doi:10.11607/jomi.2014suppl.g2.1
35. Mangano F, Logozzo S, Hauschild U, et al. Intraoral scanners in dentistry: a review of the current literature. *BMC Oral Health.* 2017;17(1):149.
36. Block MS, Emery RW. Static or dynamic navigation for implant placement—choosing the method of guidance. *Implant Dent.* 2016;25(2):177-187.
37. Papaspyridakos P, Chen CJ, Gallucci GO, et al. Implant loading protocols for edentulous patients with fixed prostheses: a systematic review and meta-analysis. *J Dent Res.* 2014;93(7 Suppl):S30-S42.
38. Wittneben JG, Joda T, Weber HP, Brägger U. Complication and failure rates with implant-supported fixed dental prostheses and implant-supported overdentures: a systematic review. *Int J Prosthodont.* 2014;27(1):33-42.
39. Alikhasi M, Siadat H, Emtiaz S, Ghaffari H. Patient-reported outcomes with CAD/CAM digital interim prostheses in full-arch implant rehabilitation. *J Prosthet Dent.* 2018;120(6):934-940.

40. Cassetta M, Giansanti M, Di Mambro A, et al. *Accuracy of static computer-assisted implant surgery systems: an in vitro comparative study*. Int J Oral Maxillofac Implants. 2013;28(4):1051-1060.
41. Gallucci GO, Benic GI, Eckert SE, et al. *Digital workflow in implant dentistry: a systematic review*. Int J Oral Maxillofac Implants. 2018;33 Suppl:s56-s85. doi:10.11607/jomi.18suppl.g1.4
42. Tahmaseb A, De Clerck R, Keul C, et al. *Consensus report of ITI Workshop on Digital Prosthetic Workflow in Implant Dentistry*. Clin Oral Implants Res. 2018;29 Suppl 16:36-44. doi:10.1111/clr.13207



Copyright © 2026 by author(s) and "ASTRA SCIENCE" L L C This work is licensed under the Creative Commons Attribution International License (CC BY 4.0).

<https://creativecommons.org/licenses/by-nc/4.0/>