

DOI: 10.58240/1829006X-2023.19.2-124



## MANIFESTATIONS OF SEXUALLY TRANSMITTED INFECTIONS IN THE ORAL CAVITY

Ophelia Kocharyan<sup>1</sup><sup>1</sup> Obstetrician-gynecologist Clinic Medical Center, Lahta clinic, St. Preburg

\*Corresponding author-dr Ophelia Kocharyan, Medical Center Lahta clinic, RF, St. Preburg, Savushkina street 73;  
e-mail: [fascinating\\_gynecology@mail.ru](mailto:fascinating_gynecology@mail.ru)

**Received:** Feb. 24, 2023; **Accepted:** Mar. 24, 2023; **Published:** Apr. 15, 2023

**Abstract**

Sexually transmitted diseases are transmitted in the oral cavity through various forms of sexual activity. This article discusses the relevant clinical manifestations of several sexually transmitted viruses, including human papillomavirus, chlamydia trachomatis, and gonorrhea. Oral manifestations of these infections include ulcerative, inflammatory, or papillomatous lesions of the lips, tongue, mucous membranes, and throat, and may also present with oropharyngeal cancer. The literature review used the databases Google Scholar, PubMed, Scopus, Web of Science.

**Keywords:** oral manifestations; sexually transmitted diseases

**Intraduction**

Sexually transmitted diseases often affect the mucous membranes, causing characteristic lesions on the oral mucosa.<sup>1</sup>

Membranes of the oral cavity are vulnerable to direct inoculation of many of these infections. Oral contact with the genitals can create tiny microtraumas through which pathological microorganisms in body fluids can come into contact and be transmitted.<sup>2</sup>

Oral sex is one of the most common ways of transmitting sexually transmitted infections (STIs). STIs that can be contracted through oral sex:

- chlamydia
- gonorrhea
- herpes
- genital warts
- hepatitis (A, B and C)
- HIV
- Syphilis

Depending on the transferred pathogen, ulcerative, inflammatory or papillomatous lesions of the lips, tongue, mucous membranes and pharynx occur.

Today, the authors estimate that about 75% of women report having had oral sex. The authors attribute its growing popularity to a common misconception that oral sex is relatively safe compared to intercourse that requires a condom to protect against.<sup>3</sup> The authors emphasize that this sexual practice comes with other risks, such as potential female infertility.

Identification of sexually transmitted infections in oral cavity characteristic clinical signs allows for early diagnosis and treatment.

This article presents a literature review of Oral manifestations of sexually transmitted infections and the clinical picture of these diseases in the oral cavity. We conducted a literature review of scientific papers, using the resources of the Google Scholar, PubMed, Scopus, Web of Science and embase search engines, for the above keywords. For this analysis, we used articles containing an evidence-based experimental and clinical base on the most recent issues related to

the epidemiology, etiology and pathogenesis of Sexually transmitted diseases (STDs).

Human papillomavirus (HPV) is the most common sexually transmitted disease.<sup>4</sup> HPV can affect the mouth and throat. Some high-risk strains, notably HPV-16, have been linked to head and neck cancers, which are four times more common in men than women. These cancers usually develop in the throat at the base of the tongue, in the folds of the tonsils, or at the back of the throat, making them difficult to detect.

Although the oral transmission of HPV is not clear, various sexual habits such as early sexual initiation, increased number of partners, and orogenital sex have made HPV an endemic infection. It has been postulated that the incidence of HPV-associated tumors is related to changes in sexual practices. A significant proportion of squamous cell carcinoma of the mucous membranes of the head and neck, especially the oropharynx, is directly related to HPV. As a result, some studies have shown the role of viruses in the development of head and neck cancer.

HPV infections are often asymptomatic and unrecognized. Most sexually active people become infected with HPV at least once in their lives<sup>6</sup>, often unaware of it and without showing any symptoms. HPV infection prevalence, persistence, and infection correlate with sexual behavior, viral load, anatomical location, local immunity, and clearance.<sup>5,6</sup>

Despite evidence that HPV is an etiologic risk factor for head and neck cancers, especially HPV type 16, there are few population-based studies on the mechanisms of HPV transmission. Initial studies have shown that smoking, age, and HIV-positive serostatus are risk factors.<sup>7</sup>

The human papillomavirus (HPV) is responsible for a growing percentage of head and neck cancers (HNCs); primarily, a subset of oral squamous cell carcinoma, oropharyngeal squamous cell carcinoma, and laryngeal squamous cell carcinoma. Most HPV-associated head and neck cancers (HPV + HNC) are caused by HPV16; in addition, cofactors such as smoking and immunosuppression promote HPV+HNC progression by interfering with tumor suppressor siRNA and disrupting immune system mediators.<sup>8</sup>

Case-control studies of head and neck cancer have shown an association with the number of sexual partners, history of oral-genital contacts, history of genital warts, and age at first intercourse.<sup>9-11</sup>

Head and neck cancer, the sixth most common cancer in the world, accounts for approximately 1 in 20 malignancies. In recent years, there has been a decrease in the incidence of cervical cancer, but a concomitant significant increase in the incidence of HPV-mediated oropharyngeal cancer caused by orogenital transmission of HPV. Consequently, in rich countries, oropharyngeal squamous cell carcinoma (OPSCC) is currently the most common HPV-associated cancer, overtaking cervical cancer. Orogenital transmission of HPV has now overtaken smoking and excessive alcohol consumption as the main risk factor for oropharyngeal cancer.<sup>12</sup>

Human papillomavirus (HPV) accounts for the majority of sexually transmitted infections (STIs). Oral sexual behavior is an important factor contributing to HPV infection of the oral mucosa. HPV infection of the oral mucosa is believed to affect between 1% and 50% of the general population, depending on the method used for diagnosis. The immune system clears most HPVs naturally within 2 years (about 90%), but those that persist can cause serious illness. HPV is an important carcinogen that is increasingly causing cancers that occur in many places in the body.

Increased oral transmission of HPV eventually leads to increased head and neck infections; Thus, oral sex is associated with the majority of HPV infections in the head and neck region.

Head and neck cancer (HNC) accounts for ~4.8% of cancers, and 90 percent of HNCs arise from squamous cells lining the mouth, pharynx, larynx, or, less commonly, the nasal cavity.<sup>13</sup>

These include: (i) oral squamous cell carcinoma (OSCC), which is a cancer that occurs on the lips, tongue, floor of the mouth, oral cavity, etc.; (ii) oropharyngeal squamous cell carcinomas (OPSCCs), which are cancers arising from the base of the tongue, soft palate, tonsils, back of the throat; (iii) squamous cell carcinoma of the larynx (LSCC), which arises from the supraglottic, vocal, and subglottic regions; (iv) nasal squamous cell carcinoma (NSCC; to a lesser extent), which arises from squamous epithelial cells lining the nasal cavity and paranasal sinuses.<sup>14,15</sup>

Factors such as alcohol consumption, tobacco smoking and/or chewing increase the risk of HNC.<sup>16,17</sup>

Alcohol consumption is associated with ~5% of HNC cases, tobacco use is associated with ~34%, and alcohol combined with tobacco use is associated with

36% of ~HNC cases [5,7,9]; thus ~75% of HNC (i.e. squamous cell carcinoma) is caused by alcohol and tobacco use.<sup>18</sup>

The remaining percentage (~25%; world average) of HNC cases are caused by human papillomaviruses (HPV).<sup>19,20</sup>

HPV also causes almost all cases of cervical cancer, a percentage of other anogenital cancers (vaginal, vulvar, anal, penile, etc.) and almost all cases of genital warts.<sup>21</sup>

HPV associated with HNC is transmitted orally, mainly through oral sex. Studies have shown that oral sexual activities, as well as an increase in the number of oral sexual partners, transmission of HPV.<sup>22,23</sup> A high number of HPV infections in the head and neck area have been reported in men compared with women.<sup>24,25</sup> This is likely due to the large number of men who have oral sex with partners infected with HPV. Thus, oral sex is associated with the majority of HPV infections in the head and neck region. Deep kissing (with open mouth) has also been reported to be

associated with oral transmission of HPV. HPV has been found on the oral mucosa of men/women without a history of oral sex who have had ≥10 deep kisses in a lifetime or ≥5 deep kisses in a year.<sup>23</sup>

HPV can be transmitted by self-vaccination from the genital area to the mouth area through infected nails.<sup>26,27</sup>

**The HPV + OCSCC Prevalence Worldwide**

In addition, both low and high levels of HPV incidence have been reported in all geographical locations. The lowest prevalence of HPV+ OCSCC has been found in the Philippines, the United Kingdom (UK), India, the Republic of Korea and France. The highest prevalence is reported to be 37% in Jordan. A proportional meta-analysis was conducted, determining the total prevalence of HPV+ OCSCC to 6% (95% CI; 3–10%)<sup>28</sup>. There was a great heterogeneity in the prevalence as well,  $I^2 > 75%$ ,  $p < 0.01$ , shown in Figure 1.

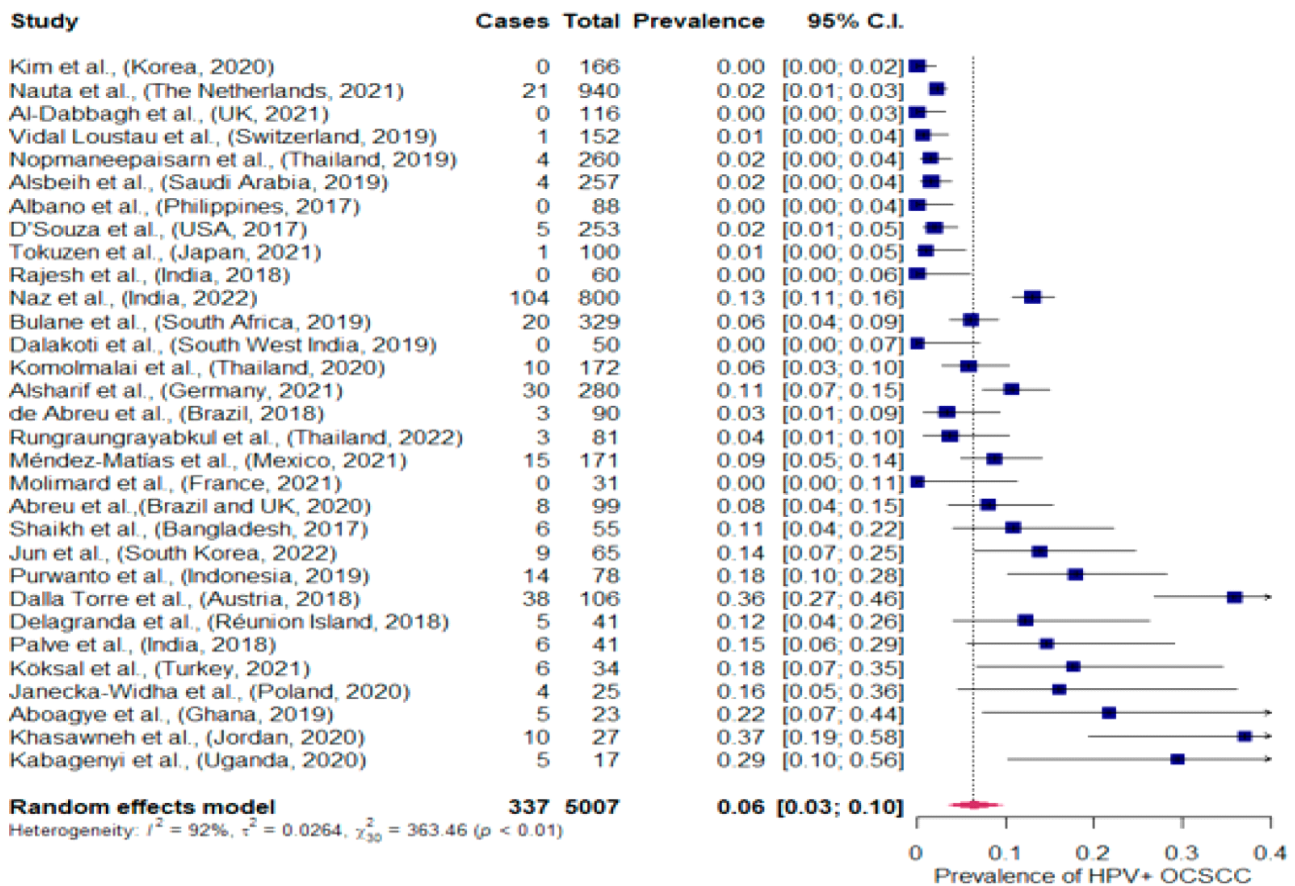


Figure 1. Meta-analysis of the HPV+ OCSCC prevalence in the included studies, representing the present HPV+ OCSCC prevalence worldwide HPV+: human papillomavirus positive [OCSCC: oral cavity squamous cell carcinoma. 95% C.I: confidence interval]

**Distribution of human papillomavirus-associated head and neck cancers (HPV + HNC) between anatomical sites**

HPV status in tumors located at different anatomical subsites of the oral cavity was reported in studies. These cancers usually develop in the throat at the base of the tongue, in the folds of the tonsils, or at the back of the throat, making them difficult to detect.<sup>29</sup> Around 30% of oropharyngeal cancers (which mainly comprises the tonsils and base of tongue sites) are caused by HPV.

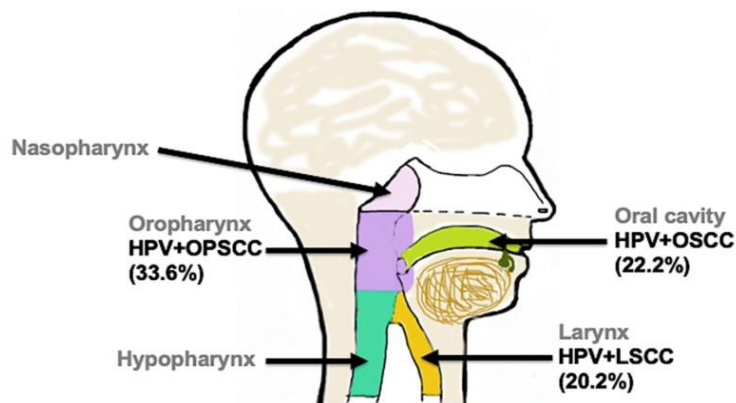


Figure 2. Distribution of human papillomavirus-associated head and neck cancers (HPV + HNC) between anatomical sites. HPV is associated with 33.6% of OPSCC (lavender), 22.2% of OSCC (bright green), and 20.2% of LSCC (gold) worldwide

Therefore, HPV in the head and neck is transmitted orally through oral sex, contributing to the majority of HPV transmission/infections associated with the head and neck.<sup>30,31</sup> While progress (in terms of treatment) has been made over the past few decades to improve overall survival for HPV+HNC patients, HPV+HNC screening and diagnosis has lagged behind cervical cancer. Future screening methods should focus on using HPV DNA as a marker in the diagnosis of HPV+HNC cases regardless of anatomical region; if HPV + OPSCC is suspected, p16INK4a expression levels should be assessed for protein in oropharyngeal cells, as well as seropositivity for E6/E7 antibodies in blood serum. E6 antibodies were detected in the blood serum, more than 10 years, before the diagnosis of HPV + OPSCC; seropositivity is a sensitive diagnostic tool for HPV + OPSCC.

Over the past decade, the number of cases of oropharyngeal cancer has increased at least four to

five times. The oropharynx includes the tonsils and the base of the tongue. The increase in these cancers is the result of HPV infection. Almost all of these cancers are caused by HPV16, a subtype of the HPV virus. Studies show that approximately 70 percent of oropharyngeal cancers are caused by HPV16. These cancers have the HPV16 virus found in the tumor. The number of HPV-positive cancers of the tonsils and the base of the tongue (cancer of the oropharynx) is growing rapidly. Several studies evaluating the prevalence of active oral HPV infection have shown that three to five percent of adolescents and five to 10 percent of adults have active HPV infection. More than 3% of adult men and 1% of adult women have HPV16 in their saliva at any given time. In contrast to active infection, it is estimated that 90% of adults have been exposed to HPV16 and 70% have signs of infection.<sup>32,33</sup>

In the literature, studies of sexually transmitted viruses in oral lesions have generally been limited to the search for HPV, so little is known about the presence and co-infection with other infectious agents such as *C. trachomatis* and *Neisseria gonorrhoeae*.<sup>34</sup>

The frequency of *Neisseria gonorrhoeae* (NG) and *C. trachomatis* in the oral cavity varies widely among published studies.<sup>35,36</sup> *Neisseria gonorrhoeae* (NG) and *Chlamydia trachomatis* (CT) are the two most common causes of sexually transmitted infections (STIs) in the oropharynx. These pathogens can be transmitted by orogenital contact.

Current results confirm that our knowledge of the diversity of infectious agents in the oral cavity is only partial. Indeed, *C. trachomatis* infection can alter the normal pattern of epithelial cell junctions, increasing susceptibility to HPV infection in both the genital mucosa and the oral cavity<sup>37</sup>.

Human Papillomavirus (HPV) and *Chlamydia trachomatis* (*C. trachomatis*) are the most frequent, viral and bacterial respectively, sexually transmitted infections (STIs) worldwide. Co-infection with *chlamydia trachomatis* is considered a possible cofactor that can lead from infection to oncogenesis. A positive association has been observed between *C. trachomatis* infection and cervical squamous cell carcinoma or its precursors in most epidemiological studies identifying HPV infection. Indeed, *C. trachomatis* infection can alter the normal pattern of epithelial cell junctions, increasing susceptibility to HPV infection in both the genital mucosa and the oral

cavity.<sup>38-39</sup> A possible biological explanation for the increased risk of coinfection is that *Chlamydia* causes local inflammation leading to damage to epithelial tissue, which in turn may become more susceptible to other infections. *Chlamydia trachomatis* infection: Possible cofactor for oropharyngeal cancer development.<sup>40</sup>

This study highlights the importance of diagnosing HPV and sexually transmitted pathogens such as *C. trachomatis*, which have been identified in many studies as possible cofactors of oncogenesis.<sup>41</sup>

Due to the increase in the practice of oral sex, researchers are urging scientists and clinicians to consider that when transmitted by the fecal-oral or genital-oral route, *Chlamydia trachomatis* (*C. trachomatis*) can colonize the gastrointestinal tract (GIT) and ultimately increase the risk of female infertility.

*Chlamydia*, one of the most common sexually transmitted diseases in the world, often goes unnoticed for many years because infected people often do not show symptoms. This increases the chance that infected people will not receive treatment to treat the infection; if left untreated, *chlamydia* can lead to urethritis, cervicitis, pelvic inflammatory disease, ectopic pregnancy and infertility. All members of the *Chlamydiaceae* have evolved primarily as commensals of the digestive tract of their host(s), with the fecal-oral route of transmission (FOT) as the main route of spread to new hosts. In communities where the PBF is reduced, the occurrence of *chlamydia* in the digestive tract is reduced. Oral *chlamydia* is a *chlamydia* infection that is found in the mouth or throat. *C. trachomatis*, a commensal microorganism of the human gastrointestinal tract, is an opportunistic pathogen in the genital and respiratory tracts, as well as on the conjunctiva. In conditions of reduced FOT, direct contact is the main mode of transmission. *C. trachomatis* is effectively transmitted into the gastrointestinal tract of new hosts through oral sex. The growing practice of oral sex is contributing to an increase in the prevalence of *C. trachomatis* in the human gastrointestinal tract in communities where FOT has previously been reduced.

The frequency of *C. trachomatis* in the oral cavity varies widely in published studies. This variability can be explained by the diversity of biological samples, the lack of global standardization methods, and the diversity of study populations.<sup>42,43</sup>

Although HPV-associated tumor information is clear, the prevalence of HPV and *C. trachomatis* oropharyngeal infection remains unclear.<sup>44,45</sup> Both organisms are important to public health because an existing chlamydial genital infection can increase the risk of contracting HPV and also contribute to the persistence of the virus, leading to complications such as cervical cancer.<sup>46</sup>

Indeed, *C. trachomatis* infection can alter the normal pattern of epithelial cell junctions, increasing susceptibility to HPV infection in both the genital mucosa and the oral cavity. A possible biological explanation for the increased risk of coinfection is that *Chlamydia* causes local inflammation leading to damage to epithelial tissue, which in turn may become more susceptible to other infections. The researchers urge other researchers and clinicians in the field to expand screening for *chlamydia* to include also sampling from rectal and pharyngeal sites when deemed appropriate to identify infection and patients receive treatment, thereby avoiding the potential long-term consequences of undiagnosed infection.<sup>47</sup>

In most cases, patients complain of symptoms of oral *chlamydia*, which include pain and tenderness in the mouth and throat.<sup>48</sup>

Oral *chlamydia* infections in the mouth or throat may cause the following symptoms: sore throat with a scratchy, dry feeling, mouth pain, redness in the throat or mouth with white spots, similar to strep throat, painless mouth sores, lesions around the mouth that look like cold sores, tonsillitis, redness with white spots resembling strep throat. However, in rare cases, patients may also experience chlamydial bumps on the tongue.

Gonococcal infection of the pharynx is usually transmitted through oral sex. Oropharyngeal gonorrhea is known to be rare because saliva is a hostile environment for *N. gonorrhoeae*. The disease can be transmitted through oral sex and kissing even in an asymptomatic infected person. Oropharyngeal infections with *Neisseria gonorrhoeae* or *Chlamydia trachomatis* (Serovar D-K) can cause pharyngitis and tonsillitis with sore throat, but in most cases are completely asymptomatic.<sup>49-51</sup>

Infection with gonorrhea in the mouth and throat occurs more often through oral-sexual contact than through oral-vaginal contact. Oral gonorrhea is often asymptomatic, but persistent sore throat is the most predominant symptom. Other possible signs include

acute ulceration, diffuse erythema of the oropharynx, swelling of tissues that bleed easily, the tonsils are invariably enlarged and infected, covering a whitish-yellow exudate and flu-like symptoms. Untreated oral gonorrhea can lead to disseminated gonococcal infection, causing fever, chills, skin sores, inflammation, and joint pain.<sup>52,53</sup>

Laboratory tests directly detect the gonococcal pathogen in urogenital, anorectal, or oropharyngeal swabs and should be considered in patients with symptoms and a history suggestive of gonorrhea. Nucleic acid amplification tests (NAATs) can detect *N. gonorrhoeae* in the genitals or extragenital specimens such as the pharynx. The development of multiplex NAATs now allows simultaneous screening of extensive sexually transmitted diseases.

Genital candidiasis can also be transmitted to the mouth. Depending on the transferred pathogen, ulcerative, inflammatory or papillomatous lesions of the lips, tongue, mucous membranes and pharynx occur. Asymptomatic infections are an important but often overlooked source of new infections. Systemic treatment for oral STIs is usually the same as for anogenital infections. May be accompanied by symptomatic local therapy. For infections of the tonsils and other hard-to-reach tissues, higher doses and an antibiotic with good tissue penetration are recommended.

Therefore, HPV in the head and neck is transmitted orally through oral sex, contributing to the majority of

HPV transmission/infections associated with the head and neck.<sup>54-59</sup>

While progress (in terms of treatment) has been made over the past few decades to improve overall survival for HPV+HNC patients, HPV+HNC screening and diagnosis has lagged behind cervical cancer. Future screening methods should focus on using HPV DNA as a marker in diagnosing HPV+HNC cases regardless of anatomical region

We believe that our review allows us to draw the following conclusions. The orogenital route of transmission has been shown to be the most documented route of oral HPV infection.

To successfully control these infections, programs will need to use strategies such as frequent testing of the oropharyngeal reservoir in addition to promoting condom use. Moreover, it is important for the attending physician to be aware of these manifestations in order to make an early diagnosis and begin adequate treatment. Oral examination should be an integral part of the evaluation of any patient with suspected STI.

### Declaration of Competing Interest

The author declare that they have no known competing financial interests or personal relationships that, could have appeared to influence the work reported in this paper.

### Funding

The work was not funded.

## REFERENCES

1. Bruce AJ, Rogers RS 3rd. Oral manifestations of sexually transmitted diseases. *Clin Dermatol*. 2004;22(6):520-7. doi: 10.1016/j.clindermatol.2004.07.005
2. Ljubojević S, Skerlev M, Alajbeg I. Manifestacije spolno prenosivih bolesti na oralnoj sluznici [Manifestations of sexually transmitted diseases on oral mucous membranes]. *Acta Med Croatica*. 2013;67(5):439-46. PMID: 24979885
3. Casey E. Copen, Anjani Chandra, Isaedmarie Febo-Vazquez Sexual Behavior, Sexual Attraction, and Sexual Orientation Among Adults Aged 18–44 in the United States: Data From the 2011–2013. National Survey of Family Growth. National Health Statistics Reports Number 88 v January 7, 2016 <https://www.cdc.gov/nchs/data/nhsr/nhsr088.pdf>
4. Li H, Torabi SJ, Yarbrough WG, Mehra S, Osborn HA, Judson B. Association of human papillomavirus status at head and neck carcinoma subsites with overall survival. *JAMA Otolaryngol Head Neck Surg*. 2018;144(6):519-525

5. Koutsky L. Epidemiology of genital human papillomavirus infection. *Am J Med.* 1997;102(5A):3-8.
6. Wong MCS, Vlantis AC, Liang M, et al. Persistence and clearance of oral human papillomavirus infections: a prospective population-based cohort study. *J Med Virol.* 2020. doi: 10.1002/jmv.26130
7. Furniss CS, McClean MD, Smith JF, Bryan J, Nelson HH, Peters ES, Posner MR, Clark JR, Eisen EA, Kelsey KT. Human papillomavirus 16 and head and neck squamous cell carcinoma. *Int J Cancer.* 2007;120(11):2386-2392. doi: 10.1002/ijc.22633.
8. Tumban E. A Current Update on Human Papillomavirus-Associated Head and Neck Cancers. *Viruses.* 2019;11(10):922. doi: 10.3390/v11100922
9. Schwartz SM, Daling JR, Doody DR, et al. Oral cancer risk in relation to sexual history and evidence of human papillomavirus infection. *J Natl Cancer Inst.* 1998;90(21):1626-36. doi: 10.1093/jnci/90.21.1626
10. Smith EM, Ritchie JM, Summersgill KF, et al. Age, sexual behavior and human papillomavirus infection in oral cavity and oropharyngeal cancers. *Int J Cancer.* 2004;108(5):766-72. doi: 10.1002/ijc.11633
11. Monti E, Barbara G, Libutti G, et al. A clinician's dilemma: what should be communicated to women with oncogenic genital HPV and their partners regarding the risk of oral viral transmission? *BMC Women's Health.* 2022;22:379 doi: /10.1186/s12905-022-01965-x
12. Gravitt PE. Unraveling the Epidemiology of Oral Human Papillomavirus Infection. *Ann Intern Med.* 2017;167(10):748-749. doi: 10.7326/M17-2628
13. Bray F, Ferlay J, Soerjomataram I, Siegel RL, Torre LA, Jemal A. Global cancer statistics 2018: GLOBOCAN estimates of incidence and mortality worldwide for 36 cancers in 185 countries. *CA Cancer J Clin.* 2018;68(6):394-424. doi: 10.3322/caac.21492
14. Macmillan Types of head and neck cancer. [(accessed on 30 September 2018)]; Available online: <http://www.macmillan.org.uk/information-and-support/head-and-neck-cancers/understanding-cancer/types-head-neck-cancer.html>
15. NCI Head and Neck Cancers. [(accessed on 3 December 2017)]; Available online: <https://www.cancer.gov/types/head-and-neck/head-neck-fact-sheet>
16. Hashibe M, et al. Interaction between tobacco and alcohol use and the risk of head and neck cancer: pooled analysis in the International Head and Neck Cancer Epidemiology Consortium. *Cancer Epidemiol Biomarkers Prev.* 2009;18(2):541-50. doi: 10.1158/1055-9965.EPI-08-0347
17. Kawakita D, Matsuo K. Alcohol and head and neck cancer. *Cancer Metastasis Rev.* 2017;36(3):425-434. doi: 10.1007/s10555-017-9690-0
18. Malhotra J, Borron C, Freedman ND, et al. Association between Cigar or Pipe Smoking and Cancer Risk in Men: A Pooled Analysis of Five Cohort Studies. *Cancer Prev Res (Phila).* 2017;10(12):704-709. doi: 10.1158/1940-6207.CAPR-17-0084
19. Ndiaye C, Mena M, Alemany L, et al. HPV DNA, E6/E7 mRNA, and p16INK4a detection in head and neck cancers: a systematic review and meta-analysis. *Lancet Oncol.* 2014;15(12):1319-31. doi: 10.1016/S1470-2045(14)70471-1
20. de Martel C, Plummer M, Vignat J, Franceschi S. Worldwide burden of cancer attributable to HPV by site, country and HPV type. *Int J Cancer.* 2017;141(4):664-670. doi: 10.1002/ijc.30716
21. Zhai L, Tumban E. Gardasil-9: A global survey of projected efficacy. *Antiviral Res.* 2016;130:101-109. doi: 10.1016/j.antiviral.2016.03.016
22. D'Souza G, Wentz A, Kluz N, et al. Sex Differences in Risk Factors and Natural History of Oral Human Papillomavirus Infection. *J Infect Dis.* 2016;213(12):1893-1896. doi: 10.1093/infdis/jiw063

23. D'Souza G, Agrawal Y, Halpern J, Bodison S, Gillison ML. Oral sexual behaviors associated with prevalent oral human papillomavirus infection. *J Infect Dis.* 2009;199(9):1263-9. doi: 10.1086/597755
24. Chaturvedi AK, Graubard BI, Broutian T, et al. NHANES 2009-2012 Findings: Association of Sexual Behaviors with Higher Prevalence of Oral Oncogenic Human Papillomavirus Infections in U.S. Men. *Cancer Res.* 2015;75(12):2468-77. doi: 10.1158/0008-5472.CAN-14-2843
25. Schnelle C, Whiteman DC, Porceddu SV, Panizza BJ, Antonsson A. Past sexual behaviors and risks of oropharyngeal squamous cell carcinoma: a case-case comparison. *Int J Cancer.* 2017;140(5):1027-1034. doi: 10.1002/ijc.30519
26. Fu TC, Hughes JP, Feng Q, et al. Epidemiology of Human Papillomavirus Detected in the Oral Cavity and Fingernails of Mid-Adult Women. *Sex Transm Dis.* 2015;42(12):677-85. doi: 10.1097/OLQ.0000000000000362
27. Houlihan CF, Baisley K, Bravo IG, et al. Human papillomavirus DNA detected in fingertip, oral and bathroom samples from unvaccinated adolescent girls in Tanzania. *Sex Transm Infect.* 2019;95(5):374-379. doi: 10.1136/sextrans-2018-053756
28. Palve V, Bagwan J, Krishnan NM, et al. Detection of High-Risk Human Papillomavirus in Oral Cavity Squamous Cell Carcinoma Using Multiple Analytes and Their Role in Patient Survival. *J Glob Oncol.* 2018;4:1-33. doi: 10.1200/JGO.18.00058
29. Tumban E. A Current Update on Human Papillomavirus-Associated Head and Neck Cancers. *Viruses.* 2019;11(10):922. doi: 10.3390/v11100922
30. Wierzbicka M, San Giorgi MRM, Frederik GD. Transmission and clearance of human papillomavirus infection in the oral cavity and its role in oropharyngeal carcinoma. A review *Mediacal Virology.* 2022;33(1):2337. doi: 10.1002/rmv.2337
31. Koskimaa HM, Waterboer T, Pawlita M, Grénman S, Syrjänen K, Syrjänen S. Human papillomavirus genotypes present in the oral mucosa of newborns and their concordance with maternal cervical human papillomavirus genotypes. *J Pediatr.* 2012;160(5):837-43. doi: 10.1016/j.jpeds.2011.10.027
32. Yrjänä S. Human papillomavirus infections and oral tumors. *Med Microbiol Immunol.* 2003;192:123-128. doi: 10.1007/s00430-002-0173-7
33. Szostek S, Zawilińska B, Biernat-Sudolska M, et al. Differences in the expression of human papillomavirus type 16 (HPV-16) E6 oncogene mRNA in SiHa cell line inoculated with CMV, HSV or Ureaplasmas. *Folia Biol.* 2014;62:73-78. doi: 10.3409/fb62\_1.73
34. Matsumoto M, Hamasuna R, Le PT, Fujimoto N, Matsumoto T. Detection of Neisseria gonorrhoeae or Chlamydia trachomatis from oral wash specimens using the Abbott RealTime CT/NG assay and the Cobas 4800 CT/NG assay: A prospective study. *Journal of Infection and Chemotherapy.* 2022;28(4):480-485. doi: 10.1016/j.jiac.2021.12.006
35. Madeleine M, Antilla T, Schwartz S, et al. Risk of cervical cancer associated with chlamydia trachomatis antibodies by histology, HPV type and HPV cofactors. *Int J Cancer.* 2006;120:650-655. doi: 10.1002/ijc.22325
36. Zhu H, Shen Z, Luo H, et al. Chlamydia trachomatis infection- associated risk of cervical cancer: A meta- analysis. *Medicine (Baltimore).* 2016;95:e3077. doi: 10.1097/MD.00000000000003077
37. Nonato D, Alves R, Ribeiro A, et al. Prevalence and factors associated with coinfection of human papillomavirus and Chlamydia trachomatis in adolescents and young women. *Am J Obstet Gynecol.* 2016;215:e1-e753. doi: 10.1016/j.ajog.2016.07.003
38. Vriend H, Boggards J, Van Bergen J, et al. Incidence and persistence of carcinogenic genital human papillomavirus infections in young woman

- with or without Chlamydia trachomatis co-infection. *Cancer Med.* 2015;4:1589–1598. doi: 10.1002/cam4.496
39. Samoff E, Koumans EH, Markowitz LE et al. Association of Chlamydia trachomatis with persistence of high-risk types of human papillomavirus in a cohort of female adolescents. *Amer J Epidemiol.* 2005;162:668–675. doi: 10.1093/aje/kwi262
40. Jenkins D, LeVault K, Sutcliffe S. Chlamydia trachomatis infection: Possible cofactor for oropharyngeal cancer development? *Oral Oncology.* 2015;51(2):e8-e9. doi: 10.1016/j.oraloncology.2014.11.015
41. Mosmann JP, Zayas S, Kiguen AX, et al. Human papillomavirus and Chlamydia trachomatis in oral and genital mucosa of women with normal and abnormal cervical cytology. *BMC Infect Dis.* 2021;21:422. doi: 10.1186/s12879-021-06118-3
42. Hamasuna R, Hoshina S, Imai H, Jensen JS, Osada Y. Usefulness of oral wash specimens for detecting Chlamydia trachomatis from high-risk groups in Japan. *Int J Urol.* 2007;14(5):473-475. doi: 10.1111/j.1442-2042.2006.01733.x
43. van Rooijen MS, van der Loeff MF, Morré SA, van Dam AP, Speksnijder AG, de Vries HJ. Spontaneous pharyngeal Chlamydia trachomatis RNA clearance. A cross-sectional study followed by a cohort study of untreated STI clinic patients in Amsterdam, The Netherlands. *Sex Transm Infect.* 2015;91(3):157-64. doi: 10.1136/sextrans-2014-051633
44. Eggersmann TK, Sharaf K, Baumeister P, et al. Prevalence of oral HPV infection in cervical HPV positive women and their sexual partners. *Arch Gynecol Obstet.* 2019;299(6):1659-1665. doi: 10.1007/s00404-019-05135-7
45. Cossellu G, Fedele L, Badaoui B, et al. Prevalence and concordance of oral and genital HPV in women positive for cervical HPV infection and in their sexual stable partners: *An Italian screening study.* *PLoS One.* 2018;13(10):e0205574. doi: 10.1371/journal.pone.0205574
46. Di Pietro M, Filardo S, Porpora MG, Recine N, Latino MA, Sessa R. HPV/Chlamydia trachomatis co-infection: metagenomic analysis of cervical microbiota in asymptomatic women. *New Microbiol.* 2018;41(1):34-41. PMID: 29313867
47. Mosmann JP, Talavera AD, Criscuolo MI, et al. Sexually transmitted infections in oral cavity lesions: Human papillomavirus, Chlamydia trachomatis, and Herpes simplex virus. *J Oral Microbiol.* 2019;11(1):1632129. doi: 10.1080/20002297.2019.1632129
48. Patrik M Bavoil, Patricia X Marques, Rebecca Brotman, Jacques Ravel Does Active Oral Sex Contribute to Female Infertility? *The Journal of Infectious Diseases.* 2017;216(8),932–935. doi: 10.1093/infdis/jix419
49. Javanbakht M, Westmoreland D, Gorbach P, Factors Associated with Pharyngeal Gonorrhea in Young People: Implications for Prevention. Sexually transmitted diseases. 2018
50. van Overbeek JJ. Gonorrhoeal infections in the oropharynx. *Arch Otolaryngol.* 1976;102(2):94-6. doi: 10.1001/archotol.1976.00780070072008
51. Chue PW. Gonorrhoea--its natural history, oral manifestations, diagnosis, treatment, and prevention. *J Am Dent Assoc.* 1975;90(6):1297-1301. doi: 10.14219/jada.archive
52. Balmelli C, Günthard HF. Gonococcal tonsillar infection-a case report and literature review. *Infection.* 2003;31(5):362-5. doi: 10.1007/s15010-003-4003-7
53. Wiesner PJ, Tronca E, Bonin P, et al. Clinical spectrum of pharyngeal gonococcal infection. *N Engl J Med.* 1973;288:181. doi: 10.1056/NEJM197301252880404
54. Schöfer H. Sexually transmitted infections of the oral cavity. *Hautarzt.* 2012;63(9):710-715. doi: 10.1007/s00105-012-2352-9
55. Eggersmann TK, Sharaf K, Baumeister P. et al. Prevalence of oral HPV infection in cervical HPV positive women and their sexual partners. *Arch Gynecol Obstet.* 2019;299:1659–1665. doi: 10.1007/s00404-019-05135-7

56. Chaturvedi AK, Engels EA, Pfeiffer RM, et al. Human Papillomavirus and Rising Oropharyngeal Cancer Incidence in the United States. *Journal of clinical oncology*. 2011;29(32): 4294-4301. doi: 10.1200/JCO.2011.36.4596
57. Saini R, Saini S, Sharma S. Oral sex, oral health and orogenital infections. *J Glob Infect Dis*. 2010;2(1):57-62. doi: 10.4103/0974-777X.59252
58. Agalliu I, Gapstur S, Chen Z, et al. Associations of oral alpha-, beta-, and gamma-human papillomavirus types with risk of incident head and neck cancer. *JAMA Oncol*. 2016;2(5):599-606. doi: 10.1001/jamaoncol.2015.5504

**ՍԵՌԱԿԱՆ ՃԱՆԱԳԱՐՀՈՎ ՓՈԽԱՆՅՎՈՂ ՀԻՎԱՆԴՈՒԹՅՈՒՆՆԵՐԻ ԴՐՍԵՈՐՎՐՈՒՄՆԵՐԸ ԲԵՐԱՆԻ ԽՈՌՈՉՈՒՄ**

Օֆելյա Զոչարյան <sup>1</sup>

<sup>1</sup> Մանկաբարձ-գինեկոլոգ, Բժշկական կենտրոն, Lahta clinic, Սանկտ Պրեբուրգ, ՌԴ

**Ամփոփում**

Սեռական ճանապարհով փոխանցվող հիվանդությունները բերանի խոռոչում փոխանցվում են սեռական հարաբերությունների ժամանակ: Այս հոդվածը քննարկում է բերանի խոռոչում սեռական ճանապարհով փոխանցվող մի քանի վիրուսների համապատասխան կլինիկական դրսևորումները, ներառյալ մարդու պապիլոմավիրուսը, Chlamydia trachomatis, Gonorrhoea: Այդ վարակների դրսևորումները բերանի խոռոչում ներառում են շրթուքների, լեզվի, լորձաթաղանթների և կոկորդի խոցային, բորբոքային կամ պապիլոմատոզ ախտահարումներ, նաև կարող են արտահայտվել առաջանում են բերան -ըմպանային շրջանի քաղցկեղով: Գրականության վերլուծության այս ակնարկում օգտագործվել է Google Scholar, PubMed, Scopus, Web of Science տվյալների բազաները:

**ПРОЯВЛЕНИЯ ИНФЕКЦИИ ПЕРЕДАЮЩИЕСЯ ПОЛОВИМ ПУТЕМ В РОТОВОЙ ПОЛОСТИ**

Офелия Кочарян <sup>1</sup>

<sup>1</sup> Врач акушер-гинеколог, Медицинский центр, Lahta clinic, г.Санкт Пребург, РФ

**Резюме**

Заболевания, передающиеся половым путем, передаются в ротовой полости во время полового акта. В этой статье обсуждаются соответствующие клинические проявления нескольких вирусов, передающихся половым путем, включая вирус папилломы человека, Chlamydia trachomatis и гонорею. Проявления этих инфекций в полости рта включают язвенные, воспалительные или папилломатозные поражения губ, языка, слизистых оболочек и горла, а также могут проявляться раком ротоглотки. В обзоре литературы использовались базы данных Google Scholar, PubMed, Scopus, Web of Science.