

DOI: 10.58240/1829006X-2023.19.2-163



## RESEARCH ARTICLE

## METHOD OF FACIAL SKIN REJUVENATION USING ELECTROSTIMULATION

Tsovinar Hambartsoumian,<sup>1\*</sup> Karyna Shoman,<sup>2</sup> Krasnopeevea Ekaterina<sup>2</sup><sup>1</sup> Doctor at MC Kanaker-Zeytun, State Medical University after M. Heratsi, Armenia<sup>2</sup> Doctor at Polyclinic 67. Moscow, RF

*\*Corresponding Author: Tsovinar Hambartsoumian; Doctor at MC Kanaker-Zeytun, State Medical University after M. Heratsi, Armenia;  
e-mail: [kayaran@aol.com](mailto:kayaran@aol.com)*

**Received:** Feb. 26, 2023; **Accepted:** Mar. 27, 2023; **Published:** Apr. 15, 2023

## Abstract

**Objectives:** Purpose of the study evaluation of the cosmetic effect using patches by the company “Aganyan” for facial rejuvenation.

**Materials and Methods:** The study was carried out in 106 participants with presence of perioral wrinkles of the skin. Participants applied four patches (2 copper and 2 zinc) on the face in the area of wrinkles crosswise according to the instructions. The patches were applied for eight hours every third day for three months. Perioral wrinkles were assessed by comparing photographs at the beginning and at the end of the study for each individual case. The efficacy was assessed according to the International Global Aesthetic Improvement Scale (GAIS). Visual confirmation of clinical improvement was also obtained by Life Viz 3D camera pictures.

**Results:** After analyzing the photographs taken before and after using the patch and a personal conversation with each participant, the following data were obtained from participants:

- a decrease in puffiness and dark circles under the eyes was noted: 6 out of 15 men, 34 out of 91 women;
- smoothing of small mimic wrinkles was noted: 24 women out of 106 people;
- lifting of the face oval was noted: 14 women out of 106 people.

Evaluation of the effectiveness of the GAIS procedure on M03 and M05, 2/3 of patients had significant improvement as assessed by physician and participants according to GAIS. Most of the patients also showed significant improvement at visit M12. After analyzing the photographs taken before and after the experiment, and a personal conversation with each patient of the cosmetology profile, the following results were obtained: in 38% of patients, puffiness and dark circles under the eyes decreased, in 23% of participants fine facial wrinkles were smoothed, in 12% of participants the oval of the face was tightened. Our results suggest that patches by the company “Aganyan” can serve as a novel therapy for controlled skin rejuvenation, effective wrinkles and folds.

**Conclusion:** The results of the studies provide a basis for concluding that the method of skin. The patches by the company “Aganyan” have proven its effectiveness through electrical stimulation with low intensity current in patients in different age groups, the study revealed a large number of positive cosmetic effects.

**Keywords:** Wrinkles; Skin rejuvenation; Novel method of electrostimulation

## Introduction

The aging process of the skin is complex and depends on many internal and external factors. Internal skin aging occurs over time and is influenced by genetic factors. The main clinical signs of skin aging include wrinkles and uneven pigmentation. The most common causes of wrinkles are age-related changes and ultraviolet radiation.<sup>1,2</sup>

## Wrinkles can be

**Static wrinkles:** These wrinkles are visible at all times and do not change in appearance with facial movements.

**Dynamic wrinkles:** These are expression lines that may appear as folds when the skin is not moving, and deepen with facial movements or expressions. Dynamic wrinkles appear when expressing emotions, such as fear, worry, joy, sadness, or surprise.<sup>3</sup> Cosmetologically manipulations can solve this problem. In modern aesthetic medicine, a variety of methods are used to rejuvenate the skin of the face.<sup>4-6</sup> Esthetic medicine differs from other medical care because it is not based on saving lives, but on improving the quality of life for the client. A person's autonomous decision is an indicator for esthetic treatments that will improve the client's self-image, self-esteem, and appearance to others. Medical estheticians work in accordance with strong, ethical considerations in every meeting with the client.

This includes reaching consensus in deciding which esthetic treatments to do. Over the past decade, there has been a growth in the popularity of both non-surgical and surgical cosmetic procedures. These include both medically indicated surgical techniques and more gentle procedures used to maintain skin tone. Even 10 years ago, plastic surgery methods were mainly used for skin rejuvenation and correction of age-related changes. Surgical methods were used mainly to change the shape and appearance of the face, and this is not a way to improve the internal condition of the skin, rather the opposite (since blood circulation in the affected areas is impaired).<sup>7,8</sup> Fear of surgery, use of anesthesia, long rehabilitation period, failure to achieve the desired results testify in favor of non-surgical methods.

Non-surgical methods are used can solve the following problems of age-related skin changes:

- smooth out wrinkles caused by muscles of expression (age related);
- significantly tighten the skin and correct the oval of the face;
- narrow the enlarged pores;
- enhance the natural production of anti-aging substances.

The methods of non-surgical facial rejuvenation are mainly aimed at renewing the surface layers of the skin, at improving the internal structure, i.e., to stimulate your own collagen.<sup>9,10</sup> Modern therapies use a variety non-surgical facial rejuvenation method, these procedures include laser rejuvenation, photo-rejuvenation, radio frequency, ultrasound, electro-optical synergy, thermage, ozone rejuvenation, chemical peels, microdermabrasion, injectable fillers, neurotoxins, platelet-rich plasma mesotherapy, botulinum therapy, etc. to rejuvenate the skin.<sup>11-14</sup> Among the popular methods of facial rejuvenation, mesotherapy should be noted.<sup>15-17</sup> This technique consists in injecting special preparations into the skin of the face: bioactive substances, preparations based on hyaluronic acid and fibroblasts- the key elements of the cell involved in the formation of collagen. These beneficial micro-injections contribute to effective facial rejuvenation. One of the most effective methods of facial rejuvenation is laser rejuvenation. The laser effectively penetrates the inner layers of the skin without damaging its outer layer. The technique of laser rejuvenation allows you to renew the cellular structure of the skin, make the skin smooth and elastic.<sup>18-20</sup> Ozone rejuvenation is a common method of facial rejuvenation.<sup>21</sup> Ozone stimulates the microcirculation of blood in the skin tissues, promotes the renewal of subcutaneous tissue, which leads to an improvement in complexion and provides a rejuvenating effect. Ozone is used in the form of injections into problem areas of the face and neck. Thermage is also a widely used facial rejuvenation method.<sup>22,23</sup> Under the influence of special radio frequency radiation, the temperature of the skin tissue rises, which leads to an increased production of collagen and elastane, which are responsible for the smoothness, firmness and elasticity of the skin. However, the physical and chemical methods of the listed methods of treatment have certain disadvantages. The main disadvantage of modern methods of

physical rejuvenation is that they deliver external energy to the entire mass of tissue, affecting both cells and the extracellular matrix; this changes the function and architecture of the tissue being treated. The main disadvantage of chemical rejuvenation methods is that, although they only target cells, they involve the delivery of external molecules that can trigger a tissue response outside the target. This uncontrolled subsequent reaction can lead to clinical complications such as burns, vascular deformity of the skin, tumors, keloids, hypertrophic scars, skin contraction, facial paralysis, necrosis, intravascular penetration, and infection. Among the non-invasive methods of skin rejuvenation, electrostimulation can be used to achieve numerous cosmetic effects, such as: regeneration, toning, skin rejuvenation, etc.<sup>24,25</sup> One of the most important innovations when it comes to aesthetics is the new medical advancements. The search for optimal and safe combinations, scientifically substantiated protocols for the correction of involuntal changes in the skin of the face is a current trend in dermatocosmetology. An example of a device with a similar effect is the patches by the company “Aganyan”, which will be discussed in our article. The uniqueness of this invention is that electrical stimulation can be used for long-term stimulation with low voltage and current without the use of wires and batteries. Here we report on a novel, non-invasive method of skin rejuvenation using electrostimulation plasters of "Aganyan" company.

**Purpose of the study** is evaluation of the cosmetic effect using the patches by the company “Aganyan” plaster for facial rejuvenation

**Materials and Methods**

This was an open, pilot study conducted on 106 volunteers under the control of dermatologists. All the volunteers signed a consent form containing the information relative to the nature and procedures of the study. This study was conducted according to the ethics of the “Helsinki declaration”.

Patients had a presence of peri-oral wrinkles of the facial skin.

*Table 1: Distribution of participants in the cosmetology profile*

Age (range)	M	F	Total
30-39	3 (20%)	45	48
		(49.5%)	(45.3%)
40-49	5	27	32
		(33.3%)	(29.7%)
50-59	7	19	26
		(46.7%)	(20.8%)
Total	15	91	106
		(100%)	(100%)

**Inclusion criteria:** healthy women; the patient's desire and ability to take part in the study; the presence of scales on skin over nano-labial lines, lower and upper lips, marionette lines that show wrinkles of mild and moderate degrees according to the Merz Aesthetics Scale (MAS in the validated 5-point, where 0=no wrinkles, 1=mild wrinkles, 2=moderate wrinkles, 3=severe wrinkles, and 4=very severe wrinkles) [26]. **Exclusion criteria:** The presence of somatic, endocrine, oncological, infectious and skin diseases, blood diseases, pregnancy, lactation, the presence of permanent filler in marionette lines, skin, peels, mesotherapy and surgery performed within 6 months prior to this study. Participants in front of a mirror independently assessed signs of aging on his face, comparing with the standard of the scale. The doctor, having his own subjective opinion of the clinical picture on a visual scale (during consultation and analysis of photographs) exhibited the degree of severity wrinkles and folds in points, depending on the study design: either their subjective assessment. Participants were informed of the purpose of the study and the use of any photographs obtained in which the patients could not be identified. All participants provided written consent to be included in this study and to use facial images for the purposes of the study. Each participant was given a set of patches by the company “Aganyan”, and a special brochure, in which the method of application was indicated in detail. Participants applied four patches (2 copper and 2 zinc) on the face in the area of wrinkles crosswise according to the instructions. The patches were applied for eight hours every third day for three months. The wearable patch includes a flexible substrate, a binder, an adhesive layer, with an electrode foil attached to it. Skin moisture is full of minerals, and is accepted as an

electrolyte medium. Zinc foil thickness 0.025mm and Copper foil thickness 0.025mm (Figure 1). The electrical stimulation is caused by applying at least two electrodes but preferably four, to the skin for better results to create interferential forelectrotherapy. Participants were warned that if any discomfort (redness, itching of the skin, etc.) occurs, they should immediately stop using the patch and inform the investigators. The participants tactilely and visually assessed the effects of the patch for three months. They recorded their observations in special brochures, which were later analyzed by researchers. All participants in the experiment were photographed before and after using the patch for visual assessment (Figure 2, 3). The electrostimulation therapy with patch like electrodes can be conveniently performed for long periods of time, ranging from about 1 hour to 10 hours or even more. Clinical assessment of treatment results (satisfaction by subject and investigator physician) was performed. The immediate results were assessed 1 month after the course, long-term results at the in 3 months of observation. Perioral wrinkles were assessed by comparing photographs at the beginning and at the end of the study for each case studied. The efficacy was assessed according to the International Global

Aesthetic Improvement Scale (GAIS Table 3) on the 1st (M01), 2nd (M02), 3rd (M3), 6th (M06) month of complex therapy. Visual confirmation of clinical improvement was also obtained by Life Viz 3D camera pictures.

### Results

After analyzing the photographs taken before and after using the patch (Figure 1-3) and a personal conversation with each patient, the following data were obtained in participants:

- A decrease in puffiness and dark circles under the eyes was noted on: 6 of 15 (men), and 34 of 91 (women);
- Smoothing of small mimic wrinkles was noted on: 24 of 106 people (all women);
- Lifting of the face oval was noted: on 14 of 106 people (all women).

Evaluation of the effectiveness of the GAIS procedure on M03 and M05, 2/3 of participants had significant improvement as assessed by physician and patient according to GAIS (Table 3). Most of the patients also showed significant improvement at visit M12 (Table 3).




Figure 1: The wearable patches by the company “Aganyan” includes a flexible substrate, a binder and an adhesive layer, with an electrode foil attached to it. Zinc foil thickness 0.025mm and Copper foil thickness 0.025mm

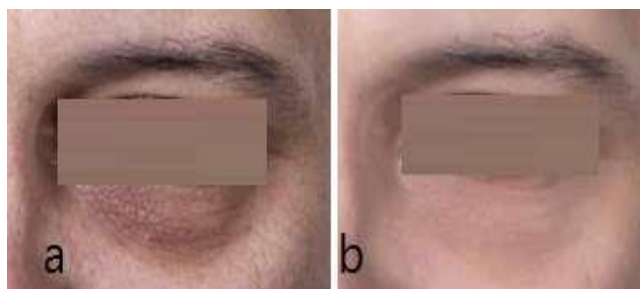


Figure 2. Patient at baseline (a) and (b) 12 weeks after skin rejuvenation using electrostimulation method under the eye's region

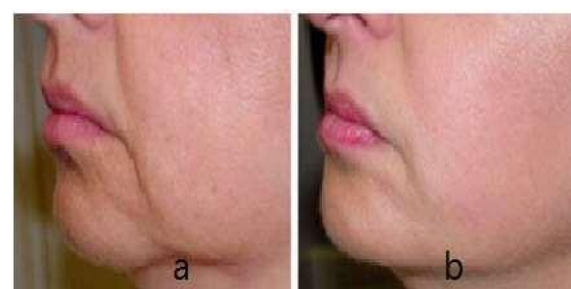

Figure 3. Patient at baseline (a) and 12 weeks after skin rejuvenation using electrostimulation method nasolabial and marionette region (b)

Table 2. Global Aesthetic Improvement Scale (GAIS) Degree Description

SCORE	TREATMENT RESULT
1	Exceptional improvement-excellent corrective result
2	Very improved-marked improvement of the appearance, but not completely optimal
3	Improved patient-improvement of the appearance, better compared with the initial condition, but a touch-up is advised
4	Unaltered patient-the appearance substantially remains the same compared with the original condition
5	Worsened patient-the appearance has worsened compared with the original condition

Table 3: GAIS indicators

Visit	Doctor	Participants
M01	2.6 ± 0.5	2.5 ± 0.51
M02	2.8 ± 0.46**	2.9 ± 0.31*
M03	2.7 ± 0.48**	2.5 ± 0.73
M06	1.8 ± 0.64*	1.7 ± 0.66*

**Note:** The value is statistically significantly different (p < 0.05): \* from that of the indicator at the M01 visit. After analyzing the photographs taken before and after the experiment, and a personal conversation with each patient of the cosmetology profile, the following results were obtained: in 38% of participants, puffiness and dark circles under the eyes decreased, in 23% of participants fine facial wrinkles were smoothed, in 12% of participants the oval of the face was tightened (figure 4). The "Aganyan" plaster has proven its effectiveness through electrical stimulation with low intensity current in participants indifferent age groups, the study revealed a large number of positive cosmetic effects.

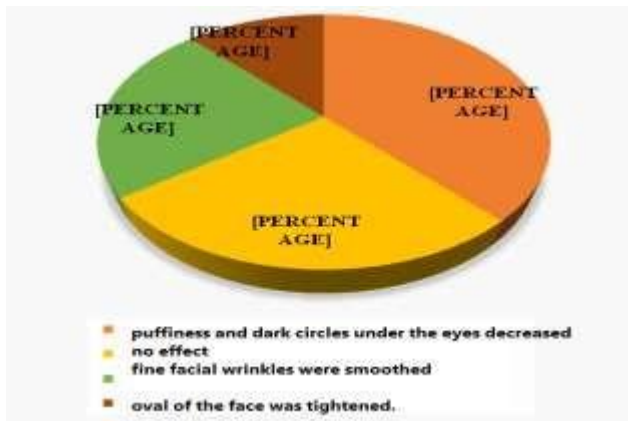


Figure 4. Effectiveness of the method of skin rejuvenation using electrostimulation method

**Discussion**

With age, the people have a deepening of the nasolabial fold, drooping of the corners of the mouth and loss of the border of the lips.<sup>27-29</sup> The appearance of perioral wrinkles often prompts patients to seek treatment.<sup>30,31</sup> The number of requests for cosmetic procedures with permanent or temporary fillers (as a method of reduction in the number and depth of wrinkles, and giving lips desired volume) is growing with varying results. However, the number of less serious complications is also increasing, even with the use of safe molecules such as hyaluronic acid.<sup>32,33</sup> According to statistics from the American Society for Aesthetic Plastic Surgery (ASAPS), dermal fillers (from English to fill; syn: dermal fillers) occupy a leading position among the most popular non-surgical aesthetic procedures.<sup>34</sup> One of the treatment options for these patients is soft tissue augmentation with skin fillers.<sup>35</sup> Skin fillers can provide the patient aesthetic result as these materials have the ability to reduce the appearance of wrinkles and give the face a more youthful appearance. Among non-surgical procedures according to statistics, fillers based on stabilized hyaluronic acid for the correction of involitional skin changes occupy a leading position.<sup>36</sup> For patients with early static lines and folds (≤ 2 degrees of contraction and ≤ 1 degrees at rest according to rating scales) for rejuvenation, physicians have the right tools in their hands to prevent or slow down skin aging. Injection procedures will be required to correct problems, and other methods, such as energy therapy, (electro-optical synergy), can be combined for optimal results. The effect of the skin bio-revitalization procedure is provided by an increase in the body's production of its own hyaluronic acid, which helps to normalize the water balance.<sup>37</sup> At the same time, all metabolic processes are improved, local blood flow is enhanced, which provides an increase in skin elasticity, a decrease in flabbiness, and an improvement in complexion. In the complex of non-invasive skin rejuvenation methods, the electrostimulation method is very popular.<sup>39</sup> Unlike contemporary physical methods that affect all tissue components, electrostimulation is an intervention at the cellular level, which precisely targets cell membranes through electroporation without affecting the extracellular matrix architecture. Unlike chemical interventions, electrostimulation is a non-invasive procedure that does not involve the application of external molecules.<sup>40</sup> This study presents results of using "Aganyan" plaster to address facial wrinkles and folds. The electrodes are made of different metals such as zinc and copper, and not connected to any electrical device such a voltage or current source. The difference in potentials causes electrons to flow on the surface of the skin from one of

the electrodes to another. In this sense, one of the electrodes can be considered as a cathode, while another electrode can be considered as an anode. The difference in potentials can be created only when the electrodes are of different metals. These ranges of voltages and electrical currents appear to be very safe for humans with no side effects whatsoever. At the cellular level, the electrostimulation therapy with patches stimulates an increase in adenosine triphosphate (ATP), the energy that fuels all biochemical functions in a human body. It also bumps up protein synthesis, which is necessary for tissue repair. When exposed to the "Aganyan" plaster, a low-intensity electric current is passed through the skin. Microcurrents activate protein synthesis (collagen and elastin), promote the renewal of epidermal cells, blood flow, lymph outflow, which increases the activity of metabolic and regeneration processes and, as a result, disappears puffiness and dark circles under the eyes. By increasing the tone of the muscles or, conversely, relaxing, if they were in a state of tension, the effect of smoothing out fine mimic wrinkles is achieved. Muscles trained after stimulation tighten the oval of the face, remove flabbiness and swelling of the skin, give the face a well-groomed and rejuvenated look. Our results show that low-intensity electric can improve skin function. The indisputable advantages of this invention are the absence of side effects on the human body.<sup>38</sup>

### Conclusion

Our results suggest that patches by the company "Aganyan" can serve as a novel therapy for controlled skin rejuvenation, effecting wrinkles and folds.

### Acknowledgements

Special acknowledgements AGANYAN, INC., USA for providing the patches by the company "Aganyan" and a special brochure, which describes in detail the method of using the patch.

### Special Acknowledgments

Silvia Aganyan, Dr. Vagharshak Pilossyan, Dr. Leon Kiraj, and Robert Avetisian.

### Conflict of interest and financial disclosure

The author declares that he has no conflict of interest and there was no external source of funding for the present study. None of the authors have any relevant financial relationship(s) with a commercial interest.

### Consent statement

Written informed consent was obtained from the patient for publication of this case report and accompanying images.

## REFERENCES

1. Panich U, Sittithumcharee G, Rathviboon N, et al. Ultraviolet Radiation-Induced Skin Aging: The Role of DNA Damage and Oxidative Stress in Epidermal Stem Cell Damage Mediated Skin Aging. *Hindawi Publishing Corporation Stem Cells International*. 2016;1-14. doi:10.1155/2016/7370642
2. Karen E. Burke Environmental aging of the skin: new insights. *Plast Aesthet Res*. 2020;7:59. doi:10.20517/2347-9264.2020.154
3. Garg S, Khan N, Makadia S. Proposed global drooping and wrinkles classification and scoring system for aging face with validation and experience on 54 Indian subjects. *Indian Journal of Dermatology, Venereology and Leprology*. 2018;84:672-677. doi:10.4103/ijdv1.ijdv1\_418\_17
4. Fab S, Pavicic T, Braz A. Combined aesthetic interventions for prevention of facial ageing, and restoration and beautification of face and body. 2017;10:423-429. doi: 10.2147/ccid.s144282
5. Samizadeh S, Belhaouari L. Effectiveness of growth factor induced the rapy for skin rejuvenation: A case series. *Journal Cosmetic dermatology*. 2020. doi: 10.1111/jocd.13750
6. Cantor J. Cosmetic dermatology and physicians' ethical obligations: More than just hope in a jar. *Seminars in Cutaneous Medicine and Surgery*. 2005;24:155-160. doi:10.1016/j.sder.2005.04.005
7. Ramirez OM. Rejuvenation of the Facial Expression: The Ultimate Paradigm Shift in Facial Surgery. Presented at the International Symposium. *All About Face*. 2019

8. Ramirez OM. Multidimensional evaluation and surgical approaches to neck rejuvenation. *Clin Plast Surg.* 2014;41:97-105. doi:10.1016/j.cps.2013.09.011
9. Stephanie EF, Mathew T, Epps Emily Brown, Julie Krochonis, Rena McConville, Mark A. Codner. A review of nonsurgical facial rejuvenation. *Plast Aesthet Res.* 2020;7:72. doi:10.20517/2347-9264.2020.152
10. Krochonis JB, McConville RL, Kosowski TR. Nonsurgical periorbital rejuvenation. In: Codner MA, McCord DC, editors. *Eyelid and periorbital surgery. 2nd ed. New York: Thieme.* 2017:483-510
11. Gary D. Monheit Nonsurgical facial rejuvenation. *Facial Plast Surg.* 2014;30:462-467. doi:10.1055/s-0034-1383560
12. IPao KY, Mancini R. Nonsurgical periocular rejuvenation: advanced cosmetic uses of neuromodulators and fillers. *Curr Opin Ophthalmol.* 2014;25:461-469. doi:10.1097/icu.0000000000000074
13. Jesse DM, Nikhil A, Daniel C, et al. Noninvasive Facial Rejuvenation. Part 3: Physician-Directed-Lasers, Chemical Peels, and Other Noninvasive Modalities *Semin Plast Surg.* 2016;30:143-150. doi:10.1055/s-0036-1584818
14. Jurado JR, Lima LF, Olivetti IP, et al. Innovations in minimally invasive facial treatments. *Facial Plast Surg.* 2013;29:154-160. doi:10.1055/s-0033-1347004
15. Domyati ME, El-Ammawi TS, Moawad O, et al. Efficacy of mesotherapy in facial rejuvenation: a histological and immunohistochemical evaluation. *Int J Dermatol.* 2012;51:913-919. doi:10.1111/j.1365-4632.2011.05184.x
16. Konda D, Thappa DM. Mesotherapy: What is new? *Indian J Dermatol Venereol Leprol.* 2013;79:127-134. doi:10.4103/0378-6323.104689
17. Hu L, Zhao K, Song WM. Effect of mesotherapy with nanochip in the treatment of facial rejuvenation. *Journal of Cosmetic and Laser Therapy.* 2020;22:2. doi:10.1080/14764172.2020.1740272
18. Yan D, Huang Z, Zhang A, Li S, Xiao X. Application effect of lattice laser in facial rejuvenation. *Medicine.* 2020;99(34):21814. doi:10.1097/md.00000000000021814
19. Lupton JR, Williams CM, Alster TS. Nonablative laser skin resurfacing using a1540 nm erbium glass laser: a clinical and histologic analysis. *Dermatol Surg.* 2020;28:833-835. doi:10.1046/j.1524-4725.2002.02091.x
20. Yuanyuan CAI, Changrui JING, Yongzhong LI. The efficacy and safety of fractional laser technology in facial rejuvenation. *J Tissue Eng Reconstr Surg.* 2018;14:277-279. doi:10.3969/j.issn.1673-0364.2018.05.012
21. Elvis AM, Ekta JS. Ozone therapy: A clinical review. *J Nat Sci Biol Med.* 2011;2:66-70. doi:10.4103/0976-9668.82319
22. Sean Sukal S, Geronemus RG. Thermage: the nonablative radiofrequency for rejuvenation *Clinics in Dermatology.* 2007;26:602. doi:10.1016/j.clindermatol
23. Bonjorno AR, Gomes TB, Pereira MC, et al. Radiofrequency therapy in esthetic dermatology: a review of clinical evidences. *J Cosmet Dermatol.* 2020;19:278-281. doi:10.1111/jocd.13206
24. Golberg A. Skin Rejuvenation with Non-Invasive Pulsed Electric Fields. *Sci Rep.* 2015;25:10187. doi: 10.1038/srep10187
25. Jauregui L, Knape WA, Ebbers E, et al. A dose-response study of nanosecond electric energy pulses on facial skin. *Journal of Cosmetic and Laser Therapy.* 2020;22:4-5. doi:10.1080/14764172.2020.1827151
26. Stella E, Di Petrillo A. Standard Evaluation of the Patient: The Merz Scale. *Injections in Aesthetic Medicine.* 2013;33-50 doi:10.1007/978-88-470-5361-8\_3
27. Kaur M, Garg RK, et al. Analysis of facial soft tissue changes with aging and their effects on

- facial morphology: A forensic perspective. *Egyptian Journal of Forensic Sciences*. 2015;2:46-56. doi:10.1016/j.ejfs.2014.07.006
28. Rhodes MG. Age estimation of faces: a review. *Appl Cogn Psychol*. 2009;23:1-12. doi:10.1002/acp.1442
29. Sadick N, Karcher C, Palmisano L. Cosmetic dermatology of the aging face. *Clin Dermatol*. 2009;27:3-12. doi:10.1016/j.clindermatol.2008.12.003
30. EL-Domyati M, Medhat W. Minimally Invasive Facial Rejuvenation. *Expert Rev. Dermatol*. 2013;8:565-580. doi:10.1586/17469872.2013.836845
31. Fabi S, Pavicic T, Braz A, et al. Combined aesthetic interventions for prevention of facial ageing, and restoration and beautification of face and body. *Clin Cosmet Investig Dermatol*. 2010;4:423-429. doi:10.2147/CCID.S144282
32. Rohrich RJ, Bartlett EL, Dayan E. Practical Approach and Safety of Hyaluronic Acid Fillers. *Plast Reconstr Surg Glob Open*. 2019;7:2172. doi:10.1097/gox.0000000000002172
33. Cox SE, Adigun CG. Complications of injectable fillers and neurotoxins. *Dermatol. Ther*. 2011;24:524-536. doi:10.1111/j.1529-8019.2012.01455.x
34. Tam T. Nguyen stic Surgery and Cosmetic Procedures: Facial Injection Procedures. *FP Essent*. 2020;497:11-17. <https://pubmed.ncbi.nlm.nih.gov/33021773/>
35. Newman J. Review of soft tissue augmentation in the face. *Clin Cosmet Investig Dermatol*. 2009;2:141-150. doi:10.2147/ccid.s3631
36. Rosset L. Mario Goisis Hyaluronic acid in calves' defects correction. *Plastic and Aesthetic Research*. 2014;1:62. doi:10.4103/2347-9264.139702
37. Gold MH. Use of hyaluronic acid fillers for the treatment of the aging face. *Clin Interv Aging*. 2007;2:369-376. doi:10.2147/cia.s1244
38. Pullar JM, et al. The Roles of Vitamin C in Skin Health *Nutrients*. 2017;9:866. doi:10.3390/nu9080866
39. Ilves M. Facial muscle activations by functional electrical stimulation. *Biomedical Signal Processing and Control*. 2019;48:248-254. doi:10.1016/j.bspc.2018.10.015
40. Mariappan N. Recent trends in Nanotechnology applications in surgical specialties and orthopedic surgery. *Biomed Pharmacol J*. 2019;12. doi:10.13005/bpj/1739

## ԴԵՄՔԻ ՄԱՇԿԻ ԵՐԻՏԱՍԱՐԴԱՅՄԱՆ ՄԵԹՈԴ ԷԼԵԿՏՐՈՍՏԻՄՈՒԼՅԱՑԻԱՅԻ ՄԻՋՈՑՈՎ

Ծովինար Համբարձումյան,<sup>1</sup> Կարինա Ծոման,<sup>2</sup> Կրասնոպենա Եկատերինա <sup>2</sup>

<sup>1</sup> Բժիշկ, Քանաքեռ-Զեյթուն ԲԿ, Երևան, Հայաստան

<sup>2</sup> Բժիշկ, Պոլիկլինիկ 67, Մոսկվա, ՌԴ

### Ամփոփում

**Նպատակը.** Դեմքի երիտասարդացման համար "Aganyan" կաշուկի օգտագործմամբ կոսմետիկ էֆեկտի արդյունավետության գնահատականը:

**Նյութեր և մեթոդներ.** Հետազոտությունն իրականացվել է մաշկի ծայրամասային կնճիռների առկայությամբ 106 մասնակիցների մոտ: Մասնակիցների մոտ ցուցումների համաձայն "Aganyan" կաշուկները խաչաձև փակցվել են դեմքի կնճիռների հատվածում (2 պղինձ և 2 ցինկ): Կաշուկները կիրառվել են ութ ժամ՝ յուրաքանչյուր երրորդ օրը, երեք ամսվա ընթացքում: Պերիորալ կնճիռները գնահատվել են համեմատելով լուսանկարները ուսումնասիրության սկզբում և վերջում յուրաքանչյուր առանձին դեպքի համար: Արդյունավետությունը գնահատվել է Էսթետիկ բարելավման միջազգային

սանդղակի (GAIS) համաձայն: Կլինիկական բարելավման տեսողական հաստատումը ստացվել է նաև Life Viz 3D տեսախցիկի նկարներով:

**Արդյունքներ.** Կապուկները օգտագործելուց առաջ և հետո արված լուսանկարները վերլուծելուց և յուրաքանչյուր մասնակցի հետ անձնական գրույցից հետո մասնակիցներից ստացվեցին հետևյալ տվյալները.

- նկատվել է այտուցների և աչքերի տակ մուգ շրջանակների նվազում՝ 15 տղամարդկանցից 6-ի մոտ, 91 կնոջից 34-ի մոտ;
- նշվել է մանր միմիկական կնճիռների հարթեցում՝ 106 մասնակիցներից- 24 կնոջ մոտ;
- նշվել է դեմքի օվալի բարձրացում՝ 106 մասնակիցներից-14 կնոջ մոտ:

Պրոցեդուրաների արդյունավետությունը գնահատելիս համաձայն GAIS-ի M03 և M05 հիվանդների 2/3-ի մոտ ցույց է տվել զգալի բարելավում, որը գնահատել են բժիշկը և մասնակիցները:

Մեծ մաս հիվանդների մոտ նույնպես զգալի բարելավումներ են ցույց տվել M12 այցելության ժամանակ: Վերցված լուսանկարները վերլուծելուց հետո փորձարկումից առաջ և հետո, և յուրաքանչյուր հիվանդի հետ անձնական գրույցից ստացվել են հետևյալ արդյունքները՝ հիվանդների 38%-ի մոտ այտուցվածությունը և աչքերի տակ մուգ շրջանակները նվազել են, մասնակիցների 23%-ի մոտ դեմքի նուրբ կնճիռները հարթվել են, մասնակիցների 12%-ի մոտ դեմքի օվալը ձգվել է: Մեր արդյունքները հուշում են, որ "Aganyan" կապուկը կարող է ծառայել որպես նոր թերապիայի մեթոդ մաշկի վերահսկվող երիտասարդացման, արդյունավետ է կնճիռների և ծալքերի համար:

**Եզրակացություն.** Ուսումնասիրությունների արդյունքները հիմք են տալիս եզրակացնելու, որ "Aganyan" կապուկի օգտագործմամբ դեմքի մաշկի երիտասարդացման մեթոդը ապացուցել է իր արդյունավետությունը ցածր ինտենսիվության հոսանքով էլեկտրական գրգռման միջոցով տարբեր տարիքային խմբերի հիվանդների մոտ, ուսումնասիրությունը մեծ թվով դրական կոսմետիկ ազդեցություն է հայտնաբերել:

## МЕТОД ОМОЛОЖЕНИЯ КОЖИ ЛИЦА С ПОМОЩЬЮ ЭЛЕКТРОСТИМУЛЯЦИИ

Цовинар Амбарцумян,<sup>1</sup> Карина Шоман,<sup>2</sup> Краснопеева Екатерина <sup>2</sup>

<sup>1</sup> Доктор. МЦ Канакер-Зейтун, Ереван, Армения

<sup>2</sup> Доктор, Поликлиника 67, Москва, РФ

### Абстракт

**Цель:** исследования оценка косметического эффекта при использовании пластыря «Аганьян» для омоложения лица.

**Материалы и методы:** Исследование проведено у 106 пациентов с наличием периоральных морщин кожи. Участники накладывали четыре пластыря (2 медных и 2 цинковых) на лицо в области морщин крест-накрест согласно инструкции. Пластыри накладывались на восемь часов каждый третий день в течение трех месяцев. Периоральные морщины оценивались путем сравнения фотографий в начале и в конце исследования для каждого отдельного случая. Эффективность оценивали по Международной шкале глобального эстетического улучшения (GAIS). Визуальное подтверждение клинического улучшения также было получено по снимкам с камеры Life Viz 3D.

**Результаты:** После анализа фотографий, сделанных до и после использования пластыря и личной беседы с каждым участником, от участников были получены следующие данные:

- отмечено уменьшение отечности и темных кругов под глазами: у 6 из 15 мужчин, у 34 из 91 женщины;
- отмечено разглаживание мелких мимических морщин: у 24 женщин из 106 пациентов;
- отмечена подтяжка овала лица: 14 женщин из 106 пациентов.

При оценке эффективности процедуры GAIS на M03 и M05 у 2/3 пациентов значительное улучшение по оценке врача и участников в соответствии с GAIS. Большинство из пациентов также продемонстрировали значительное улучшение при посещении M12. После анализа сделанных фотографий до и после

эксперимента и личная беседа с каждым пациентом косметологии профиля были получены следующие результаты: у 38% пациентов отечность и темные круги под глаза уменьшились, у 23% пациентов разгладились мелкие мимические морщины, у 12% пациентов овал лица подтянулся. Наши результаты показывают, что пластырь «Аганян» может служить новым методом терапии для контролируемого омоложения кожи, эффективных морщин и складок.

**Заключение:** Результаты исследований дают основание для вывода о том, что пластырь «Аганян» доказал свою эффективность при электростимуляции током низкой интенсивности у пациентов разных возрастных групп, при исследовании выявлено большое количество положительных косметических эффектов.