



REVIEW ARTICLE

PREVENTION AND MANAGEMENT OF INTRA-OPERATIVE COMPLICATIONS IN
MAXILLARY SINUS AUGMENTATION USING THE LATERAL APPROACH? A REVIEW

Pascal Valentini DDS *

University of Corsica Pasquale Paoli, Institute of Health, Dept of Implant Surgery, Tattone Hospital, 20250 Corte,
France

*Corresponding author: Pascal Valentini; Tattone Hospital, 20250 Corte, France;
e-mail: drpascalvalentini@gmail.com

Received: Feb. 25, 2023; Accepted: Mar. 28, 2023; Published: Apr. 15, 2023

Abstract

The lateral approach for maxillary sinus grafting has become a routine technique with an implant survival rate over 96% in the maxillary posterior region. However, this technique may be associated with some complications that may occur at different time points and influence short and long-term implant survival rate. This article is dedicated to intra operative complications which are mainly due to anatomical variations such as the shape of the sinus, the presence of septa and other particularities such as the intraosseous passage of the antral alveolar artery which may interfere with the position of the vestibular window.

In order to identify the risk and prevent the complications, a perfect knowledge of the anatomy is therefore essential. If a complication does occur, it must be treated in an efficient manner to prevent the postoperative complications that may follow, in the form of chronic or acute sinusitis. The prevalence of intra operative complications is conversely proportional to the surgeon's skill and experience without an influence on implant survival if they are properly managed.

Keywords: Bone graft, complications, management, maxillary sinus augmentation, prévention

Introduction

Maxillary sinus augmentation via the lateral approach technique, has been recognized for many years as a reliable, effective and well documented technique for bone augmentation in the posterior maxilla.^{1,2,3} This technique is reported to induce more complications being more invasive than the crestal approach.^{4,5}

In medicine, as in everyday life, each time a complication occurs, two questions must be asked: why did I get this complication, and how could I have avoided it? According to Pjetursson et al,⁶ there is a learning curve in implant dentistry, represented in higher survival rates and lower complication rates reported in more recent clinical studies. This is particularly true for maxillary sinus augmentation

using the lateral approach. Comparing studies from the early 2000s^{7,8} with those published 20 years^{9,10} later the 5y implant survival rate is 92% and 95% respectively. the purpose of this article is to identify, through the literature and the author's experience, the ways to achieve this by preventing and treating complications in the most predictable way.

Intra operative complications:

In order to prevent and to anticipate them a pre-operative CBCT is absolutely mandatory.^{11,12}

Neurosensory disturbance:

This complication is rarely mentioned. Sometimes after the surgery the patient can feel some numbness on the same side the graft has been performed. This is

due to the presence of terminal branches of the infra orbital nerve which are cut at the moment the anterior vertical releasing incision is made.¹³ The prevention of this complication consists of making a partial incision, instead a full thickness one, in the alveolar mucosa and spreading the edges with Metzenbaum scissors, which stretches the nerve fibers rather than cutting them (Figure 1).

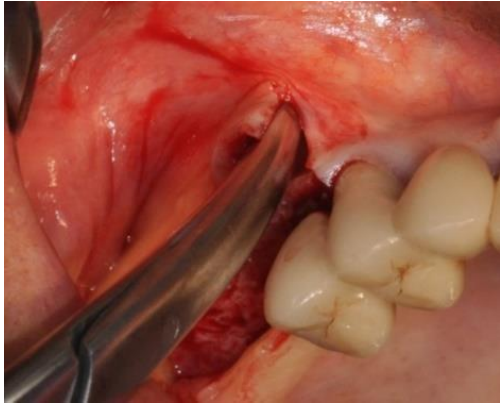


Figure 1. Metzenbaum scissors are inserted under the split thickness incision and opened to stretch the nerve branches without cutting them

Vascular damage

This complication is only observed if the lateral approach is used. A significant bleeding may complicate the procedure. It is due to a damage of the alveolar antral artery when making the vestibular osteotomy when its passage is intra osseous within the buccal wall. This artery is an anastomosis between the infraorbital artery and the postero-superior alveolar artery, its passage being extraosseous in 44% of cases.¹⁴ Its course can be very variable so it should be checked systematically on cross sectional cuts with pre op CBCT. The likelihood for an intraoperative bleeding with a vessel of 0.5-1mm in diameter will be 10% and 57% for a diameter of 1-2 mm.¹⁵ The higher risk corresponds with a diameter more than 2mm.¹⁶ Intra operative bleeding can be managed with various methods. By crushing the bleeding point with a hemostat,¹⁷ applying pressure with a gauze impregnated with tranexamic acid 13 or bone wax.¹⁷ The risk is the recurrence of bleeding post operatively.¹³ Electro coagulation with a bipolar device can also be employed with the risk of sinus membrane damage.

The absence of a suture at the distal releasing incision may favour the drainage of the clot.¹⁸

Avoiding bleeding remains the best approach. To do this, it will be necessary to proceed with the isolation of the alveolo antral artery using piezo surgery (Figure 2).^{13,19} Another option, if technically possible, is to make the window as small as possible and to move it lower.¹⁷

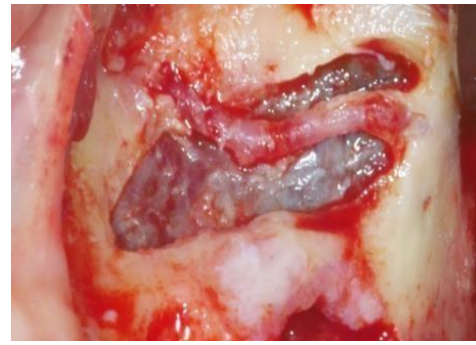

Figure 2. The alveolo antral artery has been isolated using piezo surgery

Membrane perforation:

It is the most common complication with a prevalence between 0 and 58% and an average of 19.5%.²⁰ This complication is not considered as a negative factor for bone formation and implant survival^{21,22} even contrary opinions on the quality of new-bone formation²³ and survival have been expressed.^{24,25}

Risk factors and prevention:

The prevention of this type of complication is essential and for that it is necessary to be able to detect the risk factors of tearing in the most comprehensive manner.²⁶

Considering the membrane thickness, there is a controversy. According to Aimetti et al²⁷ the sinus membrane in patients with a thick gingival phenotype is thicker. Lum et al²⁸ in their retrospective study, concluded that patients who experienced membrane perforation had a thinner membrane compared with patients without membrane perforation. But Insua et al,²⁹ after testing mechanically sinus membranes harvested from fresh cadavers, found that a thick membrane is not prevented to tear, as its resistance under elastic forces is not higher than a thinner one. Similarly, Lin et al³⁰ showed that membranes with a thickness of 1 to 1.5 mm were the most resistant while those that are thinner or thicker are more prone to tearing.

It is therefore impossible to appreciate the real thickness relying solely on radiographic examination, especially since it is over-evaluated on the CBCT.³¹ Another risk factor that must be considered is the presence of septa. In case of complex internal anatomy, a 3D reconstruction is essential³² to have an exact idea of the number of septa, their orientation, and their size.

The prevalence of perforation is less with medio lateral septa compared with antero-posterior²⁶ and an appropriate surgical approach must be implemented according to these criteria.³³ For instance, when the sinus is divided in 3 cavities because of the presence of 2 medio-lateral septa it is preferable to consider 3

different sinuses³⁴ to be grafted or by removing surgically the septa when it is antero-posterior.¹³ The width of the sinus cavity is also a risk factor.³⁵ This parameter is appreciated by measuring the angle between the buccal wall and the palatal component of the nasal wall. When this angle is acute the perforation rate is more than 60%³⁶ and it decreases moving in a more posterior direction, making the anterior region the most dangerous regarding the risk of perforation, especially in the presence of a particularly narrow anterior recess (Figure 3). Consequently, the window should be placed as close as possible to the anterior wall in order to dissect the membrane under direct vision, which will allow the detection and treatment of any tears.

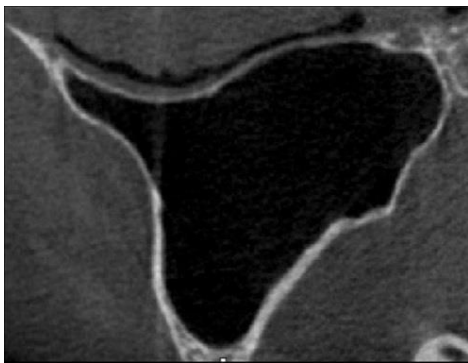


Figure 3. The anterior part of the sinus is very narrow (axial cut)

The thickness of the lateral wall is also mentioned as a risk factor.³⁷ If the buccal wall is thin, it is recommended to erode it until the membrane is visible in order to lift it.¹⁹ When the buccal wall is thick the lateral osteotomy by erosion using the piezo surgery would be time consuming and therefore it is recommended to cut the window and to lift it out. The risk of perforation being very high, in some cases, because of its strong adhesion to the bone. This degree of adhesion can't be detectable on the CBCT. To prevent this drawback, it is recommended to split the thick window in small pieces in order to detach each of them with a lower pulling force (Figure 4. a, b).¹³ Regarding the grafting technique, when the implants are placed simultaneously if the sinus is entirely filled with the grafting material, the risk is to tear the membrane apically while inserting the implants is very high by creating an increased pressure internally.

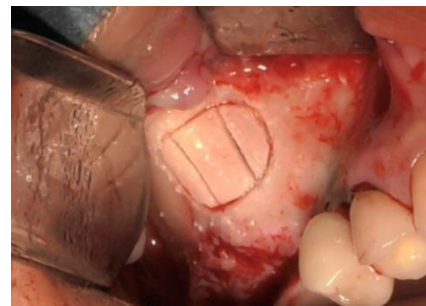


Figure 4a. The window is divided in 3 small pieces

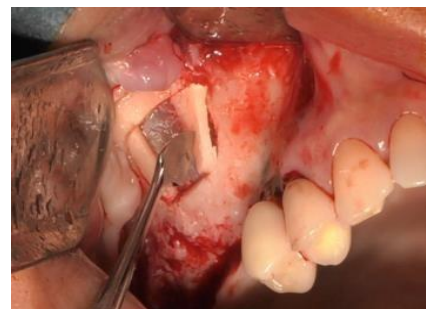

Figure 4b. All pieces are removed successively

To avoid this undetectable perforation, it is preferable to fill the sinus cavity two-thirds of the way and then place the implants before completing the graft. Smoking has been recently identified as a risk factor.³⁸

How to detect the perforation?

The Vaslava maneuver might have certain limitations,³⁹ thus, a more preferable approach would be to detect perforation and to manage it more efficiently by direct view. An alternative way is to inject saline into the sinus cavity and to ask the patient if he/she feels liquid flowing into the nose.

Management of perforations

According to Nolan et al,²⁴ the use of antibiotics to treat post-operative sinusitis and graft failure was higher in sinuses with perforation. This means that the size of the perforation must be as small as possible and that perfect hermeticity must be ensured to grafting material penetration in the sinus. Among the treatments reported, the most widely used technique in the studies reviewed was collagen membrane repair although this was managed in different ways.⁴⁰ Often the perforation occurs when the window is made and is tangent to the osteotomy line (Figure 5a), so that it is not completely visible. In this case, the shape of the window must be modified so that it can be seen in its entirety (Figure 5b). The next step is to initiate the detachment on the opposite side (Figure 5c) of the perforation to take advantage of the membrane's own elasticity, which will lead to a reduction of its size and to its partial closure (Figure 5d).

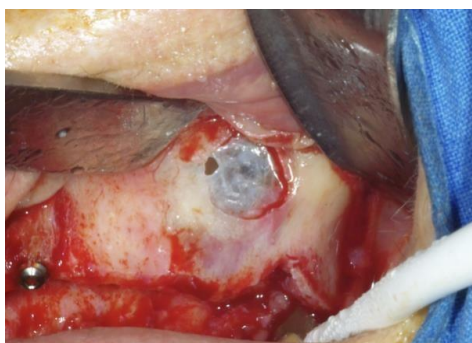


Figure 5a. The perforation is tangent to the osteotomy line

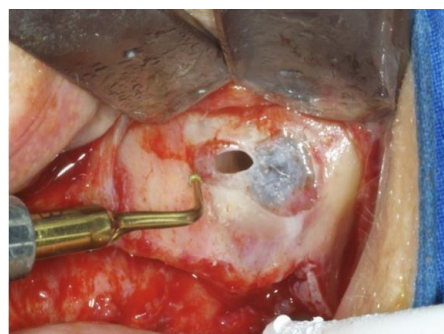


Figure 5b. The shape of the window is modified to see the perforation in its entirety

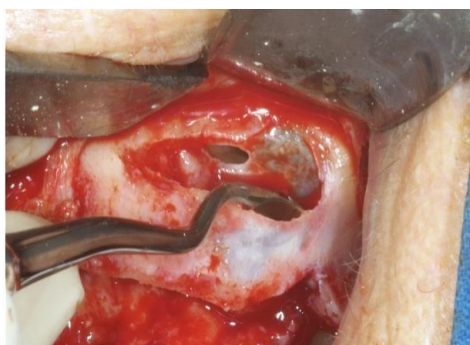

Figure 5c. The detachment is initiated opposite to the perforation

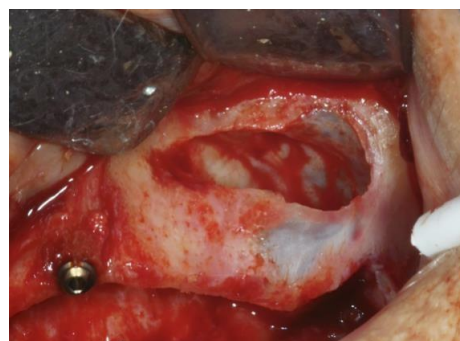

Figure 5d. The perforation size is reduced

Then, it will be necessary to seal it with a collagen membrane to ensure its hermeticity.⁴¹ But, despite the use of a collagen, membrane perforation and repair of the Schneiderian membrane can compromise new bone formation and implant survival rate.⁴² They explain this by saying that during the condensation of the graft the surgeon cannot know if the membrane resists the pressure or not. To prevent this, it is preferable to pack the grafting material always against a bony wall and not upwards or backwards because of the risk of an undetected perforation.

In the same way it was reported⁴³ a higher prevalence for sinusitis in cases of membrane perforation (31.4%) despite intraoperative closure with resorbable membranes. In this report, as the way in which the collagen membrane was used was not specified, it can be assumed that the stability of this membrane above the perforation was not ensured and that it shifted during the placement of the graft.⁴⁴ It is therefore necessary to ensure its stability at the time of grafting. For this purpose, the Pouch Technique has been advocated.⁴⁵

The disadvantage of this technique is that there may be a gap between the medial wall and the graft which may alter the quality of the newly formed bone. The way to prevent this could be the use of the Tattone Technique⁴⁶, which consists of stabilizing part of the collagen membrane with titanium pins on the medial

wall, allowing this type of perforation to be hermetically sealed (Figure 6. a, b).

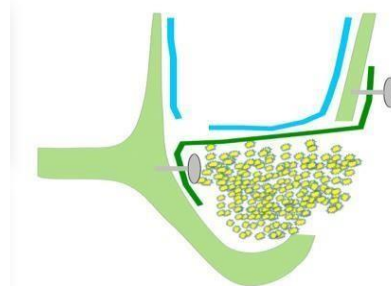


Figure 6a. The membrane is pinned in the medial wall and the buccal wall

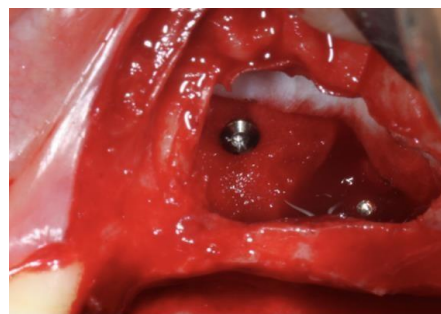


Figure 6b. Clinical view: the titanium tacks in the medial wall

This technique is particularly indicated in case of presence of a para-nasal recess of less than 30° which can result in a tear adjacent to the medial wall.^{24,47}

De Oliveira et al⁴⁸ assert that the resorbable membrane influences the intensity of inflammatory responses producing a reduction in bone formation. Another option is to use a resorbable suture⁴⁹ with the risk with of enlarging the perforation or PRF membranes.⁴⁷ This last possibility needs to be further documented.

According to other authors^{39,49} the implant failure rate increases as the perforation size. In only two studies^{50,51} the treatment of both small and large defects has been described. Small defects have been managed with resorbable collagen membrane in both studies.

Large defects with resorbable sutures and adsorbable membranes⁴⁹ with no differences for the implant failure, conversely to Hernandez-Alfaro et al⁵² who treated large defects with lamellar bone and a lower implant success compared to small defects.

The impact of membrane perforation on graft quality and implant survival remains controversial. Moreno Vazquez et al⁵³ and Sakkas et al⁵⁴ assert there is no impact of membrane perforation on the graft failure rate conversely to others.⁴² In a recent systematic review,⁴⁰ it was concluded that a negative impact on the bone graft itself or on remodeling processes could not have been shown. Another option to avoid the complications related to granules loss trough the perforation could be the use of PRF^{55,56} alone as grafting material or without any grafting material⁵⁷ with an implant survival of 100% and 98.7% respectively, but evidence is still lacking.

Delamination

At the time of the osteotomy or during its dissection, the schneiderian membrane may be partially damaged due to the tearing of its periosteal part (Figure 7). Although not perforated because the pseudostratified respiratory epithelium will remain, it will be very fragile. This type of lesion should be treated in the same way as a perforation.

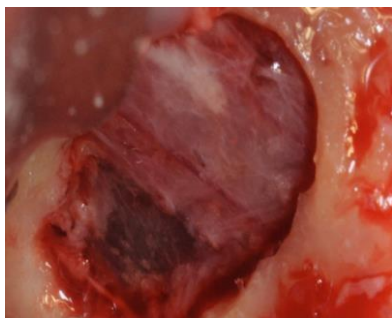


Figure 7. The delamination (dark area) in the lower left

For large perforations, a better option would be to abort the surgery and to insert a collagen sponge in the sinus cavity and to wait 3-6 weeks.⁵⁸ This time frame allows the membrane to heal, making the re-entry much easier using a split thickness approach.

Implant migration

When the implant placement is performed simultaneously to the graft it is necessary to achieve a perfect implant stability to prevent the implant from falling into the sinus and its migration in sensitive areas (Figure 8).⁵⁹ The implant can migrate for two reasons: If the sinus floor is not dense, the osseodensification technique can be used.⁶⁰

The second reason is when the bone height under the sinus is reduced and there is an indication to place implants at the same time as the graft, it will be necessary to undersize the drilling and to use a tapered implant which may cause a fracture of the vestibular wall when the implant is inserted using a high torque.

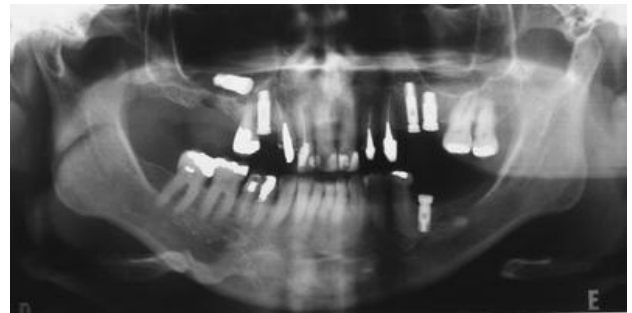


Figure 8. The Implant migration in the sinus

The solution is to shift the window apically 8-10 mm¹³.

Conclusion

In addition to the risk factors mentioned above the frequency of intra operative complications is also inversely proportional to the surgeon's skill and experience. They can be considered to have no influence on graft and implant postoperative survival, if they are properly managed thanks to a perfect knowledge of the anatomy and its variations. If not, they may cause acute or chronic infectious post- operative complications.

Acknowledgments

Source of funding: This research did not receive any specific grant from funding agencies in the public

Conflict of interests: The author declares that they have no conflict of interest to disclose.

Patient consentment: Not required Consent for publication: Not applicable

REFERENCES

1. Jensen OT, Shulman LB, Block MS, Iacono VJ. Report of the Sinus Consensus Conference of 1996. *Int J Oral Maxillofac Implants*. 1998;13 Suppl: 11-45. PMID: 9715571.
2. Del Fabbro M, Testori T, Francetti L, Weinstein R. Systematic review of survival rates for implants placed in the grafted maxillary sinus. *Int J Periodontics Restorative Dent*. 2004;24(6):565-77
3. Raghoobar GM, Onclin P, Boven GC, Vissink A, Meijer HJA. Long-term effectiveness of maxillary sinus floor augmentation: A systematic review and meta-analysis. *J Clin Periodontol*. 2019;46(21):307-318. doi: 10.1111/jcpe.13055. PMID: 30624789
4. Huwais S, Mazor Z, Ioannou AL, Gluckman H, Neiva R. A Multicenter Retrospective Clinical Study with Up-to-5-Year Follow-up Utilizing a Method that Enhances Bone Density and Allows for Transcrestal Sinus Augmentation Through Compaction Grafting. *Int J Oral Maxillofac Implants*. 2018;33(6):1305-1311. doi: 10.11607/jomi.6770
5. Tsai CF, Pan WL, Pan YP, et al. Comparison of 4 sinus augmentation Jensen OT, Shulman LB, Block MS, Iacono VJ. Report of the Sinus Consensus Conference of 1996. *Int J Oral Maxillofac techniques for implant placement with residual alveolar bone height ≤ 3 mm. *Medicine (Baltimore)*. 2020 Nov 13;99(46):e23180. doi: 10.1097/MD.00000000000023180*
6. Pjetursson BE, Asgeirsson AG, Zwahlen M, Sailer I. Improvements in implant dentistry over the last decade: comparison of survival and complication rates in older and newer publications. *Int J Oral Maxillofac Implants*. 2014;29:308-24. doi: 10.11607/jomi.2014suppl.g5.2
7. Wallace SS, Froum SJ. Effect of maxillary sinus augmentation on the survival of endosseous dental implants. A systematic review. *Ann Periodontol*. 2003;8(1):328-43. doi: 10.1902/annals.2003.8.1.328
8. Del Fabbro M, Testori T, Francetti L, Weinstein R. Systematic review of survival rates for implants placed in the grafted maxillary sinus. *Int J Periodontics Restorative Dent*. 2004;24(6):565-77
9. Starch-Jensen T, Aludden H, Hallman M, Dahlin C, Christensen AE, Mordenfeld A. A systematic review and meta-analysis of long-term studies (five or more years) assessing maxillary sinus floor augmentation. *Int J Oral Maxillofac Surg*. 2018 ;47 (1):103-116.doi:10.1016/j.ijom.2017.05.001

10. Raghoobar GM, Onclin P, Boven GC, Vissink A, Meijer HJA. Long-term effectiveness of maxillary sinus floor augmentation: A systematic review and meta-analysis. *J Clin Periodontol.* 2019;46(21):307-318. doi: 10.1111/jcpe.13055
11. Friedland B, Metson R. A guide to recognizing maxillary sinus pathology and for deciding on further preoperative assessment prior to maxillary sinus augmentation. *Int J Periodontics Restorative Dent.* 2014;34(6):807-15. doi: 10.11607/prd.2043
12. Tavelli L, Borgonovo AE, Re D, Maiorana C. Sinus presurgical evaluation: a literature review and a new classification proposal. *Minerva Stomatol.* 2017;66(3):115-131. doi: 10.23736/S0026-4970.17.04027-4
13. Valentini P, Artzi Z: Sinus Augmentation Procedure via the lateral window technique - Reducing invasiveness and managing complications: A narrative review. *Periodontology2000.* <https://doi.org/10.1111/prd.12443>
14. Pjetursson BE, Tan WC, Zwahlen M, Lang NP. A systematic review of the success of sinus floor elevation and survival of implants inserted in combination with sinus floor elevation Part I: Lateral approach. 2008;35(8):216–240. doi: 10.1111/j.1600-051X.2008.01272
15. Ella B, Sédarat C, Noble Rda C, et al. Vascular connections of the lateral wall of the sinus: surgical effect in sinus augmentation. *Int J Oral Maxillofac Implants.* 2008;23(6):1047-52
16. Testori T, Tavelli L, Yu SH, Scaini R, Darnahal A, Wallace SS, Wang HL. Maxillary Sinus Elevation Difficulty Score with Lateral Wall Technique. *Int J Oral Maxillofac Implants.* 2020;35(3):631-638. doi: 10.11607/jomi.8034
17. Kim J, Jang H. A review of complications of maxillary sinus augmentation and available treatment methods. *J Korean Assoc Oral Maxillofac Surg.* 2019;45(4):220-224. doi: 10.5125/jkaoms.2019.45.4.220
18. Scarano A, Lorusso F, Arcangelo M, D'Arcangelo C, Celletti R, de Oliveira PS. Lateral Sinus Floor Elevation Performed with Trapezoidal and Modified Triangular Flap Designs: A Randomized Pilot Study of Post-Operative Pain Using Thermal Infrared Imaging. *Int J Environ Res Public Health.* 2018;15(6):1277. doi: 10.3390/ijerph15061277. PMID: 29914159
19. Wallace SS, Tarnow DP, Froum SJ, et al. Maxillary sinus elevation by lateral window approach: evolution of technology and technique. *J Evid Based Dent Pract.* 2012;12(3):161-71. doi: 10.1016/S1532-3382(12)70030-1
20. Pjetursson BE, Tan WC, Zwahlen M, Lang NP. A systematic review of the success of sinus floor elevation and survival of implants inserted in combination with sinus floor elevation. *J Clin Periodontol.* 2008;35(8):216-40. doi: 10.1111/j.1600-051X.2008.01272.x
21. Froum SJ, Khouly I, Favero G, Cho SC. Effect of maxillary sinus membrane perforation on vital bone formation and implant survival: a retrospective study. *J Periodontol.* 2013;84(8):1094-9. doi: 10.1902/jop.2012.120458
22. de Almeida Ferreira CE, Martinelli CB, Novaes AB Jr, et al. Effect of Maxillary Sinus Membrane Perforation on Implant Survival Rate: A Retrospective Study. *Int J Oral Maxillofac Implants.* 2017;32(2):401-407. doi: 10.11607/jomi.4419
23. Tükel HC, Tatli U. Risk factors and clinical outcomes of sinus membrane perforation during lateral window sinus lifting: analysis of 120 patients. *Int J Oral Maxillofac Surg.* 2018;47(9):1189-1194. doi: 10.1016/j.ijom.2018.03.027
24. Nolan PJ, Freeman K, Kraut RA. Correlation between Schneiderian membrane perforation and sinus lift graft outcome: a retrospective evaluation of 359 augmented sinus. *J Oral Maxillofac Surg.*

- 2014;72(1):47-52.
doi:10.1016/j.joms.2013.07.020
25. Al-Moraissi E, Elsharkawy A, Abotaleb B, Alkebsi K, Al-Motwakel H. Does intraoperative perforation of Schneiderian membrane during sinus lift surgery causes an increased the risk of implants failure?: A systematic review and meta regression analysis. *Clin Implant Dent Relat Res.* 2018;20(5):882-889. doi: 10.1111/cid.12660
26. Testori T, Yu SH, Tavelli L, Wang HL. Perforation Risk Assessment in Maxillary Sinus Augmentation with Lateral Wall Technique. *Int J Periodontics Restorative Dent.* 2020;40(3):373-380. doi: 10.11607/prd.4179
27. Aimetti M, Massei G, Morra M, Cardesi E, Romano F. Correlation between gingival phenotype and Schneiderian membrane thickness. *Int J Oral Maxillofac Implants.* 2008;23(6):1128-32. PMID: 19216284
28. Lum AG, Ogata Y, Pagni SE, Hur Y. Association Between Sinus Membrane Thickness and Membrane Perforation in Lateral Window Sinus Augmentation: A Retrospective Study. *J Periodontol.* 2017;88(6):543-549. doi: 10.1902/jop.2017.160694
29. Insua A, Monje-Gil F, García-Caballero L, Caballé-Serrano J, Wang HL, Monje A. Mechanical characteristics of the maxillary sinus Schneiderian membrane ex vivo. *Clin Oral Investig.* 2018;22(3):1139-1145. doi: 10.1007/s00784-017-2201-4
30. Lin YH, Yang YC, Wen SC, Wang HL. The influence of sinus membrane thickness upon membrane perforation during lateral window sinus augmentation. *Clin Oral Implants Res.* 2016;27(5):612-7. doi: 10.1111/clr.12646
31. Insua A, Monje A, Chan HL, Zimmo N, Shaikh L, Wang HL. Accuracy of Schneiderian membrane thickness: a cone-beam computed tomography analysis with histological validation. *Clin Oral Implants Res.* 2017;28(6):654-661. doi: 10.1111/clr.12856
32. Park YB, Jeon HS, Shim JS, Lee KW, Moon HS. Analysis of the anatomy of the maxillary sinus septum using 3-dimensional computed tomography. *J Oral Maxillofac Surg.* 2011;69(4):1070-8. doi: 10.1016/j.joms.2010.07.020
33. Wen SC, Chan HL, Wang HL. Classification and management of antral septa for maxillary sinus augmentation. *Int J Periodontics Restorative Dent.* 2013;33(4):509-17. doi: 10.11607/prd.1609
34. Krennmair G, Ulm CW, Lugmayr H, Solar P. The incidence, location, and height of maxillary sinus septa in the edentulous and dentate maxilla. *J Oral Maxillofac Surg.* 1999;57(6):667-71; discussion 671-2
35. Marin S, Kirnbauer B, Rugani P, Payer M, Jakse N. Potential risk factors for maxillary sinus membrane perforation and treatment outcome analysis. *Clin Implant Dent Relat Res.* 2019;21(1):66-72. doi: 10.1111/cid.12699
36. Cho SC, Wallace SS, Froum SJ, Tarnow DP. Influence of anatomy on Schneiderian membrane perforations during sinus elevation surgery: three-dimensional analysis. *Pract Proced Aesthet Dent.* 2001;13(2):160-3. PMID: 11315435
37. Pizzini A, Basma HS, Li P, Geurs NC, Abou-Arraj RV. The impact of anatomic, patient and surgical factors on membrane perforation during lateral wall sinus floor elevation. *Clin Oral Implants Res.* 2021;32(3):274-284. doi: 10.1111/clr.13698
38. Shao Q, Li J, Pu R, Feng Y, Jiang Z, Yang G. Risk factors for sinus membrane perforation during lateral window maxillary sinus floor elevation surgery: A retrospective study. *Clin Implant Dent Relat Res.* 2021;23(6):812-820. doi: 10.1111/cid.13052
39. Nkenke E, Schlegel A, Schultze-Mosgau S, Neukam FW, Wiltfang J. The endoscopically controlled osteotome sinus floor elevation: a preliminary prospective study. *Int J Oral Maxillofac Implants.* 2002;17(4):557-66. PMID: 12182299

40. Díaz-Olivares LA, Cortés-Bretón Brinkmann J, Martínez-Rodríguez N, Martínez-González JM, López-Quiles J, Leco-Berrocal I, Meniz-García C. Management of Schneiderian membrane perforations during maxillary sinus floor augmentation with lateral approach in relation to subsequent implant survival rates: a systematic review and meta-analysis. *Int J Implant Dent.* 2021;7(1):91. doi: 10.1186/s40729-021-00346-7
41. Scala A, Lang NP, Velez JU, Favero R, Bengazi F, Botticelli D. Effects of a collagen membrane positioned between augmentation material and the sinus mucosa in the elevation of the maxillary sinus floor. An experimental study in sheep. *Clin Oral Implants Res.* 2016 Nov;27(11):1454-1461. doi: 10.1111/clr.12762
42. Proussaefs P, Lozada J, Kim J. Effects of sealing the perforated sinus membrane with a resorbable collagen membrane: a pilot study in humans. *J Oral Implantol.* 2003;29(5):235-41. doi: 10.1563/1548-1336(2003)029<0235:EOSTPS>2.3.CO;2
43. Schwarz L, Schiebel V, Hof M, Ulm C, Watzek G, Pommer B. Risk Factors of Membrane Perforation and Postoperative Complications in Sinus Floor Elevation Surgery: Review of 407 Augmentation Procedures. *J Oral Maxillofac Surg.* 2015;73(7):1275-82. doi: 10.1016/j.joms.2015.01.039
44. Testori T, Wallace SS, Del Fabbro M, et al. Repair of large sinus membrane perforations using stabilized collagen barrier membranes: surgical techniques with histologic and radiographic evidence of success. *Int J Periodontics Restorative Dent.* 2008;28(1):9-17
45. Proussaefs P, Lozada J. The "Loma Linda pouch": a technique for repairing the perforated sinus membrane. *Int J Periodontics Restorative Dent.* 2003;23(6):593-7. PMID: 14703763
46. Valentini P, Eid G, Ferrandi JM, Abensur D, Testori T: Management of sinus membrane perforations. *Europ Dental Impl J.* 2019;15:64-65
47. Testori T, Yu SH, Tavelli L, Wang HL. Perforation Risk Assessment in Maxillary Sinus Augmentation with Lateral Wall Technique. *Int J Periodontics Restorative Dent.* 2020;40(3):373-380. doi: 10.11607/prd.4179
48. de Oliveira HAAB, de Moraes RPF, Limirio PHJO, Dechichi P. Repair of a perforated sinus membrane with an autogenous periosteal graft: a study in 24 patients. *Br J Oral Maxillofac Surg.* 2018;56(4):299-303. doi: 10.1016/j.bjoms.2017.12.020
49. Beck-Broichsitter BE, Westhoff D, Behrens E, Wiltfang J, Becker ST. Impact of surgical management in cases of intraoperative membrane perforation during a sinus lift procedure: a follow-up on bone graft stability and implant success. *Int J Implant Dent.* 2018;4(1):6. doi: 10.1186/s40729-018-0116-8
50. Shlomi B, Horowitz I, Kahn A, Dobriyan A, Chaushu G. The effect of sinus membrane perforation and repair with Lambone on the outcome of maxillary sinus floor augmentation: a radiographic assessment. *Int J Oral Maxillofac Implants.* 2004;19(4):559-62. PMID: 15346754
51. Öncü E, Kaymaz E. Assessment of the effectiveness of platelet rich fibrin in the treatment of Schneiderian membrane perforation. *Clin Implant Dent Relat Res.* 2017;19(6):1009-1014. doi: 10.1111/cid.12528
52. Hernández-Alfaro F, Torradeflot MM, Carlos Marti C. Prevalence and management of Schneiderian membrane perforations during sinus-lift procedures. *Clin Oral Implants Res.* 2008;19(1):91-8. doi: 10.1111/j.1600-0501.2007.01372.x
53. Moreno Vazquez JC, Gonzalez de Rivera AS, Gil HS, Mifsut RS. Complication rate in 200 consecutive sinus lift procedures: guidelines for prevention and treatment. *J Oral Maxillofac Surg.* 2014;72(5):892-901. doi: 10.1016/j.joms.2013.11.023
54. Sakkas A, Konstantinidis I, Winter K, Schramm A, Wilde F. Effect of Schneiderian membrane perforation on sinus lift graft outcome using two different donor sites: a retrospective study of 105 maxillary sinus elevation procedures. *GMS*

Interdiscip Plast Reconstr Surg DGPW. 2016;5:11. doi: 10.3205/iprs000090

2011;22(10):1200-1212. doi: 10.1111/j.1600-0501.2010.02096.x

55. Tajima N, Ohba S, Sawase T, Asahina I. Evaluation of sinus floor augmentation with simultaneous implant placement using platelet-rich fibrin as sole grafting material. *Int J Oral Maxillofac Implants.* 2013;28(1):77-83. doi: 10.11607/jomi.2613

56. Ali S, Bakry SA, Abd-Elhakam H. Platelet-Rich Fibrin in Maxillary Sinus Augmentation: A Systematic Review. *J Oral Implantol.* 2015;41(6):746-53. doi: 10.1563/aaid-joi-D-14-00167

57. Cricchio G, Sennerby L, Lundgren S. Sinus bone formation and implant survival after sinus membrane elevation and implant placement: a 1- to 6-year follow-up study. *Clin Oral Implants Res.*

58. Dagba AS, Mourlaas J, Ochoa Durand D, et al. A Novel Approach to Treat Large Schneiderian Membrane Perforation -A Case Series. *Int J Dent Oral Health.* 2015;1(5) <http://dx.doi.org/10.16966/2378-7090.137>

59. Felisati G, Lozza P, Chiapasco M, Borloni R. Endoscopic removal of an unusual foreign body in the sphenoid sinus: an oral implant. *Clin Oral Implants Res.* 2007;18(6):776-80. doi: 10.1111/j.1600-0501.2007.01409.x

60. Pikos MA, Miron RJ. To Drill or to Densify? Clinical Indications for the Use of Osseodensification. *Compend Contin Educ Dent.* 2019;40(5):276-282. PMID: 31067068

ԿՈՂԱՅԻՆ ՄՈՏԵՑՄԱՍԲ ՎԵՐԾՆՈՏԱՅԻՆ ԾՈՑԵՐԻ ՄԵԾԱՑՄԱՆ ՆԵՐՎԻՐԱՀԱՏԱԿԱՆ ԲԱՐԴՈՒԹՅՈՒՆՆԵՐԻ ԿԱՆԽԱՐԳԵԼՈՒՄ ԵՎ ԿԱՌԱՎԱՐՈՒՄ: ԱԿՆԱՐԿ

Պասկալ Վալենտինի*

* Կորսիկայի համալսարան Պասկուալ Պաուլի, Առողջապահության ինստիտուտ, իմպլանտների վիրաբուժության բաժին, Տատտոնե հիվանդանոց, 20250 Կորտե, Ֆրանսիա

Ամփոփում

Վերծնոտային ծոցերի մեծացման կողային մեթոդը դարձել է սովորական տեխնիկա, իմպլանտների գոյատևման մակարդակը գերազանցում է 96%-ը վերծնոտային ծոցերի հատվածում: Այնուամենայնիվ, այստեխնիկան կարող է կապված լինել որոշ բարդությունների հետ, որոնք կարող են առաջանալ տարբեր ժամանակներում և ազդել իմպլանտների կարճաժամկետ և երկարաժամկետ գոյատևման մակարդակի վրա: Այս հոդվածը նվիրված է ներվիրահատական բարդություններին, որոնք հիմնականում պայմանավորված են անատոմիական փոփոխություններով, ինչպիսիք են վերծնոտային ծոցերի ձևը, միջնապատերի առկայությունը և այլ առանձնահատկություններ, ինչպիսիք են անտրալ ավելույնի զարկերակի ներոսկրային անցումը, որը կարող է խանգարել վեստիբուլյարի պատուհանի դիրքին:

Ռիսկը բացահայտելու և բարդությունները կանխելու համար անհրաժեշտ է անատոմիայի կատարյալ իմացությունը: Եթե բարդություն առաջանա, այն պետք է արդյունավետ կերպով բուժել՝ կանխելու հետվիրահատական բարդությունները, որոնք կարող են հետևել՝ քրոնիկ կամ սուր սինուսիտի տեսքով: Ներվիրահատական բարդությունների տարածվածությունը հակառակը համեմատական է վիրաբույժի հմտությանը և փորձին՝ առանց իմպլանտների գոյատևման վրա ազդեցության, եթե դրանք պատշաճ կերպով կառավարվեն:

Valentini P. Prevention and management of intra-operative complications in maxillary sinus augmentation using the lateral approach? A review. *Bulletin of Stomatology and Maxillofacial Surgery.* 2023;19(2):16-26. doi: 10.58240/1829006X-2023.19.2-16

Паскаль Валентини*

* Университет Корсики Паскуале Паоли, Институт здоровья, отделение хирургии имплантатов, больница Таттоне, 20250 Кортэ, Франция

Абстракт

Латеральный доступ при увеличении верхнечелюстной пазухи стал рутинной техникой с коэффициентом приживаемости имплантата более 96% в задней области верхней челюсти. Однако этот метод может быть связан с некоторыми осложнениями, которые могут возникать в разные моменты времени и влиять на краткосрочную и долгосрочную приживаемость имплантатов. Эта статья посвящена интраоперационным осложнениям, которые в основном связаны с анатомическими вариациями, такими как форма пазухи, наличие перегородок и другими особенностями, такими как внутрикостное прохождение антральной альвеолярной артерии, которое может мешать положению вестибулярного окна.

Поэтому для выявления риска и предотвращения осложнений необходимо идеальное знание анатомии. Если возникнет осложнение, его необходимо лечить эффективным образом, чтобы предотвратить возможные послеоперационные осложнения в виде хронического или острого синусита. Распространенность интраоперационных осложнений обратно пропорциональна навыкам и опыту хирурга и не влияет на приживаемость имплантата при правильном лечении.