

DOI: 10.58240/1829006X-2023.19.2-38



## CLINICAL ARTICLES

THE APPLICATION OF AN ENAMEL MATRIX PROTEIN (EMDOGAIN) IN  
REGENERATIVE PERIODONTAL THERAPY. CLINICAL SERIES

Daniel Melker DDS \*

Private Practice Limited to Periodontics, Clearwater, Florida, USA

\*Corresponding author: correspondence to Daniel J. Melker; Mailing address: 28465 US Highway 19 N Ste 204,  
Clearwater Florida, 33761-2511

**Received:** Feb. 15, 2023; **Accepted:** Mar. 27, 2023; **Published:** Apr. 15, 2023

**Abstract**

**Objectives:** The purpose of this clinical series is to present indications for regenerative therapy with EMD.

**Materials and Methods:** The study included 53 patients with osseous defects from 7-15mm's in depth. Each patient understood that the procedures were not within the normal treatment due to the severity of the defects but opted to accept treatment. Along with EMD each defect also had freeze dried demineralized bone placed in the defect as well.

**Results:** Reentry of the original defects was undertaken at approximately 1 year after surgery. It was noted that for the most part significant improvement was noted in almost all defects. Exact improvement of defects was not calculated.

In several cases 10-year reentry was undertaken and in fact further reduction in defects were noted. It could not be determined at any time over the 10-year period that the reduction in pocket depth was in fact bone as no histology was ever taken to verify what the defects were filled with.

**Conclusions:** Clinical studies have indicated that treatment with EMD with freeze dried demineralized bone positively influences regenerative periodontal therapy.

**Keywords:** Periodontitis, Treatment of periodontitis, Enamel matrix derivative; Periodontal regeneration

**Introduction**

Periodontal (gum) disease is one of the most common oral diseases, half of adults aged 30 and over have some degree of gum disease, and the percentage increases with age because the symptoms of periodontitis can be very subtle, many don't realize they have gum disease until it's severe, which can lead to tooth loss.<sup>1-4</sup>

Elimination of pathological processes in the periodontal pocket, and elimination of the pathological pocket is one of the main goals of

periodontal surgery, which is why this process is also called pocket treatment (pocket therapy). Periodontal therapy is aimed at preventing the disease, slowing down or stopping the progression of the disease, restoring the lost periodontium and maintaining the achieved therapeutic goals. Treatment of chronic periodontitis can be done by non-surgical or surgical approach. Various treatments have been used, including subgingival curettage, gingivectomy, modified Widmann flap, full thickness or split flaps with or without bone recontouring.<sup>5-8</sup>

The best surgical approach remains controversial, although the results of longitudinal clinical trials have highlighted the advantages and disadvantages of each method. Since every periodontal pocket is different, specific treatment recommendations will depend on the depth and shape of the pocket, and whether the inflammation is restricted to the gum tissue, or if it has spread to the bone that lies beneath. Getting rid of plaque bacteria (also called biofilm) and tartar is the first step in keeping gum disease from getting worse. In the case of inflamed gums with no bone loss, even a pocket depth of 4 mm or 5 mm may be treated with professional cleanings to remove the causes of the inflammation, along with an enhanced at-home oral care regimen.<sup>9-12</sup>

Stage of surgical treatment of periodontal diseases logical sequence of complex treatment of periodontal diseases. The indications for surgical periodontal treatment are: pockets with a depth of 5 mm or more, the presence of bone pockets.<sup>13-16</sup>

Flap operations are one of the main methods of treatment of periodontal pockets. They are carried out only after the initial stage of periodontal treatment, with high oral hygiene. River operations are aimed at treating the affected surfaces of the roots in an open way, as well as reducing or eliminating pathological pockets.

Some methods have evolved over time. Each method has its own indications for use and features of the obtained results. The choice of method depends on the clinical situation and aesthetic requirements of the patient, as well as the doctor's preferences, experience and financial capabilities of the patient. In the presence of an active inflammatory process in the periodontium, stimulation of bone regeneration is not appropriate. In the presence of an acute purulent process, rag surgery is not only not advisable, but also dangerous due to the risk of spread of the purulent process.

The goal of regenerative periodontal therapy is to restore lost periodontal structures (i.e., new formation of root cementum, periodontal ligament, and alveolar bone). However, complete and predictable regeneration is still an elusive goal.<sup>17-19</sup>

Periodontal surgery has evolved with the use of new methods and materials. Several surgical techniques have been developed for periodontal tissue regeneration, including guided tissue regeneration (GTR), bone grafting (BG), and enamel matrix

derivatives (EMD).<sup>20,21</sup> Application of the technique guided tissue regeneration (GTR) - in some cases, it is possible to recreate previously lost tissue, depending on the nature of the tissue / bone destruction that has occurred.<sup>22,23</sup> Biocompatible materials are used alone or in combination, which can help the body to produce new bone and gum tissue.

A biocompatible membrane, applied during the procedure, isolates the area of bone damage around the tooth, creating an environment for the formation of new bone, prevents the migration of the faster moving epithelium and connective tissue of the gums into the wound space; allowing time for cement to migrate into the wound space; periodontal ligament and bone to refill the area.<sup>24,25</sup>

The guided tissue regeneration technique consists of placing a non-resorbable or resorbable membrane between the recession defect and exposed bone on one side and a coronally advanced flap on the other, in order to allow selective repopulation of the root surface by periodontal ligament cells that can form a new connective tissue junction between the root surface and alveolar bone.<sup>26,27</sup>

Grafting materials used during regenerative procedures may be allogeneic, xenografts they function as biocompatible space fillers and the use of these materials can stimulate bone growth and serve as a scaffold for new bone deposition. The resulting bone filling may also be accompanied by the development of a long junctional epithelium and/or increased attachment of connective tissue.

To date, enamel matrix derivative (EMD) is considered one of the few biomaterials for clinical use capable of demonstrating true periodontal regeneration.<sup>28-30</sup>

Amelogenins are a family of highly conserved extracellular matrix proteins derived from a single gene and play a role in biomineralization and hard tissue formation. Amelogenins can have a positive effect on wound healing, bone formation. Amelogenin (a derivative of the basic enamel matrix protein) has been shown to be effective in stimulating gingival tissue growth).

When applied Amelogenin to tooth root surfaces, amelogenins precipitate to form a stable extracellular matrix with a hydrophobic surface capable of maintaining interaction with cells in adjacent tissues.<sup>31</sup> The major (>95%) component of Emdogain® is Amelogenins (Amel). Emdogain® (Straumann AG,

Basel, Switzerland) is well established as a topical adjunct to periodontal surgery to stimulate the regeneration of periodontal tissue lost due to periodontal disease.

Emdogain® stimulates local growth factor secretion and cytokine expression in treated tissues, inducing a regenerative process that mimics odontogenesis. Emdogain is applied during surgery and forms a coating on the roots of the teeth. The gel itself dissolves after 2 days, leaving the active substance.<sup>32</sup> Many case reports have now been published showing that EMD significantly improves the level of periodontal attachment and reduces probing pocket depth compared to open flap debridement. The use of EMD in periodontal regeneration procedures demonstrates stable periodontal regeneration after 5 years of follow-up. EMD is adsorbed both on hydroxyapatite and collagen, and on bare tooth roots.<sup>33</sup> EMD treatment likely mimics odontogenesis and works to restore lost periodontal tissues by recruiting cementoblasts to the root surface and hence stimulating their formation of root cementum, which will then regenerate periodontal fibers and alveolar bone.<sup>34,35</sup>

A review of the literature indicates that the use of EMD may result in more bone formation when applied to supporting defects compared to non-supporting defects.<sup>36-38</sup>

EMD promotes the proliferation of PDL cells, cementoblasts and osteoblasts, allowing the restoration of normal periodontal architecture within a short intervention time.<sup>39</sup>

In a meta-analysis by Matarasso et al. that the combination of EMD and bone grafting materials increased CAL and reduced PD compared with EMD alone, the authors did not provide information on the comparative assessment of radiological bone level.<sup>40</sup> This opens up possibilities for EMD applications as discussed below. The purpose of this clinical series is to present indications for regenerative therapy with Emdogain®.

### Materials and methods

The study included 53 patients (mean age 51.7 years, 28 men and 25 women) with chronic periodontitis, after initial periodontal therapy with intraosseous defects  $\geq 3$  mm in depth in one or more teeth. Bone material and EMD were applied upaccent.

Inclusion criteria were the presence of interproximal areas with a probing depth (PD)  $\geq 6$  mm, at least one intraosseous defect  $\geq 3$  mm deep in the area of the teeth, and an adequate level of plaque control (mean plaque index  $\leq 1$ ). Participants were required to undergo initial periodontal therapy.

Exclusion criteria were the presence of uncontrolled systemic diseases, smoking, concomitant or previous use of such as bisphosphonates or other drug therapy, current pregnancy, contraindications to dental and / or surgical interventions.

Conservative treatment was carried out according to the FMDP. All teeth were scaled and root polished with an ultrasonic scaler. The patient was instructed in proper oral hygiene and rinsing with chlorhexidine solution (0.2% 3 times a day for 2 weeks).

The sulcular incisions with a 15c scalpel and a thin elevator were used to raise the mucoperiosteal flaps in various places. Then careful degranulation of intraosseous defects and scaling of the root surface were applied. The operating field was flushed with saline. EDTA was applied to the roots surfaces for 45 seconds removing the smear layers. EMD was then placed in the defects. At this point the filling material was saturated with EMD and then placed in the defect. The flap was tightly closed with sutures using the with 5-0 Chromic gut absorbable suture. Oral hygiene measures were restricted to local rinses with chlorhexidine 0.2% three times a day for 3 weeks. After suture removal or absorption no brushing was allowed for two full weeks. The first postoperative evaluation underwent at 6 months, which was followed by a strict maintenance protocol.

The mean increase in clinical attachment level (CAL) at 2 years was 5mm from baseline. the average decrease in the decrease in probing depth (PD) after 3 years was 3.2 mm, respectively, the average percentage of bone filling after 3 years was up to 31%-75%. The use of EMD in patients with intraosseous defects showed effectiveness in terms of clinical periodontal and radiographic parameters for 3 years.

In the presented clinical cases reported patients with periodontitis with intraosseous defects 3 years after regenerative periodontal therapy with enamel matrix derivative (EmdogainR; Straumann™), it can be stated that the condition of the teeth has changed for the better. Many studies show

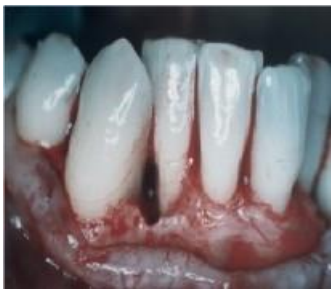significant improvement of periodontally affected teeth with the use of an enamel matrix.

**Case report 1**

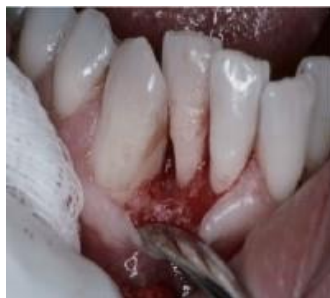The patient presented with the presence of pronounced defects in the lateral incisors and canine teeth of the lower jaw, after clinical and radiological examinations, a treatment plan was drawn up, which included initial conservative periodontal therapy, then bone plastic in the intraosseous defects. After local anesthesia, buccal gingival tissue was incised mesial and distal to the defect site to provide access for visualization and instrumentation of the defect. After flap reflection, granulation tissue was removed from the defect. Scaling and root planing were performed with hand and the defect was rinsed with water. Area debrided and root surfaces cleaned. Phosphoric acid 38% was applied to the surfaces for 25 seconds to remove the smear layer.

After site preparation, the EMD gel was applied on the root surfaces and into the intrabony defect. A mixture of EMD and freeze-dried demineralized bone was then placed into the defect. Flaps were repositioned at the preoperative level or slightly coronal without tension. Sutures were placed using 5-0 Chromic gut absorbable sutures. Pain control was obtained by 400 mg Ibuprofen 3 times per day for the first 72 h and subsequent doses were indicated only if needed. Patient was advised to rinse three times per day with a 0.2% chlorhexidine gluconate solution for 6 weeks and mechanical tooth cleaning was not allowed in the surgical area during this period. However if the soft tissue was sufficiently healed after 3 weeks the patient was instructed to use a Braun circular head toothbrush twice a day.

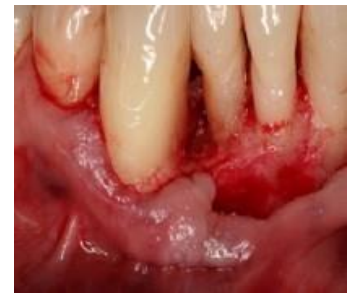Professional oral hygiene/maintenance procedures and reinforcement of oral hygiene instructions were performed during follow-up visits.



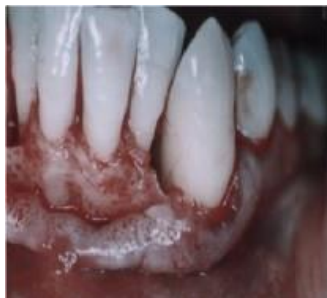*Figure 1. Day of surgery, intraosseous defect 7-8mm's with bone only present ob the buccal and lingual*



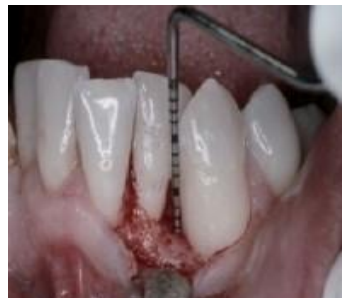*Figure 2. 1 year evaluation with a small incision to evaluate material present. 95% of the defect was filled with a material that resembled bone*



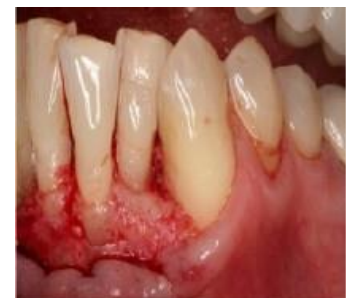*Figure 3. 10-year reentry shoed virtually no changes from 1-year photos*



*Figure 4. Day of surgery, intraosseous 6-8mm's with bone only present on the buccal and lingual of the defect*



*Figure 5. 1-year post surgery showed a material that appeared to be similar to bone. Fill appeared to be 95%*



*Figure 6. 10-year post surgery 0 changes occurred*

### Case report 2

The patient applied for the presence of pronounced the intraosseous defects surrounding the apex on the mandibular right canine tooth. The patient had no money for any treatment and it was determined that an effort would remake to keep the tooth for free along with endodontics. After clinical and radiological examinations, a treatment plan was drawn up, which included initial conservative periodontal therapy, then bone graft in intraosseous

defects. It was decided to splint the right canine so it would not fall out at surgery. The periodontal treatment protocol was the same as in the clinical case 1 patient: After site preparation, the EMD gel was applied on the root surfaces and into the intrabony defect. A mixture of EMD and freeze-dried demineralized bone was then placed into the defect. The treatment undertaken was simply to try to buy time for the patient to position herself financially for future treatment of a more permanent nature.

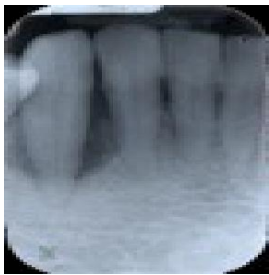


Figure 7. Intraoral periapical baseline radiographic view, bone loss as seen in the right cuspid tooth

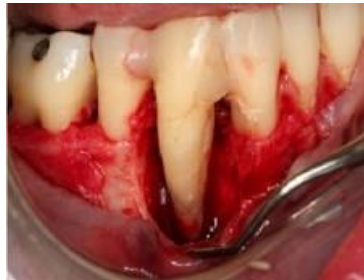

Figure 8. Application of standard protocol for treatment with EMD was undertaken. Endodontic treatment followed 6 weeks later

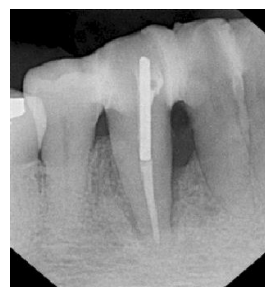

Figure 9. 24-months follow-up Intraoral periapical radiographic view

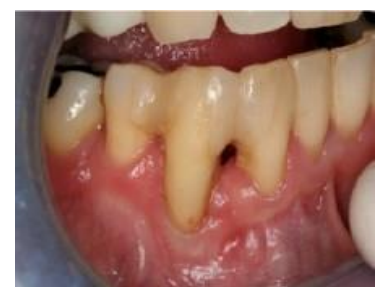

Figure 10. 24-month follow-up clinical view with no bleeding upon probing

### Case report 3

The patient presented with the presence of pronounced the intraosseous defects surrounding the mandibular right premolar. After clinical and radiological examinations, a treatment plan was drawn up, which included initial conservative

periodontal therapy, then bone graft in intraosseous defects. The periodontal treatment protocol was the same as in all previous cases. After site preparation, the EMD gel was applied on the root surfaces and into the intrabony defect. A mixture of EMD and freeze-dried demineralized bone was then placed into the defect.

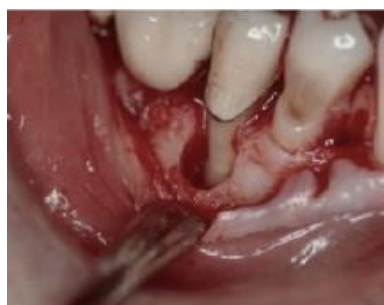

Figure 11. Intraoral periapical baseline radiographic view, bone loss as seen in right bicuspid tooth

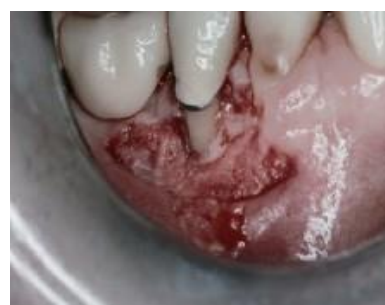
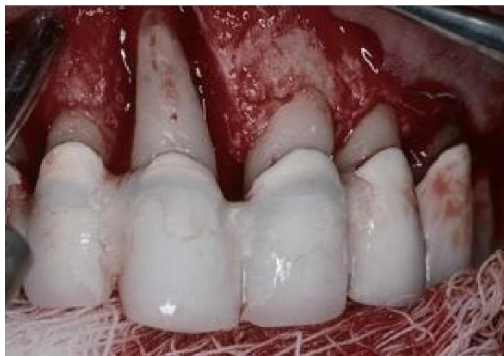
Figure 12. Reentry at 1 year show the original defect gone and a material that appears to be of the consistency of bone present. 95% of the defect was filled

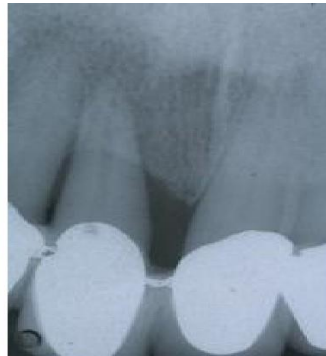#### Case report 4

The patient presented with an intraosseous defects surrounding the upper right central incisor. The patient had limited finances not even in a position to replace the central incisor with a partial denture. Since this was in the early use of EMD it was determined to splint the tooth and make an effort to keep it. After clinical and radiological examinations, a treatment plan was drawn up,

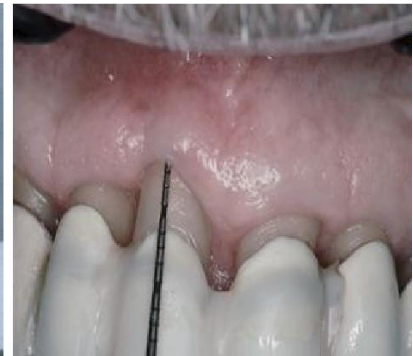which included initial conservative periodontal therapy, then bone plastic in the intraosseous defects. It was decided to splint the anterior teeth. The periodontal treatment protocol was the same as in the clinical case 1 patient: After site preparation, the EMD gel was applied on the root surfaces and into the intrabony defect. A mixture of EMD and freeze-dried demineralized bone was then placed into the defect.



*Figure 13. Intraosseous defects surrounding the apex 11 incisor tooth*



*Figure 14. Intraoral periapical radiographic view 1 year later*

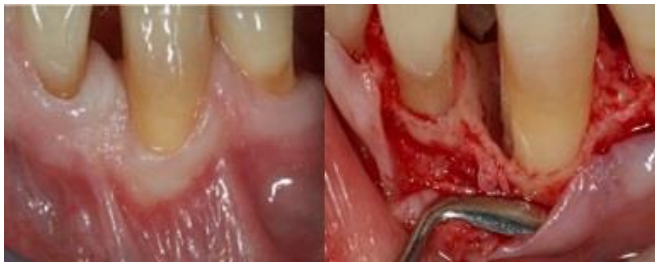

*Figure 15. Probing at 1 year showed 1mm at best with adequate pressure placed. The patient continued with no real probings up to 8 years when he left the practice to return up north*

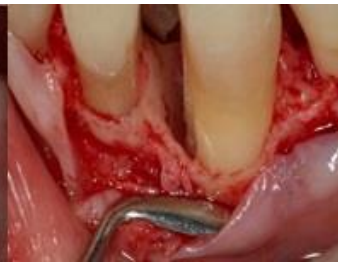#### Case report 5

The patient presented with an intraosseous defects surrounding the lower left cuspid. Reflection of flaps on the buccal and lingual for ideal visibility. Close attention to removal of all granulation was undertaken in the flap itself. Meticulous removal of calculus and altered cementum ensured using curettes as well as diamond burs where possible Prefgel (EDTA) was used to remove the smear layer. Prefgel was part of the Emdogain

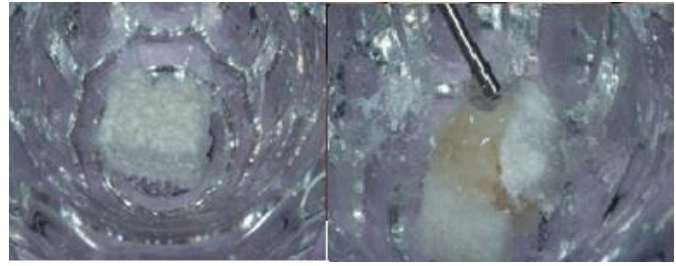
protocol. I also used 38% Phosphoric acid for 15 seconds as an alternative to Prefgel. Emdogain was then placed in the defect. Highly important is that Emdogain be placed where no blood was present as the proteins in the blood would bind the Emdogain. Whatever filling material was also used was soaked in Emdogain prior to placing in the defect. In the case below a small CT graft was added to the buccal bone which really had no bearing on the regenerative procedure. Primary closure with 5-0 Chromic absorbable suture was used.



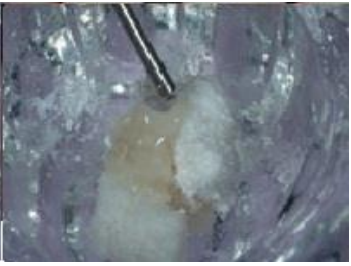*Figure 16. Lower left cuspid photo prior to entry for an attempt to eliminate deep pocket*



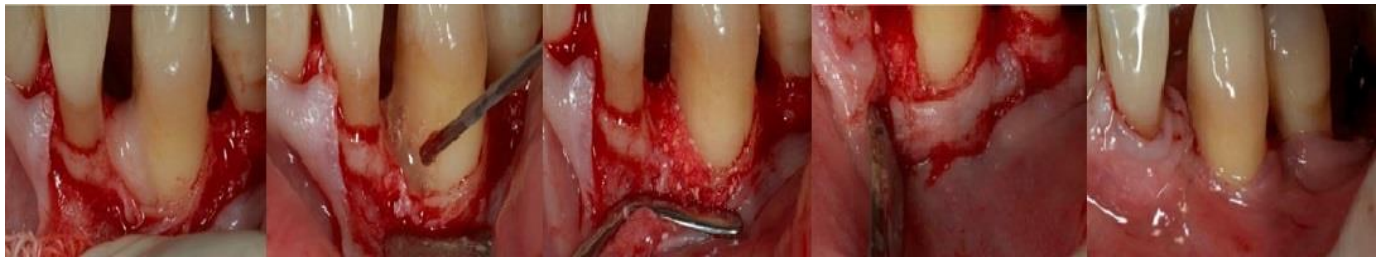*Figure 17. Reflection of flaps on the buccal and lingual for ideal visibility. Close attention to removal of all granulation was undertaken in the flap itself*



*Figure 18. Bio-Oss Collagen placed in dampen dish*



*Figure 19. Bio-Oss collagen is impregnated with Emdogain and mixed thoroughly so all the material has EMD present*



*Figure 20. Prefgel (EDTA) was used to remove the smear layer. Prefgel was part of the Emdogain protocol. I also used 38% Phosphoric acid for 15 seconds as an alternative to Prefgel*

*Figure 21. Emdogain was then placed in the defect. Highly important is that Emdogain be placed where no blood was present as the proteins in the blood would bind the Emdogain*

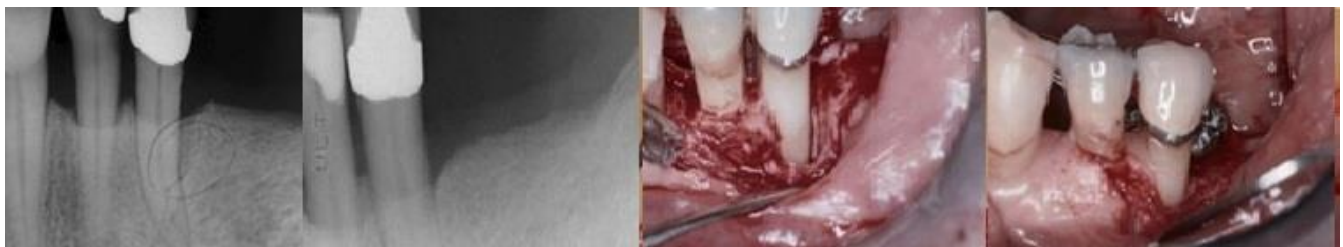*Figure 22. Whatever filling material was also used was soaked in Emdogain prior to placing in the defect*

*Figure 23. In the case below a small CT graft was added to the buccal bone which really had no bearing on the regenerative procedure*

*Figure 24. Primary closure with 5-0 Chromic absorbable suture was used*

**Case report 6**

The patient presented with an intraosseous defects surrounding right lower second bicuspid.



*Figure 25. Distal defect of lower right second bicuspid to be treated*

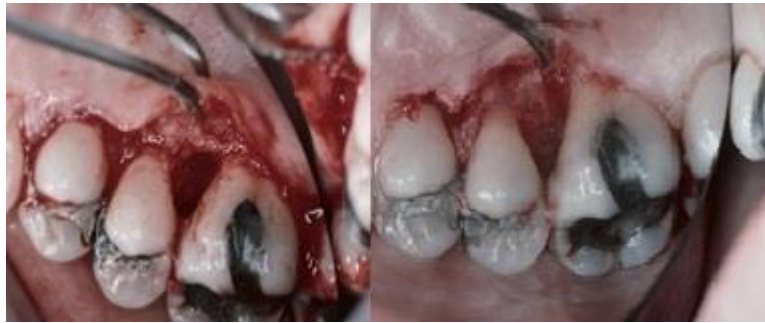*Figure 26. 1-year post surgery radiographically appears to have a material that looks like bone having filled the defect*

*Figure 27. Entry prior to placement of EMD and filling material*

*Figure 28. Reentry at 1 year shows nice fill with a material that resembles bone*

Case report 7

The patient presented with an intraosseous defects surrounding between maxillary molar and bicuspid.



*Figure 29. Deep defect between maxillary bicuspid and molar. EMD and freeze-dried demineralized bone placed in defect*

*Figure 30. 1-year reentry shows excellent fill with a material that resembles bone*

**Discussion**

In the 1990's Emdogain came to market as a method of bone regeneration. It was however FDA approved for use only by itself. As the practitioner I was uncomfortable using it by itself. So initially all procedures had freeze dried demineralized bone placed along with Emdogain. A huge advantage of Emdogain was its ability to prevent epithelial down growth which eliminated the need for a barrier. Years later the use of Bio-Oss collagen was instituted with Emdogain as a substitute for FDDMB.

Restoration of lost periodontal structures (i.e., new formation of root cementum, periodontal ligament and alveolar bone) is the goal of regenerative periodontal therapy.

Enamel matrix protein derivatives (EMD) play an important role in periodontal wound healing. There is a large body of clinical and experimental evidence that demonstrates that enamel matrix proteins (EMPs) mediate periodontal regeneration.

EMRs have been used therapeutically with EMD, which is clinically available as Emdogain. There are histological data in animals and humans showing the restoration of true periodontal regeneration with new bone, new PDF, new cementum and functional fibers.<sup>42,43</sup>

Surgical periodontal treatment of deep intraosseous defects with EMD can lead to a significant improvement in clinical parameters than open flap debridement alone.<sup>35</sup>

Clinical trials have been conducted for the assessment of the effectiveness of EMD regarding its ability to improve periodontal health. One of the first human studies was a split-mouth randomized multicenter trial undertaken to compare the longterm effect of EMD treatment as an adjunct to modified Widman flap (MWF) surgery vs. MWF plus a placebo (PGA).<sup>44</sup> Thirty-three patients with 34 paired test and control sites (one- or two-wall bony defects > 4 mm deep) were enrolled in the study and monitored for 36 months. The results in the EMD group were better, as shown by a gain in the clinical attachment level, probing depth reduction, and restoration of bone radiographically.

The superiority of surgically treating intrabony defects with EMD compared with open-flap debridement has also been shown with re-entry 12 months post-surgery, where the average defect fill was 2.4 mm greater with EMD (Froum et al., 2001).<sup>45</sup>

Keila et al investigated the effects of EMD on rat bone marrow stromal cells and on gingival fibroblasts.<sup>46</sup> EMD increased the osteogenic capacity of bone marrow and mineralized nodule formation. The presence of EMD in the initial stages (first 48 hours) of the culture was crucial for this effect. In contrast, EMD did not induce osteoblastic differentiation of gingival fibroblasts but increased both cell numbers and amount of matrix produced by up to two-fold.

The use of EMD indicated a positive effect on both surgical and non-surgical therapy. However, the

available literature is scarce, with low evidence in non-surgical approach and modest evidence in surgical approach using EMD. More RCTs with standardize protocols are necessary to evaluate the efficacy of using EMD in both therapies.<sup>46,7</sup>

Regenerative surgery with a combination of enamel matrix derivative (EMD) and natural bone mineral (NBM) can result in bone formation and clinical results can be maintained for up to 5 years.<sup>48,49</sup>

A study by Alessandro Crea et al showed that the treatment of intraosseous defects in patients with chronic advanced periodontitis with NTR or EMD led to a significant improvement in clinical parameters. Significance tests showed better results with EMD, although absolute differences between treatments were small.<sup>50</sup>

This cases series demonstrates that of intraosseous defects with Emdogain can be successfully treated and preserved. The combination of EMD and bone substitutes may result in some improvement in soft and hard tissue parameters compared to EMD treatment alone.

Clinical studies have indicated that treatment with EMD positively influences regenerative periodontal therapy. EMD contributes to the replenishment of bone tissue of intraosseous defects, as well as the regeneration of the destroyed periodontal apparatus.

### Conclusions

Clinical studies have indicated that treatment with EMD with freeze dried demineralized bone positively influences regenerative periodontal therapy.

## REFERENCES

1. Nazir MA. Prevalence of periodontal disease, its association with systemic diseases and prevention. *Int J Health Sci (Qassim)*. 2017 Apr;11(2):72-80. PMID: 28539867
2. Pihlstrom BL, Michalowicz BS, Johnson NW. Periodontal diseases. *Lancet*. 2005;366(9499):1809-20. doi: 10.1016/S0140-6736(05)67728-8.
3. Kinane DF, Stathopoulou PG, Papapanou PN. Periodontal diseases. *Nat Rev Dis Primers*. 2017;3:17038. doi: 10.1038/nrdp.2017.38
4. Highfield J. Diagnosis and classification of periodontal disease. *Aust Dent J*. 2009;54(1):S11-26. doi: 10.1111/j.1834-7819.2009.01140.x.
5. Kripal K, Chandrashekar BM, Anuroopa P. Practical periodontal surgery: an overview. *Journal of Evolution of Medical and Dental Sciences*. 3(66):14398-14409 DOI:10.14260/jemds/2014/3930
6. Heitz-Mayfield LJA, Trombelli L, Heitz F, Needleman I, Moles D. A systematic review of the effect of surgical debridement vs. non-surgical debridement for the treatment of chronic periodontitis. *J Clin Periodontol*. 2002;29:92-102. doi:10.1034/j.1600-051x.29.s3.5
7. Bajaj P, Agarwal E, Rao NS. Autologous Platelet-Rich Fibrin in the Treatment of 3-Wall Intra-bony Defects in Aggressive Periodontitis: A Randomized Controlled Clinical Trial. *Journal of Periodontology*. 2017;88(11):1186-1191. doi:10.1902/jop.2017.120661
8. Sharma A, Pradeep AR, Treatment of 3-Wall Intra-bony Defects in Patients with Chronic Periodontitis with Autologous Platelet-Rich Fibrin: A Randomized Controlled Clinical Trial. *Journal of Periodontology*. 2011;82(12):1705-1712. doi: 10.1902/jop.2011.110075
9. Aimetti M. Nonsurgical periodontal treatment. *Int J Esthet Dent*. 2014;9(2):251-67. PMID: 24765632
10. Drisko CH. Nonsurgical periodontal therapy. *Periodontol* 2000. 2001;25:77-88. doi: 10.1034/j.1600-0757.2001.22250106.x
11. Hanes PJ, Purvis JP. Local anti-infective therapy: pharmacological agents. A systematic review. *Ann Periodontol*. 2003;8(1):79-98. doi: 10.1902/annals.2003.8.1.79
12. Haffajee AD, Socransky SS, Gunsolley JC. Systemic anti-infective periodontal therapy. A systematic review. *Ann Periodontol*.

- 2003;8(1):115-81. doi: 10.1902/annals.2003.8.1.115
13. Roshna T, Nandakumar K. Generalized aggressive periodontitis and its treatment options: case reports and review of the literature. *Case Rep Med.* 2012;2012:1-17. doi: 10.1155/2012/535321
14. Owczarek B, Kiernicka M, Galkowska E, Wysokińska-Miszczuk J. The application of Bio-Oss and Bio-Gide as implant materials in the complex treatment of aggressive periodontitis. *Ann Univ Mariae Curie Skłodowska Med.* 2003;58(1):392-6. PMID: 15315021
15. Graziani F, et al. Surgical treatment of the residual periodontal pocket. *Periodontology 2000.* 2017;76(1):150-163 doi:10.1111/prd.12156
16. Pilloni, A. et al. Treatment of Residual Periodontal Pockets Using a Hyaluronic Acid-Based Gel: A 12 Month Multicenter Randomized Triple-Blinded Clinical Trial. *Antibiotics 2021.* 2021;10(8):924. doi:10.3390/antibiotics10080924
17. Hägi TT, Laugisch O, Ivanovic A, Sculean A. Regenerative periodontal therapy. *Quintessence Int.* 2014;45(3):185-92. doi:10.3290/j.qi.a31203
18. Sculean A, Nikolidakis D, Schwarz F. Regeneration of periodontal tissues: combinations of barrier membranes and grafting materials - biological foundation and preclinical evidence: a systematic review. *J Clin Periodontol.* 2008;35(8):106-16. doi: 10.1111/j
19. Seshima F. et al. Periodontal Regenerative Therapy Using rhFGF-2 and Deproteinized Bovine Bone Mineral versus rhFGF-2 Alone: 4-Year Extended Follow-Up of a Randomized Controlled Trial. *Biomolecules.* 2022;12(11):1682. doi: 10.3390/biom12111682
20. Yoshida W, Takeuchi T, Imamura K, Seshima F, Saito A, Tomita S. Treatment of Chronic Periodontitis with Recombinant Human Fibroblast Growth Factor-2 and Deproteinized Bovine Bone Mineral in Wide Intrabony Defects:12-month Follow-up Case Series. *Bull Tokyo Dent Coll.* 2020;61(4):231-241. doi: 10.2209/tdcpublication.2019-0050
21. Mancini L, Fratini A, Marchetti E. Periodontal Regeneration. *Encyclopedia.* 2021;1(1):87-98. doi:10.3390/encyclopedia1010011
22. Venezia E, et al. The use of enamel matrix derivative in the treatment of periodontal defects: a literature review and meta-analysis. *Critical Reviews in Oral Biology & Medicine.* 2016;15(6). doi:10.1177/15441113040150060
23. Sheikh Z, Hamdan N, Ikeda Y, et al. Natural graft tissues and synthetic biomaterials for periodontal and alveolar bone reconstructive applications: a review. *Biomater Res.* 2017;21(9):1-20. doi:10.1186/s40824-017-0095-5
24. Tesić D, Durić M, Hillier-Kolarov V. Vodena tkivna regeneracija--pocetak nove ere u parodontalnoj hirurgiji [Guided tissue regeneration--the beginning of a new era in periodontal surgery]. *Med Pregl.* 1998;51(5-6):237-41
25. Gottlow J, Nyman S. Barrier membranes in the treatment of periodontal defects. *Curr Opin Periodontol.* 1996;3:140-8. PMID: 8624559.
26. Alauddin MS, Abdul Hayei NA, Sabarudin MA, Mat Baharin NH. Barrier Membrane in Regenerative Therapy: A Narrative Review. *Membranes.* 2022;12(5):444. doi:10.3390/membranes12050444
27. Galli M, Yao Y, Giannobile WV, Wang HL. Current and future trends in periodontal tissue engineering and bone regeneration. *Plastic and Aesthetic Research.* 2021;8(3). doi:10.20517/2347-9264.2020.176
28. Jacob SA, Amudha D. Guided tissue regeneration: a review. *J Dent Health Oral Disord Ther.* 2017;6(3):67-73. doi: 10.15406/jdhodt.2017.06.00197
29. Camargo PM, Lekovic, V.; Weinlaender, M.; Vasilic, N.; Kenney, EB, Madzarevic M. The effectiveness of enamel matrix proteins used in combination with bovine porous bone mineral in the treatment of intrabony defects in humans. *J. Clin. Periodontol.* 2001;28:1016–1022

30. Scheyer ET, Velasquez-Plata D, Brunsvold MA, Lasho DJ, Mellonig JT. A clinical comparison of a bovine-derived xenograft used alone and in combination with enamel matrix derivative for the treatment of periodontal osseous defects in humans. *J. Periodontol.* 2002;73:423–432
31. Velasquez-Plata D, Scheyer ET, Mellonig JT. Clinical comparison of an enamel matrix derivative used alone or in combination with a bovine-derived xenograft for the treatment of periodontal osseous defects in humans. *J. Periodontol.* 2002;73:433–440
32. Gestrelus S, Andersson C, Johansson AC, Persson E, Brodin A, Rydhag L, Hammarström L. Formulation of enamel matrix derivative for surface coating. Kinetics and cell colonization. *J Clin Periodontol.* 1997;24(9 Pt 2):678-84. doi: 10.1111/j.1600-051x.1997.tb00249.x
33. Lyngstadaas SP, Wohlfahrt JC, Brookes SJ, Paine ML, Snead ML, Reseland JE. Enamel matrix proteins; old molecules for new applications. *Orthod Craniofac Res.* 2009;12(3):243-53. doi: 10.1111/j.1601-6343.2009.01459.x
34. Heden G, Wennström JL. Five-year follow-up of regenerative periodontal therapy with enamel matrix derivative at sites with angular bone defects. *J Periodontol.* 2006;77(2):295-301. doi: 10.1902/jop.2006.050071
35. Rathe F, Junker R, Chesnutt BM, Jansen JA. The effect of enamel matrix derivative (Emdogain) on bone formation: a systematic review. *Tissue Eng Part B Rev.* 2009;15(3):215-24. doi: 10.1089/ten.teb.2008.0065
36. Sculean A, Windisch P, Döri F, Keglevich T, Molnár B, Gera I. Emdogain in regenerative periodontal therapy. A review of the literature. *Fogorv Sz.* 2007;100(5):220-32, 211-9
37. Rathva VJ. Enamel matrix protein derivatives: role in periodontal regeneration. *Clin Cosmet Investig Dent.* 2011;3:79-92. doi: 10.2147/CCIDEN.S25347
38. Esposito M, Grusovin MG, Papanikolaou N, Coulthard P, Worthington HV. Enamel matrix derivative (Emdogain(R)) for periodontal tissue regeneration in intrabony defects. *Cochrane Database Syst Rev.* 2009;2009(4):CD003875. doi: 10.1002/14651858.CD003875
39. Iorio-Siciliano V, Andreuccetti G, Blasi A, Matarasso M, Sculean A, Salvi GE. Clinical Outcomes Following Regenerative Therapy of Non-Contained Intrabony Defects Using a Deproteinized Bovine Bone Mineral Combined with Either Enamel Matrix Derivative or Collagen Membrane. *J. Periodontol.* 2014;85:342–1350
40. Vandana KL, Shah K, Prakash S. Clinical and radiographic evaluation of Emdogain as a regenerative material in the treatment of interproximal vertical defects in chronic and aggressive periodontitis patients. *Int J Periodontics Restorative Dent.* 2004;24(2):185-91. PMID: 15119889
41. Matarasso M, Iorio-Siciliano V, Blasi A, Ramaglia L, Salvi GE, Sculean A. Enamel matrix derivative and bone grafts for periodontal regeneration of intrabony defects. A systematic review and meta-analysis. *Clin Oral Investig.* 2015;19(7):1581-93. doi: 10.1007/s00784-015-1491-7
42. Rasperini G, Silvestri M, Schenk RK, Nevins ML. Clinical and histologic evaluation of human gingival recession treated with a subepithelial connective tissue graft and enamel matrix derivative (Emdogain): A case report. *Int J Periodontics Restorative Dent.* 2000;20:269–275
43. Cairo F, Nieri M, Pagliaro U. Efficacy of periodontal plastic surgery procedures in the treatment of localized facial gingival recessions. A systematic review. *J Clin Periodontol.* 2017;41(15):S44–S62
44. Sculean A, Schwarz F, Becker J, Brex M. The application of an enamel matrix protein derivative (Emdogain®) in regenerative periodontal therapy: A review. *Med Principles Practice.* 2007;16:167-180
45. Heijl L, Heden G, Svärdröm G, Ostgren A. Enamel matrix derivative (EMDOGAIN) in the treatment of intrabony periodontal defects. *J Clin Periodontol.* 1997;24(9 Pt 2):705-14. doi: 10.1111/j.1600-051x.1997.tb00253.x

46. Forum SJ, Weinberg MA, Rosenberg E, Tarnow D. A comparative study utilizing open flap debridement with and without enamel matrix derivative in the treatment of periodontal intrabony defects: a 12-month re-entry study. *J Periodontol.* 2001;72(1):25-34. doi: 10.1902/jop.2001.72.1.25.
47. Keila S, Nemcovsky CE, Moses O, Artzi Z, Weinreb M. In vitro effects of enamel matrix proteins on rat bone marrow cells and gingival fibroblasts. *J Dent Res.* 2004;83:134-138.
48. Moldovan R, Mester A, Piciu A, Bran S, Onisor F. Clinical Outcomes of Enamel Matrix Derivate Used in Surgical and Non-Surgical Treatment of Peri-Implantitis: A Systematic Review of Clinical Studies. *Medicina.* 2022;58(12):1819. doi: 10.3390/medicina58121819
49. Sculean A, Chiantella GC, Arweiler NB, Becker J, Schwarz F, Stavropoulos A. Five-year clinical and histologic results following treatment of human intrabony defects with an enamel matrix derivative combined with a natural bone mineral. *Int J Periodontics Restorative Dent.* 2008;28(2):153-61
50. Döri F, Arweiler NB, Szántó E, Agics A, Gera I, Sculean A. Ten-year results following treatment of intrabony defects with an enamel matrix protein derivative combined with either a natural bone mineral or a  $\beta$ -tricalcium phosphate. *J Periodontol.* 2013;84(6):749-57. doi: 10.1902/jop.2012.120238.

**ԷՄԱԼԱՅԻՆ ՄԱՏՐԻՑԱՅԻՆ ՍՊԻՏԱԿՈՒՑԻ (EMDOGAIN) ԿԻՐԱՌՈՒՄԸ ՎԵՐԱԿԱՆԳՆՈՂԱԿԱՆ ԴԱՐՕԴՈՆՏԱԼ ԹԵՐԱՊԻԱՅՈՒՄ: ԿԼԻՆԻԿԱԿԱՆ ԴԵՊՔԵՐԻ ՇԱՐՔ**

Դանիել Մելկեր

պարոդոնտոլոգ, Clearwater, Ֆլորիդա, ԱՄՆ

**Ամփոփում**

Այս կլինիկական շարքի նպատակն է ներկայացնել EMD-ով վերականգնողական պարոդոնտալ թերապիայի ցուցումները:

**Նյութեր և մեթոդներ.** Ուսումնասիրությունը ներառում էր 7-15 մմ խորության ոսկրային արատներով 53 հիվանդ: Յուրաքանչյուր հիվանդ նախկին բուժական միջամտությունները արդյունավետ չեն եղել թերությունների լրջության պատճառով և ընդունել են առաջարկված բուժումը: EMD-ի հետ մեկտեղ կիրառվել է նաև այլոգեն ապահանքայնացված ոսկր:

**Արդյունքները.** Բուժման արդյունքների գնահատվել է վիրահատությունից 1 տարի հետո: Արձանագրվել է կլինիկական վիճակի զգալի բարելավում գրեթե բոլոր արատներում: Մի քանի կլինիկական դեպքերում դիտարկվել է բուժման արդյունքները 10 տարի անց, փաստացի արձանագրվել է թերությունների հետագա կրճատում:

**Եզրակացություններ.** Կլինիկական ուսումնասիրությունները ցույց են տվել, որ այլոգեն դեմինալիզացված ոսկրի հետ համակցված EMD-ով բուժումը դրականորեն ազդում է պարոդոնտալ վերականգնող թերապիայի վրա:

**ПРИМЕНЕНИЕ ПРОТЕИНА ЭМАЛЕВОГО МАТРИКСА (ЭМДОГЕЙН) В РЕГЕНЕРАТИВНОЙ ТЕРАПИИ ПАРОДОНТА. СЕРИЯ КЛИНИЧЕСКИХ СЛУЧАЕВ**

Дэниел Мелькер

пародонтолог, Clearwater, Флорида, США

**Абстракт**

**Цели:** Целью данной серии клинических исследований является представление показаний к регенеративной терапии при ЭМД.

**Материалы и методы:** В исследование включены 53 пациента с костными дефектами глубиной от 7 до 15 мм. Каждый пациент ранее имел неудачные пародонтологические терапевтические вмешательства и согласился на рекомендованное лечение. Наряду с EMD также использовалась аллогенная деминерализованная кость.

**Результаты:** Результаты лечения оценивали через 1 год после операции: достоверное улучшение клинического состояния было зафиксировано практически по всем дефектам. В нескольких клинических случаях результаты лечения наблюдались через 10 лет, было зафиксировано дальнейшее уменьшение дефектов.

**Выводы:** Клинические исследования показали, что лечение ЭМД в сочетании с аллогенной деминерализованной костью оказывает положительное влияние на восстановительную терапию пародонта.