



SURGICAL TREATMENT OF ANEURYSMS OF AORTIC ARCH BRANCHES AND VESSELS OF THE UPPER EXTREMITIES

KHANCHI MEAD, MATKERIMOV A.ZH., TERGEUSSIZOV A.S., DEMEUOV T.N., ZHAKUBAYEV M.A., KHANCHI M.M., SHAMSHIEV A.S., SAGATOV I.Y.*

Department of Vascular Surgery, "A.N. Syzganov National Scientific Center for Surgery" JSC, Almaty, Kazakhstan

Received 09.09.2021; accepted for printing 18.01.2022

ABSTRACT

Aneurysms of the aortic arch branches and vessels of the upper extremities are dangerous and there is a high probability of mortality due to rupture of the aneurysm or stroke. The indication is surgical treatment, regardless of the age and size of the aneurysms. The frequency of deaths and strokes that occurred during operations for carotid artery aneurysms is about 2%, which is associated with distal embolism of intracerebral vessels and the contents of the aneurysm cavity.

One of the most common causes of aneurysms of the branches of the aortic arch and vessels of the upper extremities are atherosclerosis, nonspecific aortoarteritis and posttraumatic aneurysms.

The study included 38 patients with aneurysms of the branches of the aortic arch and arteries of the upper extremities operated in the vascular surgery department over the past 10 years, whose total age ranged from 19 to 76 years. There were 84% men, 16% women. Aneurysms of the carotid arteries and its branches (temporal artery) were diagnosed in 58%, subclavian arteries in 16%, arteries of the upper extremities in 26%.

The size of aneurysms of the branches of the aortic arch and arteries of the upper extremities ranged from 2.5 cm to 10 cm. The average size is 6.3 ± 1.8 cm.

When choosing the method of treatment of aneurysms of the branches of the aortic arch and arteries of the upper extremities, preference was given to performing reconstructive operations without the use of additional materials, which were performed in 52% cases), in 13 of these cases, excision of a false aneurysm with stitching of the defect was performed, in 6 of these cases, resections of aneurysms with end-to-end anastomosis were performed. In 48% cases, operations with the use of synthetic materials and autovenous plastic surgery were performed, and endovascular interventions were also performed in 4 cases.

The most frequent type of surgery performed is resection of an aneurysm with a lateral suture – 34% cases. Resection of the anastomosis aneurysm at the end of the arteries – 16%, and prosthetics – in 8% cases (synthetic alloprosthetics in one and with autovenous prosthetics in two cases). After resection of subclavian artery aneurysm due to large diastasis of blood flow, reconstruction was performed by bypass surgery or prosthetics. Arterial aneurysm resection with autovenous patch was performed in 13% cases, and with allosuturing – in 8% cases. Excision of an aneurysm of the axillary artery on the left with the restoration of a synthetic patch – in 5% cases. Ligation of an aneurysm in the temporal artery was performed in 2 cases (5%), this type of operation was performed with an aneurysm of non-main vessels, as well as in vessels with collateral blood flow in the distal area of the vessels. Implantation of a stentgraft into the right subclavian artery – in 3 cases (8%). X-ray endovascular embolization of aneurysm – in 3% case.

Positive results in the postoperative period were observed in 92% patients. One (3%) patient developed complications in the form of hematomas after aneurysm resection. In 5% cases - lymphorrhea after excision of a false aneurysm.

KEYWORDS: . aneurysms of the aortic arch branches and artery of the upper extremities, surgical treatment, X-ray endovascular intervention, aneurysm embolization.

CITE THIS ARTICLE AS:

Khanchi Mead, Matkerimov A.Zh., Tergeussizov A.S., Demeuov T.N., Zhakubayev M.A., Khanchi M.M., Shamshiev A.S., Sagatov I.Y. (2022); Surgical treatment of aneurysms of aortic arch branches and vessels of the upper extremities; NAMJ v.16 (2022) No.1, p. 35-42; DOI: <https://doi.org/10.56936/18290825-2022.16.1-35>

ADDRESS FOR CORRESPONDENCE:

Inkar Y. Sagatov, MD., Ph.D.

JSC "A.N. Syzganov National Scientific Center of Surgery" 62 Zheltoksan Street, Almaty 050004, Kazakhstan

Tel.: +7 708 155 15 77, E-mail: inkar_sagatov@mail.ru

INTRODUCTION

Aneurysms of the branches of the aortic arch are relatively less common than other peripheral vessels. More often, aneurysms of this localization have an atherosclerotic etiology, whereas degenerative vascular changes occur in systemic diseases. Thus, the frequency of true carotid artery aneurysms, according to various data [El-Sabroun *R et al.*, 2000; Goldstone *J et al.*, 2005], ranges from 0.4 to 4% of all peripheral artery aneurysms, operations for which are performed in practice only in 0.1-2% of all carotid artery interventions [McCollum *C et al.*, 1972].

Totally 37 patients with internal carotid artery (ICA) aneurysms were reported over a 21-year follow-up period – about 35 patients over 24 years [Moreau *P et al.*, 1994]. Moreover, both authors describe the classic variant of the atherosclerotic etiology of the disease. In the absolute majority of cases, true aneurysms of the internal carotid artery are small and asymptomatic, as a result of which they can lead to a sudden acute violation of cerebral circulation and death. In recent years, there have been reports of a combination of aneurysm with kinking of the internal carotid artery [Gaibov *A et al.*, 2007; Arakelyan *V et al.*, 2013]. Over the past three decades, endovascular methods of treating aneurysms of all localizations, including ICA, have been actively developing, and a case of using hybrid techniques with an aneurysmal sac close to the bone canal has been described [Wong *E et al.*, 2010].

The prevalence of subclavian artery aneurysm (SCAA) is also low, only a few isolated cases in the form of clinical observations are presented in the available literature. Most of them relate to SCAA of traumatic origin [Dent *T et al.*, 1972]. The most extensive review is presented by M.

Dougherty and co-authors in 1995. It provides information about 64 patients in whom 70 subclavian artery aneurysms were detected. About 60% of them had atherosclerotic etiology, 25% were caused by infection (15% – syphilis, 10% – tuberculosis). Marfan syndrome and cystic media necrosis accounted for 10% of cases [Dough-

erty *M et al.*, 1995; Pinho Esteves *F et al.*, 2013].

The prevalence of SCAA in some cases are completely asymptomatic, especially with an intra-thoracic location of the aneurysmal sac. The most common symptoms of SCAA are chest and shoulder girdle pain, neurological manifestations in the limb due to compression of the brachial plexus. It is often possible to detect a triad of symptoms characteristic of an aneurysm: pain, the presence of a pulsating tumor and systolic noise. Differential diagnosis in SCAA is required in the presence of Gorner syndrome in patients with neurogenic tumors of the neck and mediastinum [Pairolero *P et al.*, 1981; Bicheng *Zh et al.*, 2010]. Indications for surgical interventions remain in all cases of aneurysms of the branches of the aortic arch and arteries of the upper extremities, regardless of its localization, this is due to the threat of complications threatening cute cerebrovascular accident, limb loss, bleeding or death.

The study aimed to improve the diagnosis and results of surgical treatment of patients with aneurysms of the aortic arch branches.

MATERIAL AND METHODS

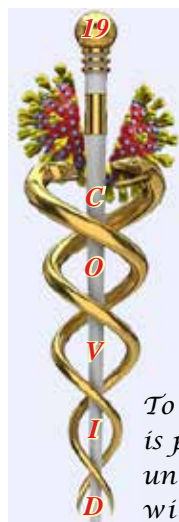Totally 38 patients with aneurysms of segments of the aortic arch branches and arteries of the upper extremities were operated on in the Department of Vascular Surgery of the National Scientific Center of Surgery named after A.N. Syzganov, from 2000 to 2019. The patients were 19 to 76 years-old; the average age was 43 ± 6.5 . There were 32 men (84%), 6 women (16%) (Table 1).

Based on table 2, the most common cause of aneurysm development was atherosclerosis in 31 (2%) patients, in second place – posttraumatic false aneurysm in 4 cases (10%) and in third place nonspecific aortoarteritis in 3 cases (8%).

By localization (table 3) carotid artery aneurysms (common carotid artery, extracranial carotid artery, internal carotid artery) were diagnosed in 20 (44%) patients, branches of the carotid artery (Temporal artery) in 2 cases (5%), subclavian – in 6 (17%), arteries of the upper extremities – in 10 (28%).

The size of aneurysms of the branches of the aortic arch and arteries of the upper extremities ranged from 2.5 cm to 10 cm. The average size is 6.3 ± 1.8 cm.

Performing reconstruction on the arteries in all cases of aneurysms of the branches of the artery arch is the only way to preserve the main circula-



To overcome it
is possible, due to the
uniting the knowledge and
will of all doctors in the world

TABLE 1
Distribution of patients depending on age

Age groups	Number of Patients
19-20	1
21-30	3
31-40	4
41-50	6
51-60	12
61-76	12
Total	38

NOTE: average age 43 years

TABLE 2
Distribution of patients depending on the causes of aneurysm development

Etiological factors	Number of patients					
	Total		Men		Women	
	n.	%	n.	%	n.	%
Atherosclerosis	31	82	27	71	4	10.5
Nonspecific aortoarteritis	3	8	1	2.5	2	5.5
Post-Traumatic False aneurysm	4	10	4	10.5	0	0
Total	38	100	32	84	6	16

TABLE 3
Distribution of patients depending on localization

No	Localization of aneurysm	Quantity	%
1	Common carotid arteries	8	21
2	Temporal artery	2	5
3	External carotid arteries	3	8
4	Internal carotid arteries	9	23.5
5	Subclavian artery	6	16
6	Brachial arteries	4	10.5
7	Ulnar artery	3	8
8	Axillary artery	3	8
	Total	38	100

tion in the area of distal localization of the aneurysm, regardless of its localization, this is due to the threat of complications threatening cerebrovascular accident, limb loss, bleeding or death. When performing operations on brachiocephalic arteries, a Matass test was performed to determine the tolerance of the brain to ischemia. Re-

gardless of this result, hypothermia and a drug method were performed if necessary.

The most frequent type of surgery performed is resection of an aneurysm with a lateral suture – 13 cases (34%) (Table 4). Resection of the anastomosis aneurysm at the end of the arteries – 6 (16%), and prosthetics – in 3 cases (8%) (synthetic alloprosthetics in one and with autovenous prosthetics in two cases). After resection of subclavian artery aneurysm due to large diastasis of blood flow, reconstruction was performed by bypass surgery or prosthetics. Arterial aneurysm resection with autovenous patch was performed in 5 cases (13%), and with allosunting – in 3 cases (8%). Excision of an aneurysm of the axillary artery on the left with the restoration of a synthetic patch – in 2 cases (5%). Ligation of an aneurysm in the temporal artery was performed in 2 cases (5%), this type of operation was performed with an aneurysm of non-main vessels, as well as in vessels with collateral blood flow in the distal area of the vessels. Implantation of a stentgraft into the right subclavian artery – in 3 cases (8%). X-ray endovascular embolization of aneurysm – in 1 case (3%).

TABLE 4
Distribution of patients depending on the type of surgery

Type of operation	Quantity	%
Excision of a false aneurysm with autovenous prosthetics	2	5
Excision of a false aneurysm alloprosthetics with a synthetic prosthesis	1	3
Excision of a false aneurysm with suturing of the defect	13	34
Aneurysm resection and bypass surgery	3	8
Excision of an aneurysm of the axillary artery on the left with the restoration of a synthetic patch	2	5
Resection of an artery aneurysm with an autovenous patch	5	13
Resection - with end-to-end anastomosis	6	16
Implantation of a stent graft into the subclavian	3	8
X-ray endovascular embolization of aneurysm	1	3
Ligation of an aneurysm in the temporal artery	2	5
Total	38	100

Positive results in the postoperative period were observed in 5 (92%) patients. 1 (3%) patient developed complications in the form of hematomas after aneurysm resection. In 2 (5%) cases – lymphorrhea after excision of a false aneurysm.

Assessment of immediate and long-term results

We evaluated the immediate and long-term results of surgical treatment by preserving the main circulation in the area of distal aneurysm localization.

Thus, in the long-term postoperative period, positive clinical results in patients after the operations performed by us were 92% ($p>0.05$). One patient (2.5%) developed a complication in the form of a hematoma after resection of an aneurysm due to post-traumatic aneurysm. In 2 (5.5%) cases – lymphorrhea after excision of a false aneurysm due to changes in local tissue and the size of the aneurysm. There were no fatal outcomes in the postoperative period.

Performing reconstruction on the arteries is the only way to preserve the main circulation in the

area of distal localization of the aneurysm.

CONCLUSION

Surgical treatment of aneurysms of the branches of the aortic arch is a difficult task. The treatment plan is determined by a number of clinical factors and a strictly individual approach to each patient. Endovascular treatment is the main one in patients with ICA aneurysms, while microsurgical techniques can help in complex, non-standard cases when endovascular treatment seems ineffective or technically impossible. The planning of surgical treatment must necessarily assume the possibility of a revascularization procedure, which may become necessary during the intervention. It is advisable to treat patients with large and giant aneurysms of the branches of the aortic arch in specialized centers that have the appropriate experience and technical capabilities for surgical, endovascular and combined staged treatment.

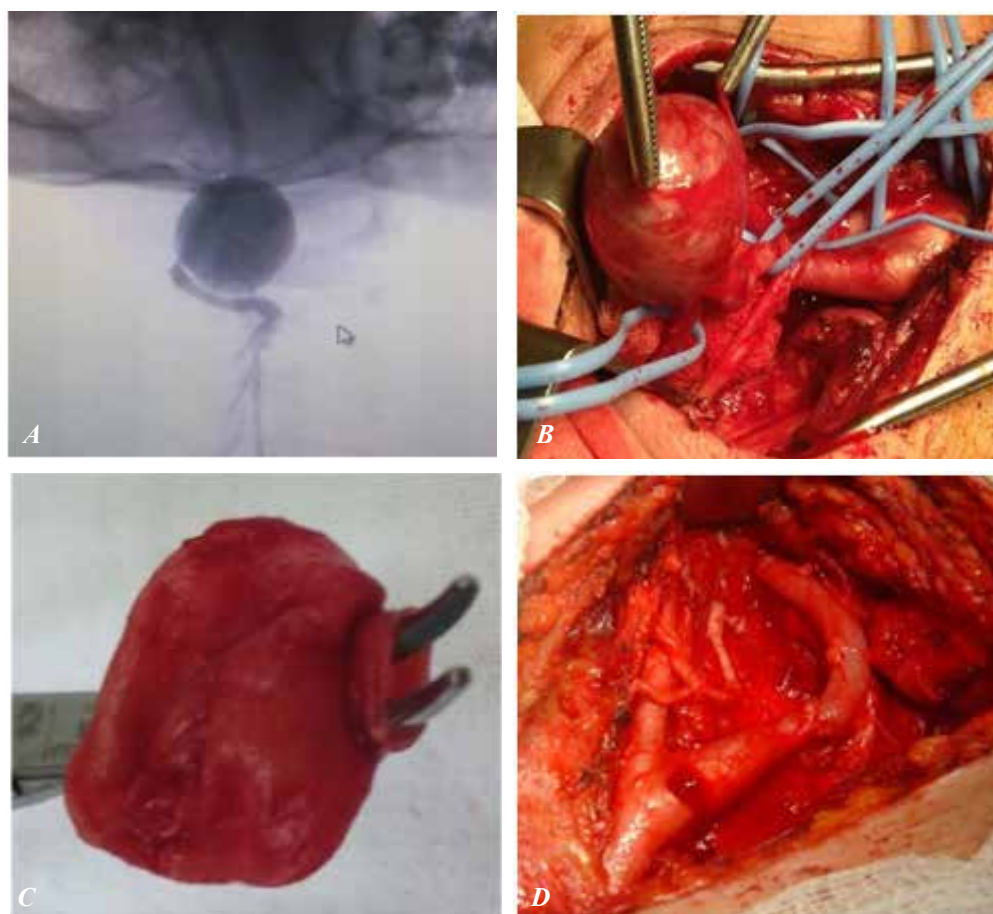


FIGURE 1. The results of the examination of aortic arch branches and the presence of carotid artery aneurysm (A) – angiogram of the aneurysm of the cervical portion of the internal carotid artery, measuring 5.0×4.0 centimeters; (B) – schematic image of intraoperative internal carotid artery, (C) – schematic representation of micropreparation of the internal carotid artery aneurysm, (D) – after resection of the internal carotid artery aneurysm with autovenous plastic surgery

CLINICAL CASE 1

Patient P.Zh., 44-years-old. Complaints of pain and the presence of throbbing in the neck on the right, dizziness, headaches, hoarseness of voice, periodic pain during the act of swallowing.

Considers himself ill for 1 year. When the above complaints first appeared, she went to the polyclinic at her place of residence, where it was regarded as submandibular lymphadenitis, received conservative treatment without effect. In this connection, she was sent to an oncologist's consultation, where she was examined and sent to a vascular surgeon at the National Scientific Center for surgery named after A.N. Syzganov where the aortic arch branches were examined and a carotid artery aneurysm was detected (Fig.1).

Angiological status: In the area of bifurcation of the carotid artery on the right, a pulsating tumors measuring 5x5 cm is determined. Auscultatively, systolic noise is heard above it.

Operation: Resection of the internal carotid artery aneurysm with autovenous plastic surgery.

CLINICAL CASE 2

Patient S.S.S., 43-years-old. Diagnosis: Idiopathic saccular aneurysm of the internal carotid arteries on the left.

Diagnosis: Idiopathic saccular aneurysm of internal carotid arteries on the left of multi-slice spiral computed tomography of the cavernous arteriovenous malformation on the left of the internal carotid artery and the jugular vein. The coiling on the right is internal carotid artery. measuring

2,3x2,4 cm in diameter

Operation: Resection of an aneurysm of the internal carotid arteries on the left with autovenous prosthetics.

Complaints about the presence of a pulsating tumor in the cervical region on the left, discomfort when turning the head. According to the patient, she fell ill in April 2019, the disease is associated with a sharp turn of the head, after which a tumor-like tumors appeared in the cervical region on the left. She was examined on an outpatient basis for CT of the neck vessels from 30.04.2019 (Fig. 2).

Conclusion: CT pattern is most characteristic of cavernous arteriovenous malformation of the left ICA and jugular vein. Coiling on the right of the ICA. 02.05.2019 consulted by the head of department. vascular surgery of the National Scientific Center for Surgery named after Syzganov recommended surgical treatment. The general condition of the patient is of moderate severity. The heart tones are muted; the rhythm is correct. Blood pressure on the left upper limb is not determined, on the right 120/80 mmHg, heart rate 76 per minute.

Local status: Palpation in the cervical region on the left shows a pulsating tumor up to 3.0 cm in diameter. Computed tomography from 30.04.2019: CT picture is most characteristic of cavernous arteriovenous malformation of the left ICA and jugular vein. Coiling on the right of the ICA.

Ultrasound of ICA from 04/24/2019: Left: ICA aneurysm (2.0*3.0), partially thrombosed, with blood circulation in it.

Ultrasound of lymph nodes from 22.04.2019: ultrasound signs of enlarged cervical lymph nodes

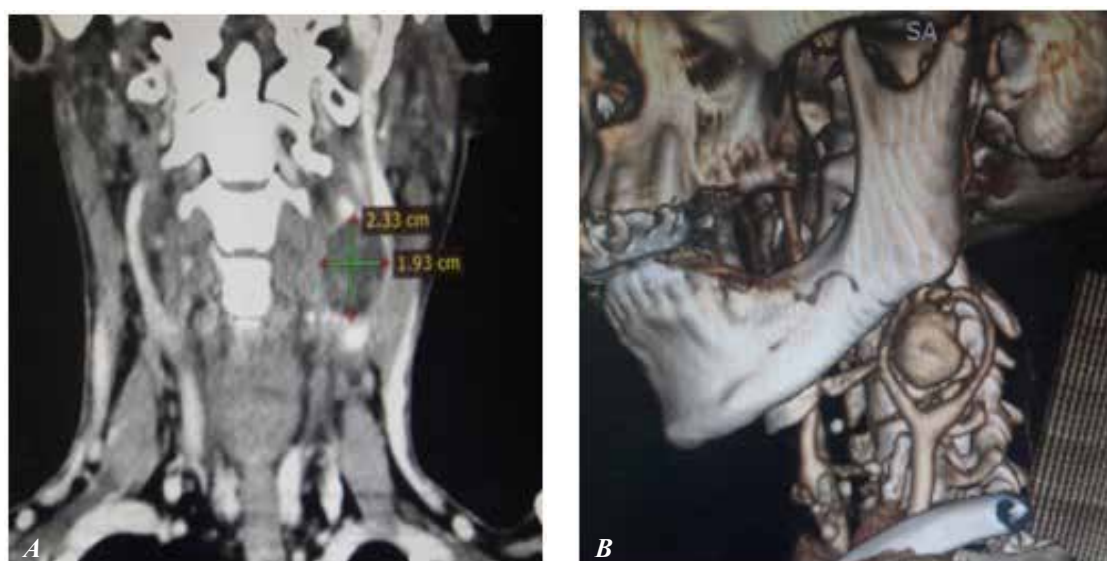


FIGURE 2. Idiopathic saccular aneurysm of internal carotid arteries on the left
A, B - schematic image, patient S.S.S., 43-years-old

on the left (differentiate with pathology of the carotid arteries, less likely). On 25.06.2019, the operation was performed: Revision. Excision of an aneurysm of the internal carotid artery on the left. Carotid endarterectomy on the left. Prosthetics of the internal carotid artery with an autovenous patch from the ven saphena magna on the left.

Endovascular surgical interventions

With the advent of minimally invasive endovascular techniques, such treatment methods as embolization of the aneurysm cavity with its subsequent thrombosis, implantation of a stent graft, allowing to avoid open surgical interventions, began to be used. However, there are a number of factors that do not allow the use of these techniques: the convoluted course of the artery, the distal location of the aneurysm, the absence of a zone for stent implantation. All these factors often force us to abandon minimally invasive techniques and apply the classic version of surgical treatment.

X-ray endovascular surgery was performed in 4 cases. In 3 cases – the use of a stentgraft and in one case - X-ray endovascular embolization of an aneurysm.

CLINICAL CASE 3

Patient P.Zh., 59-years-old. Diagnosis: Post-traumatic aneurysm of the right thyroid trunk (Fig. 3). Operation: X-ray endovascular embolization of a thyroid aneurysm complaints of the presence of a tumor-like pulsating tumors in the supraclavicular region on the right, moderate soreness, increased blood pressure to 220/110 mmHg, weakness, malaise.

In June 2018, he was injured (fell at home), an open reposition of the right clavicle and osteosynthesis of the right humerus was performed at the

place of residence due to a fracture, 2 months later he noted a bulge above the place of surgery, was observed by a traumatologist at the place of residence, in December 2018 the metal structure was removed at the city hospital, was consulted by an angiosurgeon. On 31.01.2019, the angiosurgeon of the A.N. Syzganov National Research Medical Center consulted on the “teleconference”, The general condition of moderate severity due to the underlying disease. Clear consciousness, sitting position in bed. Heart rate – 78 per minute. Tongue, moist, normal color.

Locally: on examination, there are n/a surgical scars in the projection of the right clavicle and in 1/3 of the humerus, a convex aneurysm measuring 7.0 x 8.0 cm on the right above the clavicle, moderately painful on palpation, systolic noise with periods of “cat purring” on auscultation, the distal pulse above the radial and ulnar arteries is preserved, the patency of other main arteries is preserved.

CLINICAL CASE 4

Patient P.Zh., 43-years-old Diagnosis: Post-traumatic aneurysm of the right subclavian artery. -Complaints upon admission: the presence of a pulsating tumors of the right supraclavicular region, periodic pain, cold, chilliness of the upper limb. (Fig. 4)

Operation: Implantation of a stentgraft in the right subclavian artery.

Course of intervention: after treatment of the surgical field under local anesthesia (Sol. Lidocaine 0.5% - 2 ml), the radial artery on the left side of the Seldinger was punctured and catheterized. Next, a JR type catheter was carried out and installed in the proximal third of the subclavian artery and angiography of the left upper limb was

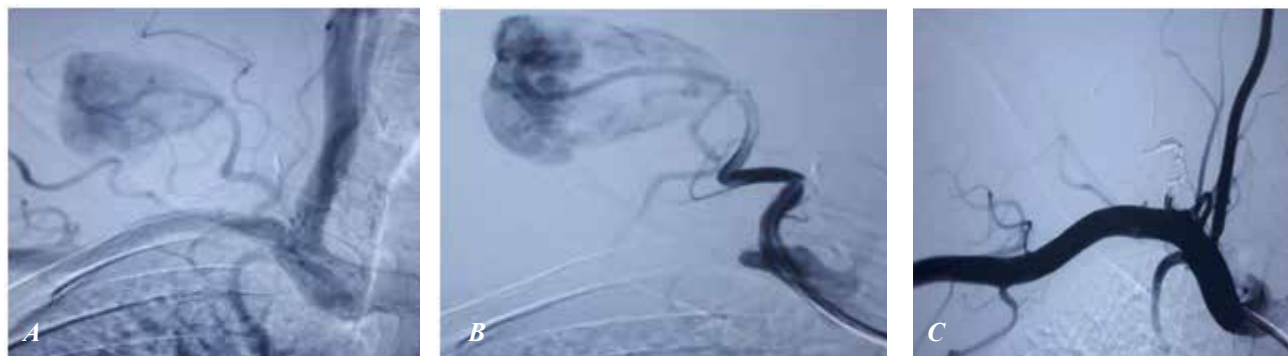


FIGURE 3. Post-traumatic aneurysm of the right thyroid trunk

(A) – Angiogram, Patient P.Zh., 59-years-old. Schematic representation of post-traumatic aneurysm of the right thyroid trunk, aneurysm measuring 7.0 x 8.0 cm, (B) - X-ray, endovascular embolization of an aneurysm of the thyroid trunk, (C) - schematic representation after endovascular embolization of a thyroid aneurysm

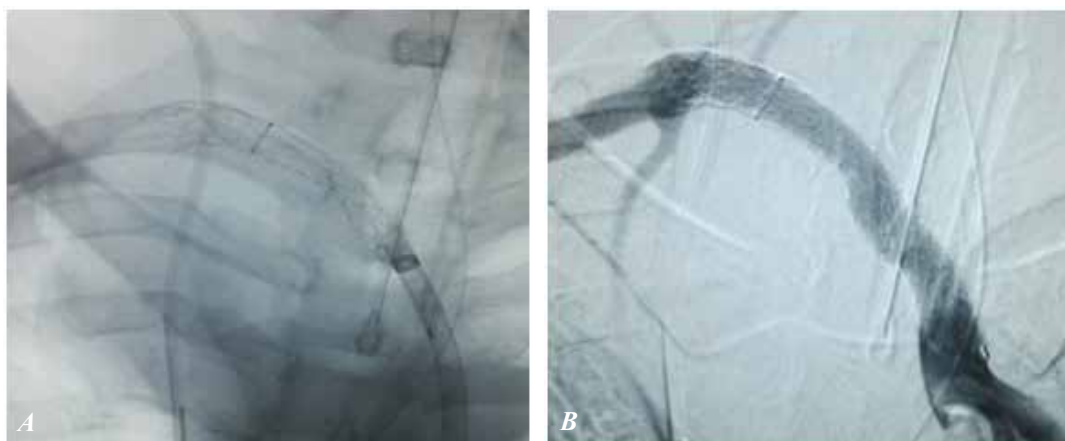

FIGURE 4. Post-traumatic aneurysm of the right subclavian artery

(A) - Schematic image of angiography. patient P.Zh, 43-years-old. Diagnosis: Post-traumatic aneurysm of the right subclavian artery and implanted stent graft stage, subclavian artery aneurysm, with a diameter of 11 mm and a length of 57 mm, (B) - Schematic representation of the control angiography of the implanted stent graft is completely passable. The defect of the subclavian artery in the middle third is completely closed, the aneurysm is not contrasted

performed, in which an aneurysm with a diameter of 11 mm and a length of 57 mm was detected in the middle third of the subclavian artery.

An “Amplatzer Super Stiff” conductor, 0.35, 260 cm long, was passed through the catheter. Next, a JR type catheter was removed and a trans-federal Advante stent graft 7.0 mm × 59.0 mm was delivered along the conductor. Positioning of the stent graft under the control of angiography and X-ray examination for the discharge of the left vertebral artery. Postdilation was performed in the middle third under a pressure of 18.0 atm. The balloon has been removed.

With control angiography, the implanted stent graft is completely passable. The defect of the subclavian artery in the middle third is completely closed, the aneurysm is not contrasted.

ANEURYSMS OF THE ARTERIES OF THE UPPER EXTREMITIES

When choosing a method of treatment with aneurysms of the arteries of the upper extremities, preference was given to performing reconstructive surgery to restore hemodynamics in the limbs of patients.

Aneurysms of the arteries of the upper extremities were in 10 cases. Aneurysm resection with autovenous brachial artery plasty was performed in 6 cases, and autovenous prosthetics - in 2 cases, aneurysm resection with end-to-end anastomosis - in 1 case.

CLINICAL CASE 5

Patient 65-year-old with a diagnosis of an aneu-

rysm of the brachial ulnar artery. The patient underwent revision of the radial artery. During the revision, multiple arteriovenous fistulas are noted. Considering multiple arteriovenous fistulas, there is a high risk of intraoperative and postoperative bleeding. In this connection, it is recommended to conduct multi-stage surgical treatment of endovascular embolization. After embolization of arteriovenous fistulas, resection of the radial artery aneurysm is recommended.

Thus, in the postoperative period, patients had positive clinical results after the surgery performed by us - 92%. 1 (2.5%) developed a complication in the form of a hematoma after resection of an aneurysm. In 2 (5.5%) cases - lymphorrhea after excision of a false aneurysm.

Performing reconstruction on the arteries is the only way to preserve the main circulation in the area of distal localization of the aneurysm.

In 19 (53%) patients, long-term results after surgical treatment were studied in terms from 6 months to 5 years. It was difficult to assess the long-term results of treatment in full, since there was a large migration of the population and some patients live in other regions of the Republic or have moved to other countries. According to the indications, if necessary, repeated hospitalization of patients was carried out to resolve the issue of surgical treatment. We recommend dynamic follow-up, conservative therapy courses, and smoking cessation to all patients after surgery. However, in many cases, the recommendations were not implemented.

For a more objective assessment of the results

of surgical treatments, the results of reconstructive operations on the brachiocephalic arteries and in the upper limb artery basin were evaluated separately. The results of reconstructive operations on the carotid arteries were studied in 26 patients (a total of 38 were operated on). In the long-term period after operations on the branch of the aortic arch, blood circulation in the operated hemisphere was noted in 2 patients, of which 1 patient had episodes of transient ischemic attacks, and strokes - in 1 patient. In the long-term results of reconstructive operations on the upper extremities, in 1 case, insignificant stenosis was noted, which, after a course of conservative treatment, blood circulation was restored.

CONCLUSION

Surgical treatment of aneurysms of the branches of the aortic arch and arteries of the upper extremities is a difficult task. The treatment plan is deter-

mined by a number of clinical factors, anatomical location and also requires a strictly individual approach to each patient. Endovascular treatment is the main treatment in patients with ICA aneurysms, while surgical techniques can help in complex non-standard cases when endovascular treatment seems ineffective or technically impossible. The planning of surgical treatment must necessarily assume the possibility of a revascularization procedure, which may become necessary during the intervention. It is advisable to treat patients with large and giant aneurysms of the branches of the aortic arch in specialized centers that have the appropriate experience and technical capabilities for surgical, endovascular and combined staged treatment. Timely surgical intervention reduces the risk of disability and complications in patients with aneurysms of the branches of the aortic arch and arteries of the upper extremities.

REFERENCES

1. Arakelyan VS, Gamzaev NR, Gidasov NA, Kolesnikov YaG, Barukin YuS., *et al* (2013). [Extracranial internal carotid artery aneurysm. A trick of abnormal tortuosity?] [Published in Russian]. Thoracic and cardiovascular surgery. 1: 27-31
2. Bicheng Zhan, Shijiang Zhang, Yongfeng Shao (2010). Operation for huge subclavian artery aneurysm: a case report. J Thorac Dis. 2(2): 117-120
3. Dent TL, Lindenauer SM, Ernst CB, Fry WJ (1972). Multiple arteriosclerotic arterial aneurysms. Arch Surg. 105: 338-343
4. Dougherty MJ, Calligaro KD, Savarese RP, DeLaurentis DA (1995). Atherosclerotic aneurysm of the intrathoracic subclavian artery: a case report and review of the literature. J Vasc Surg. 21: 521-529
5. El-Sabrouh R, Cooley DA (2000). Extracranial carotid artery aneurysms: Texas Heart Institute experience. J Vasc Surg. 31(4): 702-712
6. Gaibov AD, Sultanov DD, Kamolov AN (2007). [Successful surgical treatment of veritable internal carotid aneurysm due king-king] [Published in Russian]. Angiology and vascular Surgery. 13(3): 145-147
7. Goldstone J (2005). Aneurysms of the extracranial carotid artery. Vascular surgery. Ed. Rutherford R.B. 6th ed. Philadelphia: Elsevier Saunders. 2052-2064
8. McCollum CH, DaGama AD, Noon GP, DeBakey ME (1979). Aneurysm of the extracranial carotid artery. Twenty-one years' experience. Am J Surg. 137(2): 196-200
9. Moreau P, Albat B, Thevenet A (1994). Surgical treatment of internal carotid artery aneurysm. Ann Vasc Surg. 8(5): 409-416
10. Pairolero PC, Walls JT, Payne WS., *et al* (1981). Subclavian axillary artery aneurysms. Surgery. 90: 757-763
11. Pinho Esteves F, Ventura Ferreira A, Prado dos Santos V, Santos Novaes G, Razuk Filho A, Augusto Caffaro R (2013). Subclavian and axillary arterial aneurysms: two case reports. J Vasc Bras. 12(4): 329-334
12. Wong E, Chue WL (2010). Hybrid (open and endovascular) repair of distal extracranial internal carotid artery aneurysm. EJVES Extra. 20: 1-21



CONTENTS

4. **ZILFYAN A.V., AVAGYAN S.A., MURADYAN A.A., BARSEGHYAN E.S.**
RECOMMENDED TACTICS FOR MASS VACCINATION OF HEALTHY INDIVIDUALS AND COVID-19 CONVALESCENTS
13. **MAGHAKYAN S.A., AGHAJANOVA E.M., HOVHANNISYAN A.H., ASOYAN V.A., BARSEGHYAN E.S.**
MYXEDEMA COMA ASSOCIATED WITH COVID-19 INFECTION: CASE REPORT
17. **HAKOBYAN H.H.**
ANXIETY AND CHRONIC PAIN IN CAREGIVERS OF CHILDREN WITH CEREBRAL PALSY IN ARMENIA: DESCRIPTIVE STUDY
23. **ISSAMATOV B.K., ZHOLDYBAY ZH.ZH., TAJIBAEV T.K., SERIKULY E.S., BAIMAKHANOV B.B., MEDEUBEKOV U.SH., SAGATOV I.Y.**
FEATURE ANALYSIS OF COMPUTED TOMOGRAPHIC SIGNS OF HEPATOCELLULAR CARCINOMA IN MULTIPHASE STUDIES
29. **TAJIBAYEV T.K., CHORMANOV A.T., MATKERIMOV A.ZH., TERGEUSSIZOV A.S., BAUBEKOV A.A., ZHAKUBAYEV M.A., SAGATOV I.Y., KANCHI M.**
CAROTID BODY TUMORS: CASE SERIES OF EXTREMELY RARE HEAD AND NECK PARAGANGLIOMAS.
35. **KHANCHI MEAD, MATKERIMOV A.ZH., TERGEUSSIZOV A.S., DEMEUOV T.N., ZHAKUBAYEV M.A., KHANCHI M.M., SHAMSHIEV A.S., SAGATOV I.Y.**
SURGICAL TREATMENT OF ANEURYSMS OF AORTIC ARCH BRANCHES AND VESSELS OF THE UPPER EXTREMITIES
43. **SARKISYAN N.G., KATAEVA N.N., AKHMETOVA A.I., KUKHAREVA A.R., CHUMAKOV N.S., KHLYSTOVA K.A., MELIKYAN S.G.**
PHYSICOCHEMICAL INDICATORS OF DENTAL PATIENT SALIVA WHO HAVE UNDERGONE AN UNCOMPLICATED CORONAVIRUS INFECTION
49. **KHABADZE Z.S., NEGORELOVA YA.A., GEVORKYAN A.A., NAZAROVA D.A., SHILYAEVA E.S., KOTELNIKOVA A.P., MORDANOV O.S.**
COMPARATIVE ANALYSIS OF SMEAR LAYER REMOVAL TECHNIQUES IN THE TREATMENT OF DENTAL CARIES
58. **KULIKOVA A.A., KHABADZE Z.S., GENERALOVA YU.A., MOKHAMED EL-KHALAF R., NAZAROVA D.A., YOLLYBAYEV YA.A.**
APPLICATION OF POLYHEXANIDE AS A NEW HIGHLY EFFECTIVE ANTISEPTIC COMPOSITION.
64. **MORDANOV O.S., KHABADZE Z.S., NAZAROVA D.A., SHILYAEVA E.S., KOTELNIKOVA A.P., MORDANOVA A.V.**
TEMPERATURE EFFECT ON THERMAL CHANGES AND PHASE ANALYSIS OF 3Y-TZP ZIRCONIA RESTORATIONS
70. **BASSEL J.A., EYAD M.S.**
EVALUATION OF MARGINAL ADAPTATION OF (CAD/CAM) LAVA PLUS HIGH TRANSLUCENT ZIRCONIA AND (CAD/CAM) IPS-EMAX FULL CROWNS
76. **KHABADZE Z.S., NAZAROVA D.A., SULEIMANOVA Z.M., GENERALOVA YU.A., KOTELNIKOVA A.P.**
MICROBIAL BIOECENOSIS OF APICAL PERIODONTITIS IN THE ROOT CANAL SYSTEM (PART 1)
81. **KHABADZE Z.S., NAZAROVA D.A., SULEIMANOVA Z.M., GENERALOVA YU.A., KOTELNIKOVA A.P.**
MICROBIAL BIOECENOSIS OF APICAL PERIODONTITIS IN THE ROOT CANAL SYSTEM. (PART 2)
87. **TIUNOVA N.V., NABEREZHNOVA S.S., SAPERKIN N.V., VDovina L.V., DAUROVA F.JU., TOMAEVA D.I., CHUVARKOVA I. M.**
RATIONALE BEHIND A MINIMALLY INVASIVE APPROACH IN THE TREATMENT OF DENTAL FLUOROSIS
94. **TSVETKOVA M.A., SOHOV S.T.**
ORTHODONTIC TREATMENT ALGORITHM FOR PATIENTS WITH POSITIVE DRUG ANAMNESIS. GLUCOCORTICIDS.
101. **PANAHI S.R., SABZ G., JOKARTANGKARAMI A., AFROUGHI S., KARIMPOUR F.**
ANATOMICAL CHARACTERISTICS OF NASOPALATINE CANAL USING CONE BEAM COMPUTED TOMOGRAPHY IMAGES
109. **PURWANTI T., ERFAN KUSUMA M.S., YUDIANTO A.**
HEAD INJURY CASE WITH BLUNT FORCE TRAUMATIC: CASE REPORT AT BHAYANGKARA HOSPITAL KEDRII INDONESIA



The Journal is founded by
Yerevan State Medical
University after M. Heratsi.



Rector of YSMU

Armen A. Muradyan

Address for correspondence:

Yerevan State Medical University
2 Koryun Street, Yerevan 0025,
Republic of Armenia

Phones:

(+37410) 582532 YSMU

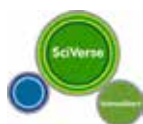(+37410) 580840 Editor-in-Chief

Fax: (+37410) 582532

E-mail: namj.ysmu@gmail.com, ysmiu@mail.ru

URL: <http://www.ysmu.am>

*Our journal is registered in the databases of Scopus,
EBSCO and Thomson Reuters (in the registration process)*



SCOPUS



EBSCO



THOMSON
REUTERS

Copy editor: Tatevik R. Movsisyan

Printed in "VARM" LLC
Director: Ruzanna Arakelyan
Armenia, 0018, Yerevan,
Tigran Mec 48, 43
Phone: (+374 91) 19 29 00,
E-mail: armana6@mail.ru

Editor-in-Chief

Arto V. Zilfyan (Yerevan, Armenia)

Deputy Editors

Hovhannes M. Manvelyan (Yerevan, Armenia)

Hamayak S. Sisakyan (Yerevan, Armenia)

Executive Secretary

Stepan A. Avagyan (Yerevan, Armenia)

Editorial Board

Armen A. Muradyan (Yerevan, Armenia)

Drastamat N. Khudaverdyan (Yerevan, Armenia)

Levon M. Mkrtchyan (Yerevan, Armenia)

Foregin Members of the Editorial Board

Carsten N. GUTT (Memmingen, Germany)

Muhammad MIFTAHUSSURUR (Indonesia)

Alexander WOODMAN (Dharhan, Saudi Arabia)

Hesam Adin Atashi (Tehran, Iran)

Coordinating Editor (for this number)

Inkar Sagatov (Almaty, Kazakhstan)

Editorial Advisory Council

Ara S. Babloyan (Yerevan, Armenia)

Aram Chobanian (Boston, USA)

Luciana Dini (Lecce, Italy)

Azat A. Engibaryan (Yerevan, Armenia)

Ruben V. Fanarjyan (Yerevan, Armenia)

Gerasimos Filippatos (Athens, Greece)

Gabriele Fragasso (Milan, Italy)

Samvel G. Galstyan (Yerevan, Armenia)

Arthur A. Grigorian (Macon, Georgia, USA)

Armen Dz. Hambardzumyan (Yerevan, Armenia)

Seyran P. Kocharyan (Yerevan, Armenia)

Aleksandr S. Malayan (Yerevan, Armenia)

Mikhail Z. Narimanyan (Yerevan, Armenia)

Levon N. Nazarian (Philadelphia, USA)

Yumei Niu (Harbin, China)

Linda F. Noble-Haeusslein (San Francisco, USA)

Eduard S. Sekoyan (Yerevan, Armenia)

Arthur K. Shukuryan (Yerevan, Armenia)

Suren A. Stepanyan (Yerevan, Armenia)

Gevorg N. Tamamyan (Yerevan, Armenia)

Hakob V. Topchyan (Yerevan, Armenia)

Alexander Tsiskaridze (Tbilisi, Georgia)

Konstantin B. Yenkovyan (Yerevan, Armenia)

Peijun Wang (Harbin, China)